

An interview with

Ajalmar Maia



- » Graduated in Dentistry, Federal University of Rio Grande do Norte - UFRN (1976), Brazil.
- » MSc, Pediatric Dentistry, University of São Paulo - USP (1978), Brazil.
- » PhD (1993) and Post-doctorate (2007), Pediatric Dentistry, USP, Brazil.
- » Associate Professor, UFRN, Brazil.
- » E-mail: ajalmar.maia@yahoo.com.br

It is a pleasure to talk about the life of a winning man. Brazil is rich in stories as the one that I am about to tell in this interview, but poor in acknowledging their value. Ajalmar Maia was born in Umarizal, a small town in the interior of the state of Rio Grande do Norte, Brazil. One of the sons of a large family of humble origins, quite common in the middle of the last century, he started working at an early age as a sales assistant and spent his teenage years in several jobs, which I am not going to describe to avoid losing focus on his greatest virtue: his tenacious quest for knowledge. Even when working very hard, Ajalmar never left school. At the age of 17, he joined the Brazilian Air Force, his second mother in his own words. While in the Air Force, he entered the School of Dentistry of the Federal University of Rio Grande do Norte (UFRN), Brazil. His intelligence, not equaled by many, associated with immeasurable strength to work and determination to learn eventually led him to unequalled success in his profession. Dr. Ajalmar Maia specialized in Orthodontics in the School of Dentistry of Lins and got his Master's Degree in the School of Dentistry of Bauru (FOB), University of São Paulo (USP). He returned to Natal, already a professor at UFRN, and met his wife and fellow dentist, Nair, mother of his three children (Najwa, Nayara and Ajalmar), working companion and life partner. After that, he obtained his doctorate also at FOB/USP. A model of success in private clinic not matched by any I have ever seen in Brazil, he also has time to write several books, from poetry to Dentistry, and dozens of scientific articles. After all that, he returned to Bauru for a post-doctorate program, mentored by Professor Guilherme Janson, one of the interviewers in this section. Professor Ajalmar is more than it all together: writer, poet, professor, airplane pilot, composer that won several music festivals in the region where he lives, and a great fan of Brazilian popular culture. Ajalmar is a rich fruit of the Brazilian Agreste region, who did not give in to the scorching sun and that used education to grow as an example of success in our profession.

David Normando
Editor in Chief

How to cite this interview: Maia A. An interview with Ajalmar Maia. Dental Press J Orthod. 2013 Mar-Apr;18(2):8-16.
Submitted: February 14, 2013 - **Revised and accepted:** March 07, 2013

» Patients displayed in this interview previously approved the use of their facial and intraoral photographs.

Tell us a little about your history: Your family, your career, why you chose Dentistry and Orthodontics. (Cátia Quintão)

I was born in a small town in the interior of the state of Rio Grande do Norte, in Brazil, in a working-class family. From my mother, a teacher, I inherited abnegation, perseverance and discipline; my father, a construction foreman, was intelligent, had a lot of friends, but was free of concerns.

My first job opportunity was at the age of 10, taking notes for a merchant who was illiterate. It was then that I found out that learning would take me to where I wanted to be. At 11, under my mother's guidance, who was always very concerned about my preparation for the future, I changed jobs and started selling fabrics at a street stand, where I learned everything about that line of business. Above all, that was when I first "went into business". Today this has been hypocritically classified as exploitation of child labor; however, I know that if children do not learn what they should, they end up learning what they should not.

At the age of 14, I was transferred to Mossoró, where I went to junior high and the first year of high school; I worked in sales during the day and went to school at night. I wanted to study in Natal, the capital city of the state of Rio Grande do Norte, but had no means to support myself there. One day, a sales representative came to the shop where I worked and talked about the Air Force, where it was possible to serve and study at the same time. That filled my head with dreams and I enlisted in the Air Force. In 1970, I joined the Brazilian Air Force, and it was then that I could study for the examinations to enter college and to join the School for Air Force Specialists: I passed both. And after that, I studied Dentistry while still in the Brazilian Air Force: "The man is forged in hardship."

I had always felt a passion for Engineering, but, I don't know why, I prepared myself to enter college in the area of healthcare, and was placed 6th in the exam, which would entitle me even to study Medicine. However, as an Air Force man, it was very difficult to study in a full-time course, and I depended on the Air Force money to support myself. Therefore, it was at this time, once again, that divine providence changed my life, as I was chosen to study Dentistry, an area that I was not familiar with and had never been in my plans.

During the course, still in the Air Force, my professors gave me great support and incentive. I was the tutor for an American professor from Seattle, Dr. Roy Velling, who recommended my name for a job as a professor at the Federal University do Rio Grande do Norte (UFRN), which had plans to renovate its program and qualify new professors at that time. After being hired as a professor, I was chosen to take a Master's Degree in the city of Bauru, in São Paulo, where I lived from 1976 to 1979 and completed two Master's Degrees (Pediatric Dentistry and Orthodontics).

After that, I came back to Bauru for my doctorate, in 1989, and a post-doctorate, in 2005. Therefore, I did not choose Dentistry; destiny put it on my way.

I had the pleasure to meet Dr. Ajalmar out of the Dentistry scene, and found a friendly, open person, a family man that loves life. A generous man that has thousands of different interests: capable of flying a plane, producing a music CD, managing business, running a large orthodontic clinic and writing books that contain incredible orthodontic cases. My question is: how is that possible? (Marco Rosa)

We all have talents and versatility. The trick is not to direct our capacity and skills to a single activity, be it profession, leisure or business, as if it were the whole world. All activities are closely associated, and what you learn in one can develop the other. Therefore, if you have a talent for music, you may have the potential to write, do business, manage an enterprise. The most important is your creative capacity, discipline, balanced boldness and a broad world vision to see the opportunities around us. Today, education (that is, qualification) is available to overcome our limitations and improve our potentialities.

What is the secret to write a professional and financial success story? What do you think is important as an investment to create and obtain maximum benefit from our careers? (Guilherme Janson and Cátia Quintão)

I think it is simple: A good professional education, a lot of training, since there is no champion without training, and practice, essential to keep a professional performance; sensitivity to work simply and effectively;

a vision, to predict in which way the world is moving; an open mind for the past and future, using perspicacity to assess the positive legacy of one's specialty (orthodontics), what will change, trends and paths into the future; financial education, because none of it is taught in undergraduate courses in the area of healthcare. Moreover, we have to learn with life and think logically.

Financial success comes from one's financial education to transform present gain into future benefit and, later on, you will have a good financial performance and produce enough to enjoy life travelling, studying and growing intellectually.

If you could make time turn back, professionally speaking, what would you do again? What would you do differently? (Cátia Quintão)

Living is a lifelong learning experience. Time shows us where and how we made mistakes, and humility redeems us because of regret that brings absolution. There are some things, attributed to me as referential, that fill me with great joy. It is good to hear people say that my simplicity, friendliness, happiness and playfulness in the way that I deal with people are "door-openers" and characteristics that call their attention. However, many times, under the pressure and in the heat of adversity in college politics and at other crucial moments in my life, when facing meanness, because of my temper and strong personality, the way I said things could have been different, with different results, which has brought me regrets because I did not have, at the time, the wisdom to express myself differently. I have never acted disrespectfully towards people, no matter who they were, but, until then, I had only been in contact with intelligence and had not yet learned about wisdom. And in my self-evaluation, every time I put in practice those qualities praised by my friends, I came off better.

Also, with the knowledge and the 33 years of clinical practice that I have today, I would have a much leaner clinic, with operational costs different from those of the first clinic I built.

Do you believe that it is still worth to be an orthodontist today, with all the contamination of our specialty? (Cátia Quintão)

I thought that I would never, in my whole life, have the chance to answer such vital questions about my profession. This is a singular opportunity.

It saddens me to see what I shall call THE BIRTH, LIFE AND DEATH OF SEVERINA, in honor of the poet João Cabral de Melo Neto. Therefore, I dimly saw Dentistry bloom in the 70s, which allowed dentists to leave the barber's chair for good and leave the artisanal life behind, to move onto the stage of science, which assigned incontestable distinction to our profession. However, our leaders in the several agencies, associations and entities have never understood that, back then, caries was under control in developed countries and that, due to its simplicity and low cost, this would inexorably come to Brazil and change the picture in relation to this disease, turning the "country of toothless people" into the "country of smiling people". But not due to public policies: It was the industry that managed to add fluoride to toothpaste, as fluoride would never be available to all Brazilians through treated water supply.

Today, children will only have significant caries if they are so poor as to not be able to buy toothpaste or if they do not brush their teeth with it. There is no comprehensive program in any university or agency to treat children 0 to 12 years of age and no caries. Indirectly, industry has done that and, in a few generations, certain dental specialties will disappear, and our actions will focus primarily on trauma and agenesis. Therefore, there should inevitably be fewer dentists to respond to such reality. Our problem has never been the number of dentists, but, rather, their distribution and the option for curative activities. Unfortunately, at the time paid university courses bloomed in our country, the success of our profession was threatened, Dentistry did not have leaders prepared to take it into the 21st century, and young dentists are paying for that. While Scandinavia, England and the United States closed down Dentistry courses, Brazil continued moving in the opposite direction and opening new Dentistry courses. Every misstep in Dentistry has an impact on Orthodontics. It is still worthy to study this beautiful specialty, but it has become harder to do it with dignity. To begin with, there is talent and ethics, which are principles that Angle held so high. However, everything will find a solution due to chaos, as there is no plan to recover our professional status. We will have to come to a point at which it no longer pays to be a dentist before courses are closed down and things get back on track. This is a task for the next 30 years.

For the time being, few orthodontists will prosper. I believe that “it is good when it is good for everyone”, and it was like that in my time, as a young dentist.

I know that one of Dr. Ajalmar’s main interests is long-term stability. What strategy do you use for treatment completion and retention currently? (Marco Rosa)

With a solid orthodontic qualification, always considering long-term results after 15 years and having a well-established technical, scientific and philosophical bearing, I tried to find out whether our clinical evidence is right and whether findings might be different. In other words, our results and patient satisfaction had to be checked against evidence from scientific research. Some studies^{1,2} answered our questions and strengthened our convictions. Basically, we use bonded lingual retainers in the mandible and wraparound retainers in the maxillary arch. Depending on the case, when there are maxillary anterior diastemas, we also use bonded lingual retainers. For Class III malocclusion, we use a night retainer for prognathism, as described by Eschler; in Class II with instability due to surgical mandibular advancement, we complement treatment with a bionator to be worn at night. In fact, stability is achieved with compliance or when skeletal relations ensure good occlusal relations, as well as muscle, functional and esthetic balance. Therefore, our treatment goals are: in terms of skeletal relations, the balance between bones to establish esthetic and functional occlusion, as well as oral and perioral muscle balance; in terms of occlusion, Andrews’ six keys to occlusion; in terms of function, the preference is for a pattern of canine disocclusion, or protrusive group disocclusion with incisors protected by canines, absence of occlusal interferences in the functional movements of the mandible, lip sealing at rest, nose breathing and tongue positioned functionally; in terms of esthetics, facial filling as a long-term approach, attractive smile and balanced facial muscles.

What is the importance of deleterious habits, such as tongue thrust, lip incompetence and mouth breathing, and speech therapy treatments in your orthodontic practice?

(Marco Rosa)

Poor oral habits change and deteriorate the functional pattern of oral and perioral muscles and affect

the pattern of muscle contraction over bone and teeth. Early advice, interventions, or both, while the patient is growing and before habits become acquired patterns ingrained for a long time, are important to redefine a normal pattern of muscle contraction before function markedly affects form. Every time we: (1) refer a child with severe airway obstruction to the otolaryngologist to clear obstruction; (2) advise a child to stop using a pacifier or sucking thumb; (3) expand the palate during deciduous dentition to recover arch form; (4) use appliances to re-educate muscle patterns, particularly to change swallowing patterns, lingual position and lip sealing. We are preventing problems that orthodontists see in adolescence or adulthood when we establish a muscle pattern and follow up irreversible skeletal changes due to functional pattern changes (Figs 1A, 1E and 2A).

Speech therapy plays a role as an important support for orthodontic stability and may be considered a complement to our activities. Therefore, we refer speech therapy to our patients when the morphology of the dental arch or bones suggests that it is possible to learn and establish a normal muscle contraction pattern. This is important to correct inadequate tongue position and swallowing patterns with atypical pressure (Figs 1C, 1D, 1G, 1H and 2B), increase the length of the upper lip in up to 4 mm in the cases of mouth breathing or hypotonic and short (hypotrophic) lip, which promotes good lip sealing and results in an esthetic smile when finalizing an orthodontic case at any stage (early, interceptive or corrective stage). For the surgical cases, in which morphological changes occur suddenly, it is indispensable to undergo muscle reeducation to stabilize the skeletal result achieved with surgery, particularly open bite, Class III and Class II.

Currently, patients have better understanding and are committed to the stability of treatment results. This has contributed to greater efforts by the patient after surgery in speech therapy for muscle reeducation.

You have several orthodontic cases of open bite treated surgically along with your very successful clinical practice. Would you treat them in the same way or differently today?

(Guilherme Janson)

Skeletal anterior open bite remains one of the main events of instability in orthodontic practice. Although the

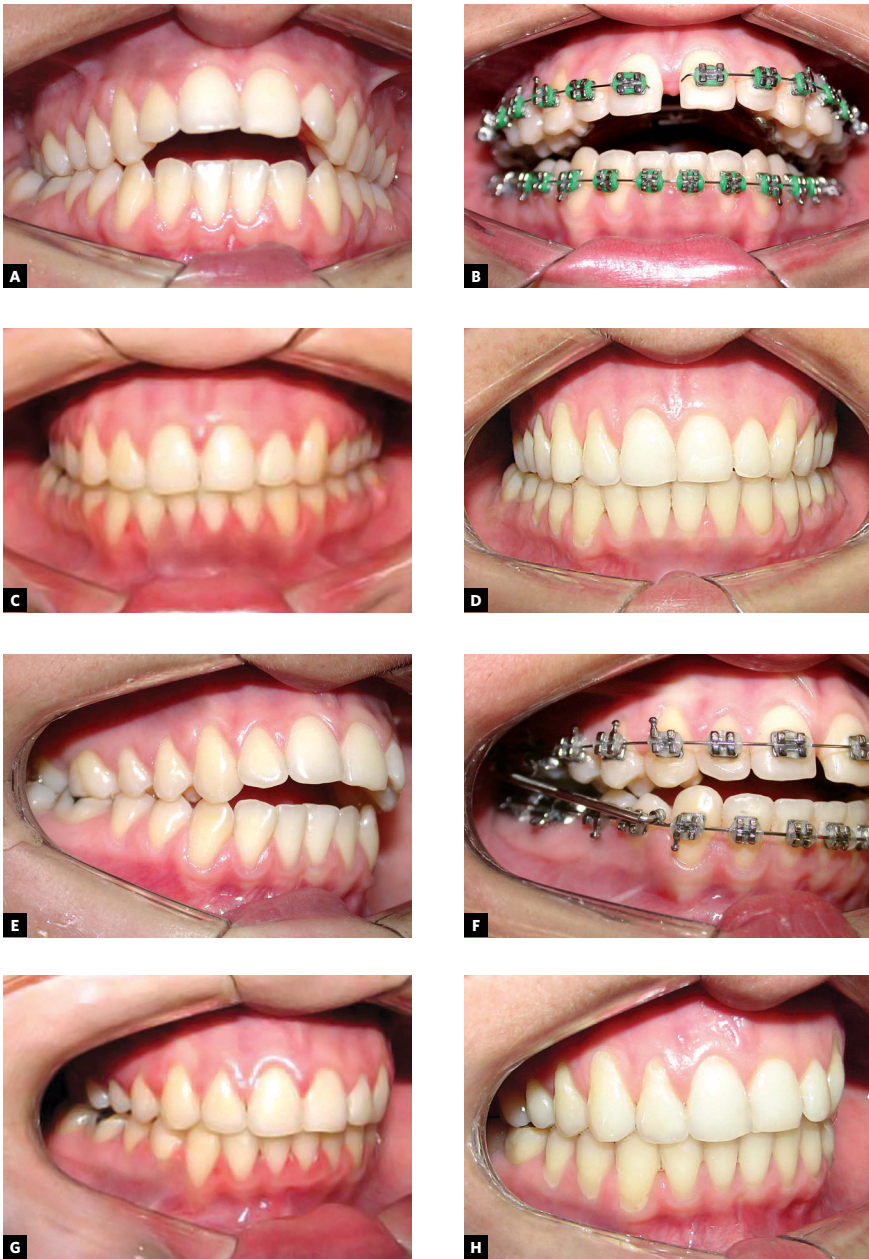


Figure 1 - Baseline intraoral images of a 19.5-year-old patient with a Class II division 1 malocclusion (A, E) treated with a rapid palatal expander and a Herbst appliance (B,F) at 2 years and 11 months (C, G) completed with speech therapy; results are stable 6 years and 6 months after treatment (D, H).

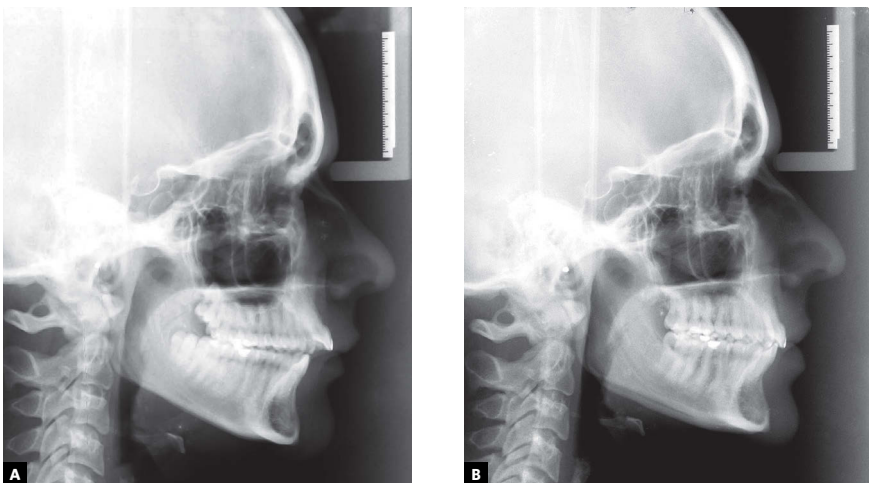


Figure 2 - Baseline cephalogram of patient at 19.5 years of age shows a Class II division 1 malocclusion (A); treatment with rapid palatal expander and Herbst appliance for 2 years and 11 months, without surgery, completed with speech therapy, as shown in final radiograph (B).

treatment prognosis is good, it is one of the leading cases of predictable poor stability. Mechanically, orthodontic open bite correction has changed very little: Whereas some authors prefer to level by section, other prefer to align and level the whole arch, which depends on whether the surgery will include segmentation. Treatment principles have changed: Studies have shown that more stability is achieved when surgery includes upper repositioning of the maxilla, particularly in the posterior segment, in cases in which the downward growth of this region affects posterior facial height. Surgery may be performed in the maxilla only, and the mandible may be functionally rotated counterclockwise in the fossa to achieve anterior occlusal contact. This type of surgery also results in good stability when including sagittal mandibular osteotomy with or without rotation of the anterior segment. However, for simplification, some surgeons still prefer to operate on the mandible only and achieve rotation only with the lower jaw. This protocol has proven to be very unstable, and I have always argued against it and discouraged surgeons to use it.

The experience in the surgical and orthodontic treatment of many cases of open bite and an observed instability around 35.8%³ led us to the development of a treatment protocol that has proven to be very efficient and stable and contributed, moreover, to reducing the number of cases with the type of malocclusion that requires orthognathic surgery as treatment. This protocol⁴ recommends extraction of the mandibular first molars and maxillary third molars, reciprocal mechanical anchorage for the retraction of anterior teeth, mesial movement of the posterior segment of the mandible, intrusion of maxillary molars and counterclockwise rotation of the mandible (Figs 3 and 4).

Do you often use intraoral distalizing appliances to correct Class II malocclusion? Do you think they are efficient?

(Guilherme Janson)

I have always been committed to an intensive private practice activity, in which everyday routines are

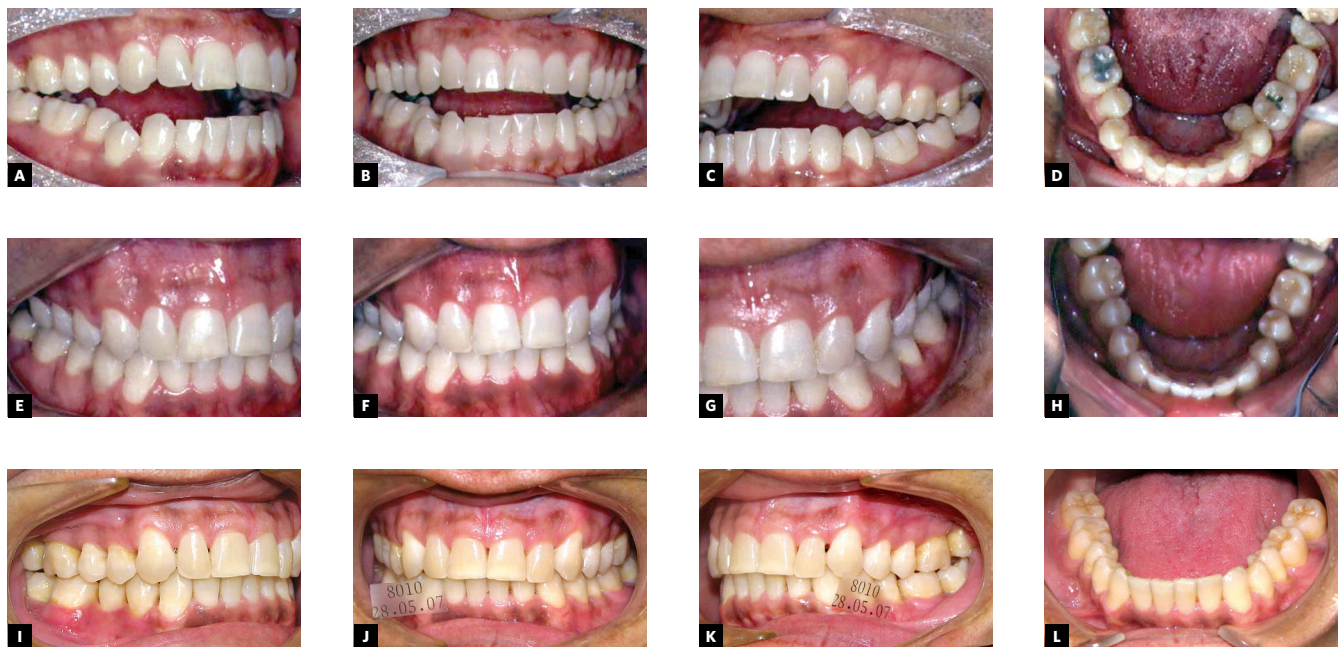

Figure 3 - Baseline intraoral images of a 31-year-old patient with Class III malocclusion and skeletal open bite (A, B, C, D); treatment with fixed straight-wire appliance, without surgery, and extraction of mandibular first molars and maxillary third molars at 2 years and 1 month (E, F, G, H); treatment complemented with speech therapy and stable results 6 years after treatment (I, J, K, L).

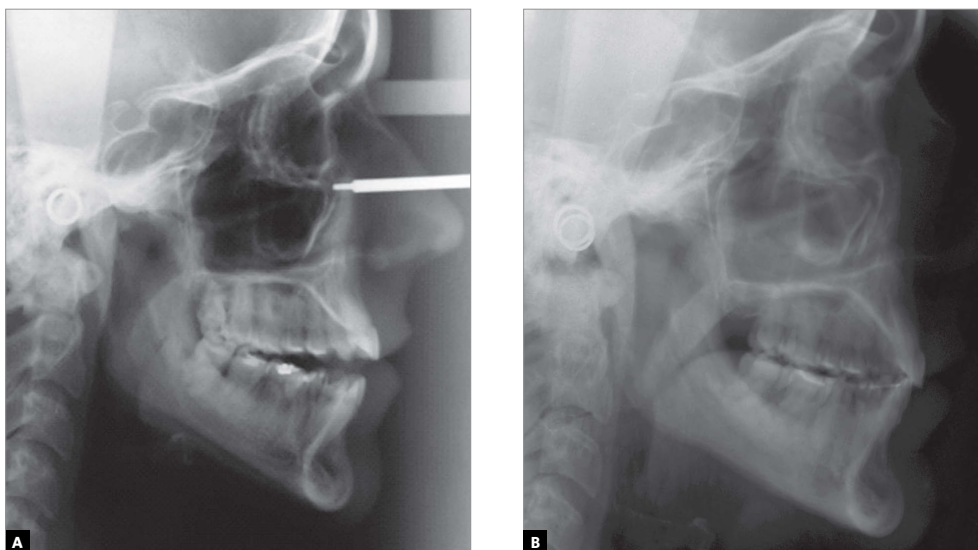


Figure 4 - Baseline cephalogram at 31 years of age shows open bite (A). At treatment completion, open bite was corrected without surgery (B), with extraction of teeth 18, 28, 36 and 46; 2 years and 10 months after treatment.

very different from the treatment of patients in courses and schools. The levels of cooperation and demand are different. Therefore, the dentist should be sensitive and work with what works, with devices that the patients wear, that do not result in effects that make the treatment longer, and that are under the control of the orthodontist. Studies have confirmed that the different types of distalizing appliances (Headgear, Pendex, Jones jig, Herbst, Jasper Jumper, etc.) work. However, the appliances that yield the best clinical results and have great predictability and control are the appliances that work as the Herbst system (Figs 1 and 2). The tandem system of sliding mechanics and Class II elastics also works well in mixed dentition.

Your interest for the treatment of tooth transposition is well known, also by your publications. Considering the perspective of someone who knows how to deal with it, how much and when is it indicated to accept maxillary canine-premolar transposition?

(Leopoldino Capellozza Filho)

The opportunity to treat an expressive number of transposition cases made me understand the main hurdles to be overcome: (1) preservation of buccal cortical bone; (2) conditions for root repositioning during transposition reversal; (3) efficient mechanics; and (4) lingual canine torque and buccal first premolar torque (Fig 5). The first two limitations may

be overcome at the time we move the first premolar lingually. These cases can be treated if we take that principle into consideration and use effective mechanics.^{5,6,7} However, in cases of alveolar narrowing, recession of the buccal bone plate, gingival retraction indicating periodontal compromise or advanced age, transposition should be accepted.

What were the greatest changes from the orthodontics that you learned in school and the one that is recognized today as contemporary practice? Were the major changes conceptual or technological? Have advantages been greater for dentists or patients?

(Leopoldino Capellozza Filho)

Changes have been enormous. We learned orthodontics using the edgewise technique and manufacturing all the bands. We had extraoral anchorage in practically all cases; numerous extractions, especially premolars; diagnosis and planning mostly according to cephalometric measurements and the mandibular incisor as the basis; important orthodontic interventions in the maxilla, as the mandible presented several limitations for traditional orthodontics; orthodontics was limited to growing patients and contraindicated for adults because of the high risks of root resorption. This has all changed, and technological advances have been fundamental for changes: Direct bonding, straight wire, shape-memory nitinol wires,

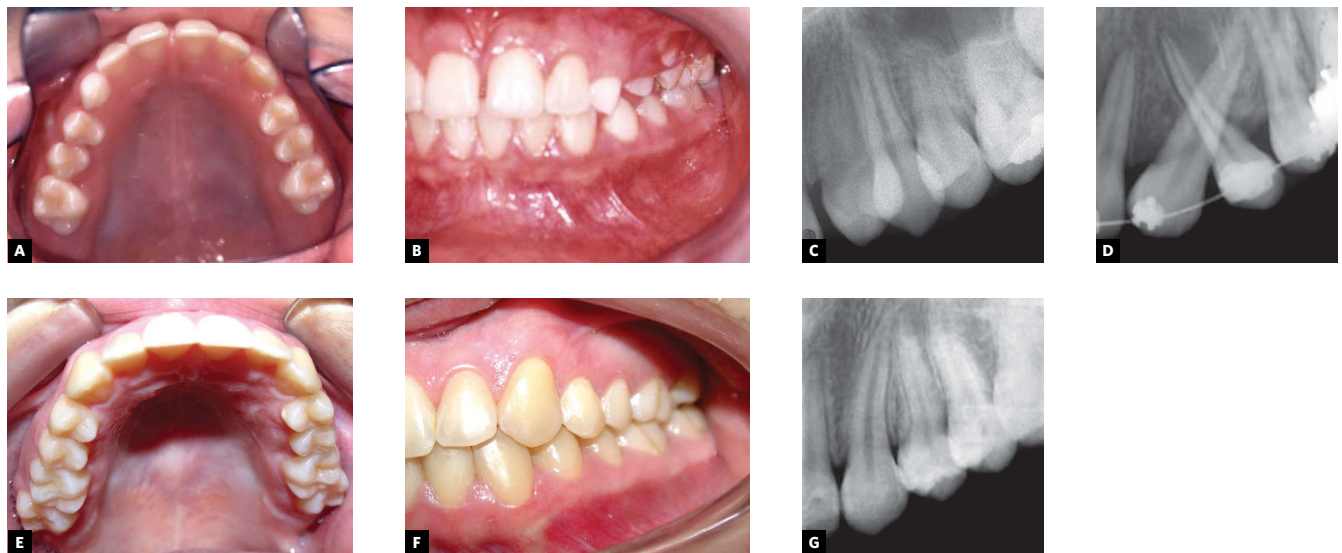


Figure 5 - Baseline intraoral view of an 11.5-year-old patient with Class I malocclusion and maxillary left canine-first premolar transposition (A, B, C); treatment with fixed straight wire appliance and reversal of transposed roots (D); at 2 years and 3 months (E, F, G).

mini-implants, computer-assisted cephalometry, computed tomography, etc. However, the crucial turning point was the conceptual change or, often, the changes in the comprehension of certain phenomena, which have not changed, but which we, orthodontists, now understand differently.

The major changes have been:

- 1) Individualized planning, with major attention to the face and using the nasolabial angle (NLA) and the position of the maxillary incisor as references.^{8,9}
- 2) Class II treatment with greater attention to the mandible. I have not used extraoral appliances for distal movements in the maxilla for over 15 years. Studies helped us to understand that in the Class II division 1 malocclusion, the maxilla, according to the NLA, is found in both mixed and permanent dentition: Slightly retruded in 45% and 53%; and protruded in only 5% and 5%. Based on the SNA, the maxilla in the mixed and permanent dentitions is: Well positioned in 23% and 15% of the cases; retruded in 27% and 35%; slightly protruded in 35% and 35%; and protruded, but not affecting facial appearance in 15% and 15%. In contrast, the mandible (SNB) in the mixed and permanent dentitions is: Well positioned in 18% and 20%; retruded in 60% and 70%; and protruded in 22% and 20%. Therefore, the

major problem Class II cases is the mandible.¹⁰ These data confirm results reported by McNamara¹¹ and suggest that we treat Class II cases based on the mandible following Kingsley's concept of jumping the bite, which Europeans applied to functional maxillary orthopedics and that, thanks to technological advances, was revived for fixed orthodontics after the development of new versions of the 1909 Herbst appliances, reintroduced by Pancherz¹² in 1979.

- 3) Implants, such as mini-implants and mini-plates, used as intraoral anchorage substantially changed the concept of anchorage and ensured greater efficiency for orthodontists and less collaboration from patients, as cooperation often depended on the patients only and was decisive for treatment success or failure.
- 4) The difficulty in deciding whether to extract or not led us to publish the basic assumptions and strategies that we routinely use to achieve 5% to 8% extractions only.¹³ In contrast, technological advances increased our accuracy in orthodontics, and now we have more control, even in the molar region, and that is an alternative for extractions. This may change results of facial filling in comparison with cases of premolar extractions.
- 5) Orthodontic treatment in adults was a revolution of its own. However, emerging concepts, defend-

ed by some authors, about the possibility of facial growth until about age 30 years led some authors, such as Ruf and Pancherz,¹⁴ to successfully treat, without extractions or surgery, numerous cases of Class II malocclusion earlier classified as surgical extraction cases, and followed them up to control stability in the long term.

Therefore, there were mutual benefits, and results were positive for both patients and orthodontists after these changes. Contemporary advances in orthodontics are marked by: more beautiful faces and smiles

with better facial filling and improved longevity due to planning that assigns priority to the face; intraoral anchorage for the treatment of Class II malocclusions associated with mandibular deficiency; reduction of the percentage of extractions and alternatives other than premolar extractions, previously practically the only option. At the same time, the treatment of a large number of very stable Class II division 1 and division 2 cases in adults without extractions, as we have used for some years, emerges as the extraordinary change for the near future.¹⁵

Cátia Cardoso Abdo Quintão

- » MSc and PhD in Orthodontics, Federal University of Rio de Janeiro (Brazil), extension course at Wales University, UK.
- » Associate Professor, State University of Rio de Janeiro; Guest Professor, Graduate Program at Federal University of Juiz de Fora (Brazil), and Universidad Mayor de San Marcos, Lima, Peru,
- » Delegate of the Association for Dental Education in Europe since 2004.

Marco Rosa

- » Former president of the Italian Association of Specialists in Orthodontics (1998-2001).
- » Professor, Graduate Program, Specialization in Orthodontics, Università degli Studi dell'Insubria, Varese, Italy.

Guilherme Janson

- » MSc and PhD in Orthodontics, School of Dentistry of Bauru, University of São Paulo (FOB-USP), Brazil.
- » Full Professor, FOB-USP, Brazil.

Leopoldino Capelloza Filho

- » MSc in Orthodontics, FOB-USP, Brazil
- » PhD in Oral Rehabilitation, Periodontics, FOB-USP.
- » Professor, Master's Program in Orofacial Clefts, Craniofacial Anomalies Rehabilitation Hospital, University of São Paulo, Brazil.

REFERENCES

1. Maia NG, Normando AD, Maia FA, Ferreira MA, Alves MS. Factors associated with orthodontic stability: a retrospective study of 209 patients. *World J Orthod.* 2010;11(1):61-6.
2. Maia NG, Normando D, Maia FA, Ferreira MA, Alves MSCF. Factors associated with long-term patient satisfaction. *Angle Orthod.* 2010;80(6):1155-8.
3. Maia FA, Janson G, Barros SE, Maia NG, Chiqueto K, Nakamura AY. Long-term stability of surgical-orthodontic open-bite correction. *Am J Orthod Dentofacial Orthop.* 2010;138(3):254.e1-254.e10; discussion 254-6.
4. Maia FA. Visão clínica da planificação do tratamento ortodôntico. In: Maia FA. *Ortodontia: diagnóstico e planejamento.* São Paulo: Ed. Santos; 2010. cap. 12.
5. Maia FA, Maia NG. Unusual orthodontic correction of bilateral maxillary canine-first premolar transposition. *Angle Orthod.* 2005;75(2):266-76.
6. Maia FA, Maia NG. Correção da transposição de canino com primeiro pré-molar na maxila: um desafio ortodôntico possível. *Rev Clin Ortod Dental Press.* 2006;5(5):79-104.
7. Maia FA. Transposições dentárias: um dilema no tratamento ortodôntico. *Rev Dent Press Ortodon Ortop Facial.* 1999;4(4):21-35.
8. Maia FA. *Ortodontia: diagnóstico e planejamento.* São Paulo: Ed. Santos; 2010. 518 p.
9. Capelloza Filho L. *Diagnóstico em Ortodontia.* Maringá: Dental Press, 2004.
10. Maia FA. Características cefalométricas da má oclusão de Classe II/1, em brasileiros da região Nordeste, em fase de dentadura mista e permanente jovem [dissertação doutorado]. Bauru (SP): Universidade de São Paulo; 1993.
11. McNamara JA Jr. Components of Class II malocclusion in children 8-10 years of age. *Angle Orthod.* 1981;51(3):177-202.
12. Pancherz H. Treatment of Class II malocclusions by jumping the bite with the Herbst appliance. A cephalometric investigation. *Am J Orthod.* 1979;76(4):423-42.
13. Maia FA. Dez estratégias para o tratamento sem extração. In: Janson G, Garib DG, Silva Filho OG. *Programa de atualização em Ortodontia.* Porto Alegre: Artmed. No prelo.
14. Ruf S, Pancherz H. Temporomandibular joint remodeling in adolescents and young adults during Herbst treatment: A prospective longitudinal magnetic resonance imaging and cephalometric radiographic investigation. *Am J Orthod Dentofacial Orthop.* 1999;115(6):607-18.
15. Ruf S, Pancherz H. Orthognathic surgery and dentofacial orthopedics in adult Class II Division 1 treatment: mandibular sagittal split osteotomy versus Herbst appliance. *Am J Orthod Dentofacial Orthop.* 2004;126(2):140-52.