

Transversal changes in dental arches from non-extraction treatment with self ligating brackets

Liliana Avila Maltagliati¹, Yasushi Inoue Myiahira², Liana Fattori³, Leopoldino Capellozza Filho⁴, Mauricio Cardoso⁴

Objective: The present study aimed at analyzing, with the use of dental casts, the transverse changes of the upper and lower dental arches, after non-extraction orthodontic treatment, with self-ligating brackets.

Methods: The sample comprised 29 patients, all presenting Class I malocclusion with upper and lower crowding of at least 4 mm and treated only with a fixed appliance, without stripping, extraction or distalization. The dental casts were obtained before and after leveling with 0.019 x 0.025-in stainless steel archwires.

Conclusion: The results indicated that the majority of transverse changes occurred at the premolar areas, both the first and the second, as well as on the upper and lower dental arches. The intercanine distance increased 0.75 mm, on average, in the upper arch and 1.96 mm in the lower arch. The molars also demonstrated a tendency towards an increase in their transverse dimension, however, at a lower intensity comparing to premolars. All measurements presented statistically significant differences with the exception of the maxillary second molars.

Keywords: Corrective orthodontics. Dental models. Orthodontic brackets.

¹MSc and PhD in Orthodontics, Bauru School of Dentistry, University of São Paulo (USP).

²MSc in Orthodontics, School of Dentistry, Methodist University of São Paulo (UMESP).

³Professor, Specialization Course in Orthodontics, Straight-Wire Group of Rio de Janeiro.

⁴Professor, Graduation and Post-Graduation Program and MSc in Orthodontics, Sacred Heart University.

How to cite this article: Maltagliati LA, Myiahira YI, Fattori L, Capellozza Filho L, Cardoso M. Transversal changes in dental arches from non-extraction treatment with selfligating brackets. *Dental Press J Orthod*. 2013 May-June;18(3):39-45.

Submitted: November 09, 2009 – **Revised and accepted:** May 03, 2011

» The authors report no commercial, proprietary or financial interest in the products or companies described in this article.

Contact address: Liliana Avila Maltagliati
Rua Salete, 200 – Sala 42 – Santana – São Paulo/SP – Brazil
CEP: 02.016-001 – E-mail: lilianamaltagliati@hotmail.com

INTRODUCTION

Every orthodontic treatment has its foundation in the moment of diagnosis and planning. A correct diagnosis and a well-designed treatment plan are responsible for the success of the treatment, independent of the selected appliance to achieve the proposed objectives. There are several parameters and tests used to aid in the detection of anomalies and malocclusions affecting patients and guiding the planning, but knowledge of the effects that each appliance provides brings safety to the choice of treatment modality based on the goals set forth. Similarly, knowledge of a successful procedure and how stable it is also brings safety in using a treatment method.

Admittedly, dental malocclusion with dental crowding, can be treated by obtaining space in the arch that can occur in 5 ways: Archwire expansion, protrusion of the anterior teeth, dental extractions, stripping, or even distalization in the upper arch. In Class I malocclusion, the distal procedure presents itself as contraindicated, remaining two alternatives that reduce the arch perimeter and two others that increase the perimeter. To decide on the procedure, the orthodontist must ponder factors like facial convexity, type of mandibular growth, facial pattern, overjet and overbite, among others. Historically, it has been touted in the literature that the extraction procedures would be more stable than the expansion ones, unless through orthopedic expansion at an early age, when is possible to separate the intermaxillary suture with minimal buccal tooth movement.^{1,2,3}

There are countless studies in the literature dealing with maxillary expansion caused by rapid maxillary expansion and the skeletal and dental effects resulting from this procedure.⁴⁻⁹ The purely dental expansion is not accepted by orthodontists because of the alveolar limitation of this procedure, being reduced to only cases with very mild crowding or that permit a buccal tipping effect, especially on the anterior segment.

However, the literature is still not clear on this subject when it comes to stability, since the results of some studies have shown that the dimensions are more altered in the post-treatment period when extraction is performed as opposed to treating without extraction,¹⁰⁻¹³ and still others show that post-treatment stability is compromised in both cases with and without

extractions.^{12,14,15,16} Walter¹³ evaluated 50 cases without extractions and 50 with extractions, measuring the intercanine and intermolar widths in the pre and post-treatment periods and 1 year after removal of the retainers. A year after the removal of the retainers, there was a decrease in the intercanine and intermolar widths in cases with or without extractions, demonstrating that the canines and molars rarely remain stable after removal of the appliance, regardless of whether or not the extraction was performed. A similar outcome was found by Heiser et al.¹⁷

Shapiro¹⁸ sought to identify the alterations that occur in between the intercanine, intermolar widths and the arch length in the pre- and post-treatment phases and 10 years after retention in the lower dental arch in patients orthodontically treated, with or without extractions. Lower dental casts of 80 treated subjects were evaluated, who initially presented Class I or Class II malocclusions, division 1 or 2, measuring the intercanine distance, having the cusp tips of the canines as reference, and intermolar distances, based on the cusp tips of the first molars. The results showed a strong tendency of intercanine width to return to its initial dimension and the length of the dental arch to substantially decrease in all cases during the post-retention period. The intermolar width decreased more in patients treated with extractions, in the period between the phases before treatment and after retention. Several cases where intermolar expansions were obtained during treatment were maintained in the treated group without extractions, although, they tend to return to the initial dimension.

The presence of crowding in the arch, even in mild cases, which were treated without extraction, stripping or expansion, with a fixed appliance demand flaring of the teeth that occurs with greater intensity in the anterior region of the arch, since the occlusal contact of the posterior teeth further restricts the buccal movement and the anterior teeth, besides being smaller and being just juxtaposed, are generally more crowded and therefore more likely to yield to the buccal movement to accommodate all the teeth.

Due to the incisors flaring, instead of the buccal posterior movement to accommodate the crowded teeth, the procedure for correction of crowding would only be suitable for specific cases, such as cases

of incisors with lingual inclination, absence of narrow arches, or increased overjet.

When they were reintroduced in orthodontics, self-ligating brackets promised tooth movement with a significant reduction of friction. However, Damon¹⁹ raised another possibility that would involve the passive expansion of the arches by means of tooth movement in the buccal direction, due to the freedom of the wires in the slots which would slide in the posterior direction as the crowding is being solved and thus reduce the effect of incisor flaring. In cases with completed facial growth and negative discrepancy, in which the extraction could greatly harm the patient profile, this possibility would present itself as a big advantage for orthodontic treatment. Faced with the controversy that raises this issue, we decided to evaluate in dental casts the transverse changes resulted from a non-extraction treatment with self-ligating brackets.

MATERIAL AND METHODS

Fifty-eight pairs of dental casts were used for this research, 29 pre-treatment and 29 taken at the end of leveling with 0.019 x 0.025-in stainless steel wire. The sample consisted of 29 patients, 12 to 34 years old, all presenting with Class I malocclusion, with a minimum of 4 mm crowding in both upper and lower arch. All patients used Damon 2 brackets bonded with the VA point as a reference point in the center of the clinical crown and undergone a treatment protocol with a sequence of archwires as recommended by Damon,¹⁹ starting with the 0.014-in CuNiti archwire followed by the 0.016 x 0.025-in CuNiti archwire and finishing with the 0.019 x 0.025-in stainless steel archwire. No procedure was performed to obtain space, namely stripping, extraction, distalization or any procedure other than the sequential archwires exchange. To perform the measurements on the dental casts (Fig 1), it was used a Mitutoyo digital caliper with 150 mm capacity and a resolution of 0.01 mm, for it is a very accurate tool.

Dental measurements on cast models

The measurements were performed transversely, from the canines to the second molars in the upper and lower casts. With the caliper positioned parallel to the occlusal plane, it was measured the distance between the cusp tips of the canines, followed by the

buccal cusp tips of the first and second premolars and mesiobuccal cusp tips of the first and second molars.

To compare the significance of the transversal changes, it was used the Student t test, with a significance level of 5%. Ten percent of the sample was re-measured with a mean interval of 30 days to evaluate the systematic and random errors. The systematic error was insignificant for all variables except the transverse distance of the first molars that reached a p value of 0.03 and the random error had the higher value of 0.47 mm for the width measurement of the upper first molars

RESULTS

Table 1 shows random and systematic error values of the repetitive measurements evaluated by the Student t test and the Dahlberg's formula.

The initial and final measurements obtained in the dental casts are shown in Tables 2 and 3.

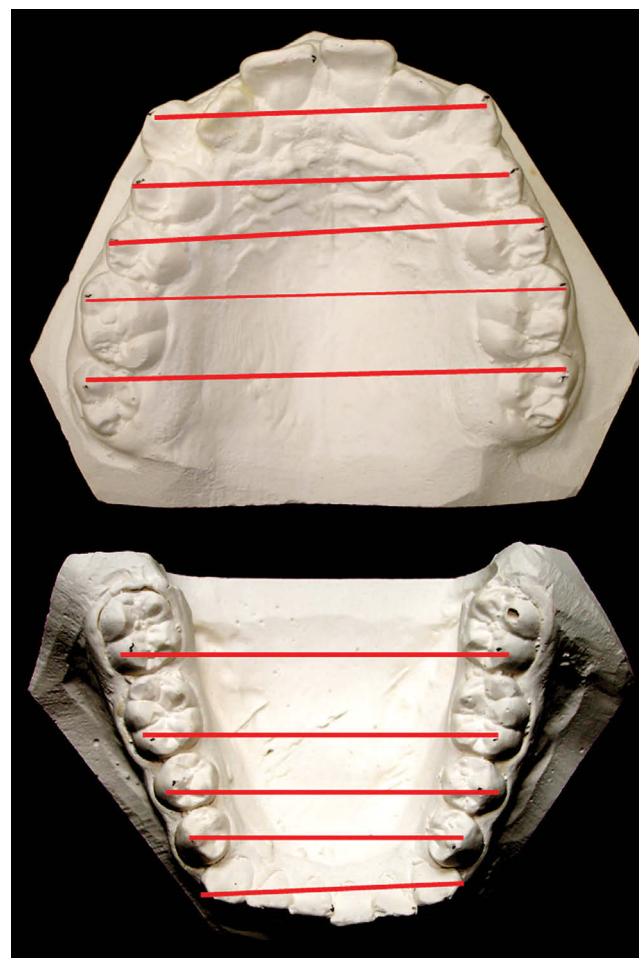


Figure 1 - Transverse measurements performed on the upper and lower casts.

DISCUSSION

By studying cases that were orthodontically treated successfully, Strang¹² noted that the initial lower intercanine and intermolar distances showed little or no variation in relation to the post-treatment values. He found that the muscle harmony should be preserved and that the forms and positions of the teeth of the upper arch are controlled by the characteristics of the lower arch, which in turn are imposed by the surrounding tissues. Thus, every effort should be made towards preservation of the muscular balance.

Grounded in such a theory as this,¹² Orthodontics understands that cases with crowding, which require space in the arch for correct alignment, should be treated by the extraction of teeth, as it is believed that, proceeding in this manner, the original arch shape is preserved, making the obtained occlusion more stable. The procedure has always been: First obtain the space and then move the displaced teeth, that is out of the arch due to the lack of space.^{10,14,15}

With the introduction of nickel titanium wires in the 80s, their property of great flexibility allowed

Table 1 - Systematic and random errors tests, for the upper and lower dental arches variables.

Upper arch	Mean 1 ± SD	Mean 2 ± SD	Dahlberg	t test	p
13 x 23	36.95 ± 3.83	36.92 ± 3.79	0.27	0.23	0.82
14 x 24	42.80 ± 3.79	42.85 ± 3.78	0.32	0.33	0.74
15 x 25	50.50 ± 4.77	50.34 ± 4.74	0.23	1.67	0.12
16 x 26	55.90 ± 1.67	55.82 ± 1.88	0.47	0.24	0.82
17 x 27	52.65 ± 4.36	52.12 ± 4.42	0.35	1.11	0.28
Lower arch	Mean 1 ± SD	Mean 2 ± SD	Dahlberg	t test	p
33 x 43	26.66 ± 3.14	27.00 ± 3.22	0.41	1.53	0.18
34 x 44	32.70 ± 3.91	32.90 ± 3.96	0.29	1.60	0.14
35 x 45	37.00 ± 3.54	37.06 ± 3.31	0.37	0.38	0.70
36 x 46	42.31 ± 3.91	42.52 ± 3.89	0.24	2.44	0.03*
37 x 47	46.46 ± 3.94	46.44 ± 3.87	0.28	0.18	0.85

*Statistically significant at $p < 0.05$.

Table 2 - Initial and final values, in millimeters, of the transverse measurements of the upper dental arch, standard deviations, mean difference, paired Student t test and p value.

Measurements	Initial average ± SD	Final average ± SD	Mean difference	t test	p
13 x 23	35.99 ± 2.47	36.74 ± 2.20	0.75	2.16	0.03*
14 x 24	41.59 ± 2.96	44.77 ± 2.34	3.18	7.19	0.01*
15 x 25	46.32 ± 3.31	49.66 ± 3.04	3.34	7.53	0.01*
16 x 26	52.13 ± 3.62	54.62 ± 11.24	2.49	7.08	0.01*
17 x 27	58.12 ± 4.02	58.16 ± 3.69	0.04	0.85	0.40

*Statistically significant at $p < 0.05$.

Table 3 - Initial and final values, in millimeters, of the transverse measurements of the lower dental arch, standard deviations, mean difference, paired Student's t test and p value.

Measurements	Initial average ± SD	Final average ± SD	Mean difference	t test	p
33 x 43	26.44 ± 2.40	28.40 ± 2.37	1.96	6.08	0.01*
34 x 44	34.49 ± 2.13	37.44 ± 2.02	2.95	8.41	0.01*
35 x 45	39.43 ± 3.03	42.82 ± 2.39	3.39	11.12	0.01*
36 x 46	44.90 ± 3.73	47.13 ± 2.93	2.23	6.09	0.01*
37 x 47	50.75 ± 3.52	53.12 ± 3.15	2.37	4.09	0.01*

*Statistically significant at $p < 0.05$.

mal-positioned teeth, even without space, to be connected to the wire. Still, this procedure continued to be contraindicated because the lack of space would require buccal movement of the teeth for aligning. It occurs because the crowding requires an increased archwire length to be ligated on the teeth, and the memory effect of these wires lead to a severe flaring. This effect, under conventional conditions, occurs mainly in the region of the incisors, because they are the teeth usually involved in crowding which have a lower resistance to movement, since there is no occlusal contact, as in the posterior teeth and are also the teeth with a smaller volume of crown and root.

Damon¹⁹ challenged the precepts of orthodontics to indicate that this paradigm to open space before and then proceed to the leveling of mal-positioned teeth can and should be broken, assuming that self-ligating brackets provide a significant reduction in friction, and when a light archwire is used, while alignment occurs, the archwire slides posteriorly, thus avoiding excessive anterior movement of incisor teeth and obtaining spaces mainly through a lateral dentoalveolar expansion, called the “posterior transverse adaption”. As the thermal active alloys release light forces, the tipping movement could also be reduced, since the moment created is reduced due to its direct relation to the force magnitude.

As stated by Bagden,²⁰ the tip of the system is to use light archwire in passive self-ligating brackets, giving great freedom for the wire inside the slot. With the friction and “binding” effect reduced, the teeth align more efficiently and with much less force than required for conventional brackets.

In accordance with this philosophy, the freedom of the wire causes the teeth to suffer the pressure of leveling, but without forcing the movement. Thus, the tooth tends to move towards areas of lesser resistance, i.e., where there is more space and no resistance to tooth movement. Furthermore, since there is no friction and the freedom of the wire is large, it tends to slide in the posterior direction as the teeth are leveled. This sliding allows the wire length — which is greater when inserted, since deflections must occur to fit the mal-positioned teeth — to do not cause excessive expansion of the arches, what leads the teeth to extremely buccal positions, as it easily slides through the adjacent brackets and remains on the distal of

the last tooth inserted on leveling, allowing greater control in the tooth movement and less protrusive effect in cases without extractions. The purpose of this study was to evaluate, in patients treated with self-ligating brackets and thermal active nickel titanium alloy wires, if it occurs, in fact, this later expansion by offering space in the arch and therefore reducing the need for protruding incisors, and verify how this treatment interferes with the intercanine distance in the upper and lower arches that could suggest a potentially unstable treatment.

INTERCANINE DISTANCE

Recognizing the canine teeth as corresponding to a stable structure and that any significant change in its position causes post-treatment movement which result in relapse, the less changes in its position, the better is the treatment.² Many clinicians and researchers believe that the shape of the mandible represents a state of structural and functional balance that should not be changed with treatment, according to cited by Burke et al.¹⁴ In this study, the upper intercanine distance presented an average expansion of 0.75 mm and the lower, 1.96 mm. This change reached a statistical significant index for both arches, although in the upper arch, on average, the change was smaller than in the lower arch. However, even if statistically significant, it is important to consider if this transverse alteration in the lower canines would be clinically important to cause, in the post-treatment period, a relapse that incurs in failure. To answer this question it is interesting to analyze the literature, and verify the expected alteration in this region with conventional orthodontic treatment. It would be interesting if it could be not modified, but the literature shows that this does not occur. Burke et al,¹⁴ through a meta-analysis, evaluated 26 studies that investigated the longitudinal stability of the intercanine distance. The studies they evaluated had different malocclusions with respect to Angle classification, cases treated with and without extraction and different treatment modalities. This data was checked to verify the relationship in the stability in the inter-canine dimension. The results showed that the intercanine distance tends to increase in the order of 1 to 2 mm, irrespective of malocclusion, treatment modality and treatment with or without extraction, and that this alteration tends to be lost in the post-reten-

tion period. Johnson,¹¹ also evaluated the intercanine and intermolar distances in dental casts of cases treated with and without extractions. An average increase of 0.8 mm in the intermolar distance was found, and 0.3 mm for the intercanine distance, while the maximum increase was 1.5 mm in one case without extraction, the intercanine distance did not change. Another interesting work was published by Araújo, Leite and Brito.¹⁰ The authors assessed the alterations in the intercanine distance in the lower arch in patients with Class I malocclusion, treated with and without extraction. The average increase in the intercanine distance observed during treatment was 1.35 mm in cases with extraction and 0.54 mm in cases without extraction. In the post-retention period, there was a reduction of this expansion in the order of 0.5 mm on average in patients treated with extraction and 0.13 mm in cases treated without extraction. In the present study, all patients were treated without extraction, with a minimum of 4 mm crowding in both arches and the changes observed during treatment, were within the parameters indicated in the literature as common in any type of treatment, making the treatment with low friction and thermal nickel titanium wires in cases of crowding, an additional option which tends to have the same degree of stability than any other protocol. Future works evaluating stability regarding the intercanine distance using this modality of treatment may bring greater clarity to the subject, as well as a correlation between the changes after retention and the degree of initial crowding or the amount of alteration observed in the active period of treatment. Once observed that the intercanine width undergoes alterations similar to other therapies, the question arises about where, indeed, there was a greater movement. For this, we also measured the transverse alterations in the premolars and molars region.

INTERPREMOLAR AND INTERMOLAR DISTANCES

In the present study, it was possible to verify that the major average transverse alterations occurred in the region of the premolars, especially in the maxillary arch. In the lower arch, there seemed to have a more uniform distribution of labial movement between the premolars and molars, but with even more intensity for the region of the premolars.

In the upper interpremolar distance, the average alterations surpassed 3 mm, reaching statistically significant values, with a value greater than three times the alteration in the intercanine distance. The molars had a smaller transverse increase, with a mean of 2.49 mm for the first molars, but with a statistical significance and the second molars practically did not alter. In the lower arch, the average alteration in the region of the premolars was 2.95 mm for the first premolars and 3.39 mm for the second premolar, indicating that they were on average 1 mm and 1.43 mm, respectively, larger than the intercanine distance. The difference in expansion between the canine and premolars in the mandibular arch was not as great as in the maxillary arch, however, the lower molars also suffered expansion, far more expressive than in the maxillary arch, especially in the second molar region, where there was an expansion average of 2.37 mm. This difference found between upper and lower second molars seemed to be related to the fact that the upper second molars erupted already, typically, in a more buccal position, being, so, little influenced by the expansion treatment, once they were in a more buccal position than the other teeth of the same arch. But in the lower arch, these teeth erupt with lingual tipping, suffering the influence of the treatment with buccal tipping. All measurements in the lower arch reached a statistical significance.

This difference in expansion, between the maxilla and the mandible, was also observed by Begole, Fox and Sadowsky.²¹ Evaluating 76 casts of 38 patients treated with and without extraction of the first premolars, these authors found that, in cases treated without extraction, significant differences were found between the maxillary expansion in relation to the mandible, greater for the maxilla, with the biggest increase in the region of the first and second premolars, except for the canines, which had similar expansions in both arches.

CONCLUSION

This result challenges conventional orthodontics when it proposes that the passive property of the bracket system, allowing all bonded brackets to function as tubes and applying extremely light forces due to the use of light and superelastic wires, allowing for a slow expansion of the dental arches, in many cases eliminating the need for rapid expansion, especially surgically assisted for the maxilla.

According to the results of this research, it seems clear that occurs, in fact, a lateral expansion, with buccal movement of the premolars, molars and to a lesser extent, of the canines, that provides space for leveling of initially crowded teeth, and most importantly, the alteration in the intercanine dimension was within the literature provides as normal for a conventional treatment, with or without extraction. It seems that the expansion was distributed throughout the dental arch, causing small buccal movement of all teeth, which together reached the space needed for leveling,

which also justifies that the alterations are not exaggerated, although they reached statistical significance for most measurements. However, other studies evaluating the movement of the upper and lower incisors in the dental casts, as well in radiographies, can help complete the understanding of how tooth movement occurs with treatment with nickel titanium wire in a low friction system and thereby verify, in relation to the alveolar bone, which are the modifications due to movements of the posterior teeth. These topics, however, will be addressed in future publications.

REFERENCES

- Riedel RA, Little RM, Bui TD. Mandibular incisor extraction: post retention evaluation of stability and relapse. *Angle Orthod.* 1992;62(2):103-16.
- Sadowsky C, Sakols EI. Long-term assessment of orthodontic relapse. *Am J Orthod.* 1982;82(6):456-63.
- Uhde MD, Sadowsky C, BeGole EA. Long-term stability of dental relationships after orthodontic treatment. *Angle Orthod.* 1983;53(3):240-52.
- Sandıkçioğlu M, Hazar S. Skeletal and dental changes after maxillary expansion in the mixed dentition. *Am J Orthod Dentofacial Orthop.* 1997;111(3):321-7.
- Adkins MD, Nanda RS, Currier GF. Arch perimeter changes on rapid palatal expansion. *Am J Orthod Dentofacial Orthop.* 1990;97(3):194-9.
- Sarver DM, Johnston MW. Skeletal changes in vertical and anterior displacement of the maxilla with bonded rapid palatal expansion appliance. *Am J Orthod Dentofacial Orthop.* 1989;95(6):462-6.
- Davis WM, Kronman JH. Anatomical changes induced by splitting of the midpalatal suture. *Angle Orthod.* 1969;39(2):126-32.
- Haas AJ. The treatment of maxillary deficiency by opening the midpalatal suture. *Angle Orthod.* 1965;35(3):200-17.
- Haas AJ. Entrevista com Andrews Haas. *Rev Dental Press Ortod Ortop Facial.* 2001;6(1):1-10.
- Araújo PRR, Leite HR, Brito HHA. Avaliação das alterações na distância intercaninos do arco inferior em pacientes com má oclusão de classe I tratados ortodonticamente. *Rev Dental Press Ortod Ortop.* 2007;12(2):105-14.
- Johnson KC. Cases six years postretention. *Angle Orthod.* 1977;47(3):210-21.
- Strang RHW. The fallacy of denture expansion as a treatment procedure. *Angle Orthod.* 1949;14(1):12-22.
- Walter DC. Comparative changes in mandibular canine and first molar widths. *Angle Orthod.* 1962;32(4):232-41.
- Burke SP, Silveira AM, Goldsmith LJ, Yancey JM, Van Stewart A, Scarfe WC. A meta-analysis of mandibular intercanine width in treatment and postretention. *Angle Orthod.* 1998;68(1):53-60.
- Erdinc AE, Nanda RS, Işiksal E. Relapse of anterior crowding in patients treated with extraction and nonextraction of premolars. *Am J Orthod Dentofacial Orthop.* 2006;129(6):775-84.
- Rossouw PE, Preston CB, Lombard C. A longitudinal evaluation of extraction versus nonextraction treatment with special reference to the posttreatment irregularity of the lower incisors. *Semin Orthod.* 1999;5(3):160-70.
- Heiser W, Richter M, Niederwanger A, Neunteufel N, Kulmer S. Association of the canine guidance angle with maxillary and mandibular intercanine widths and anterior alignment relapse: extraction vs nonextraction treatment. *Am J Orthod Dentofacial Orthop.* 2008;133(5):669-80.
- Shapiro PA. Mandibular dental arch form and dimension: treatment and postretention changes. *Am J Orthod.* 1974;66(1):58-70.
- Damon D. The rationale, evolution and clinical application of the self-ligating bracket. *Clin Ortho Res.* 1998;1(1):52-61.
- Bagden A. The Damon system: questions and answers. *Clin Impress.* 2005;14(1):4-13.
- Begole EA, Fox DL, Sadowsky C. Analysis of change in arch form with premolar expansion. *Am J Orthodont Dentofacial Orthop.* 1998;113(3):307-15.