

Matheus Melo Pithon*

ELECTRIC TOOTHBRUSH PROMOTES BETTER CLEANING FOR PATIENTS WITH FIXED ORTHODONTIC APPLIANCE

Patients with fixed orthodontic appliance find it much more difficult to clean their teeth. The presence of brackets, wires, elastics, buttons and other accessories promote greater plaque retention, favoring the appearance of white spot lesions, dental caries and periodontal disease. Daily, orthodontists see patients with dirty teeth. What must be done in these situations? There are various devices and resources available for cleaning these patients' teeth. Among these, manual and electric toothbrushes are very important. Would electric toothbrushes be more effective in cleaning compared with the manual type? To answer these questions, German and American researchers conducted a clinical study¹ in which they evaluated the effectiveness of manual, conventional electric, and orthodontic electric toothbrushes (Fig 1) in cleaning the teeth of patients using fixed orthodontic appliances. The authors were able to verify that electric brushes performed better cleaning when compared with the manual type. In the comparison between electric brushes, the specific type for orthodontic use, promoted greater cleanliness. The findings of this study are relevant and important, because orthodontists have gained proof of a new ally in the maintenance of their patients' oral health.

SEALANT REDUCES THE APPEARANCE OF WHITE SPOT LESIONS IN ORTHODONTIC PATIENTS

As mentioned in the previous article, there is constant concern about the hygiene of orthodontic patients all over the world. Development of a material that reduces the appearance of caries lesions in these patients is a dream we all share. Day by day, material industries launch new products for this purpose, including sealants. These material are indicated for application on the enamel around brackets, with the intention of preventing the appearance and progression of caries lesions dur-

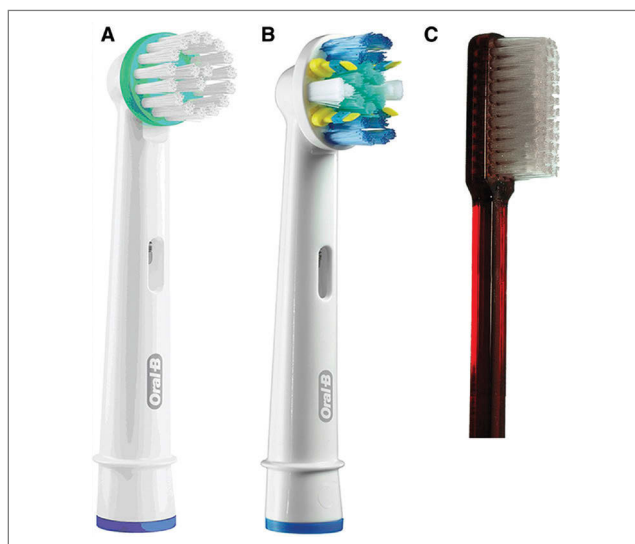

Figure 1 - Brushes evaluated in the study conducted by Erbe et al¹: A) electric with orthodontic head; B) electric with conventional head; C) manual.

ing the period the fixed orthodontic appliance is in use. However, there has been little scientific proof reported regarding these materials. The industry that develops these products is frequently satisfied only with launching them on the market, backed by laboratory studies, without conducting clinical trials. With the purpose of obtaining these clinical results, Porto Rican and American researchers developed a multi-centric study evaluating the effectiveness of these sealants in patients using orthodontic appliances.² The results found in this study demonstrated that the studied sealant presented the capacity of preventing the appearance of white spot lesions. However, the authors pointed out that the sealant does not prevent all lesions, nor does it provide protection throughout the period of experimentation. Nevertheless, the results present good future perspectives.

TOOTH EXTRACTIONS DO NOT COMPROMISE THE NASOPHARYNGEAL AIRSPACE

Over the years, orthodontics has increasingly adopted a multidisciplinary approach for patient treatment. For a long time, occlusion remained the main focus of the

How to cite this article: Pithon MM. Orthodontics highlights. Dental Press J Orthod. 2013 July-Aug;18(4):8-9.

Submitted: February 14, 2013 - **Revised and accepted:** February 20, 2013

Contact address: Matheus Melo Pithon
E-mail: matheuspithon@gmail.com

*Professor, Southwest Bahia University (UESB), Bahia, Brazil. MSc and PhD in Orthodontics, Federal University of Rio de Janeiro, (UFRJ). Diplomate of the Brazilian Board of Orthodontics and Dentofacial Orthopedics (BBO).

orthodontic world, sharing space with facial analysis and the inter-relations with the airways. Would orthodontic treatment be related to changes in these structures? Nowadays, it is known that improvements are achieved when orthodontic treatment is accompanied by surgical procedures, such as mandibular advancement for the correction of Class II malocclusion. However, little is known with respect to what the behavior of these structures would be in the face of the simplest and most common procedures for the orthodontist, such as for example, the extraction of permanent teeth. To elucidate this question, researchers of Turkish and American universities evaluated the effect of tooth extractions on the nasopharyngeal airspace.³ Tomographic images were obtained from patients who underwent extraction of the four first premolars. The results proved there was no reduction in the airway space with the extractions (Fig 2). These results demystified the idea that extractions influence the tongue by positioning it posteriorly, making air passage difficult, as a consequence of reduction in arch length.

OVERWEIGHT PATIENTS ARE LESS COOPERATIVE WITH ORTHODONTIC TREATMENT

As a severe public health problem, obesity figures among one of the greatest epidemics of the century. Excess weight compromises the individual socially and physically (cardiac, metabolic and osteoarticular alterations), frequently generating irreversible problems in patients. But, how could our orthodontic treatment be affected by this problem? German researchers developed a study seeking answers to these questions.⁴ They evaluated the cooperation, oral hygiene, care of orthodontic devices and time of treatment among patients with a normal body mass index (BMI) and individuals with increased BMI. The authors concluded that patients with an increase in body mass index did not cooperate as well during treatment, leading to the total treatment time of these individuals being longer than that of adolescents with normal BMI. The authors themselves pointed out that new studies need to be conducted to evaluate the reason for this association. Would it be due to social alterations? Or as a result of physical alterations?

FEMALE ADOLESCENTS REPORT MORE PAIN DURING ORTHODONTIC TREATMENT

A frequent complaint among patients, after orthodontic appointments, is post-activation pain. Without any doubt,

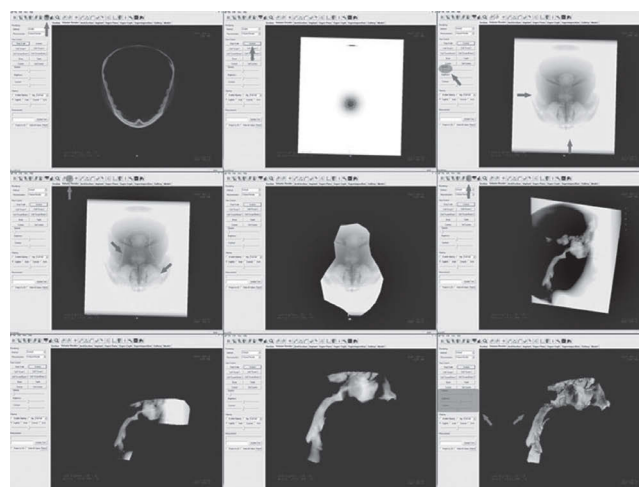


Figure 2 - Obtaining the image of the pharyngeal airway space (Source: Stefanovic et al,³ 2013).

this is one of the reasons that affects the most the patient motivation to begin with an orthodontic treatment. We all believe that orthodontic movement functions by means of a mechanism of inflammation, a process that always involves pain. Identifying the group of patients most sensitive to pain is important, in order to adjust measures that minimize this process. Starting with this premise, in the present study the authors' proposal was to evaluate, with the use of questionnaires, the interaction between orthodontic post-activation pain and the adolescents gender.⁵ It was concluded that girls in the 14 to 17 year age group presented higher levels of pain compared with boys. The results showed the need to perform activations with lighter forces in this group of patients, thereby avoiding greater complaints with respect to the treatment being performed, and obtain better cooperation.

REFERENCES

1. Erbe C, Klukowska M, Tsaknaki I, Timm H, Grender J, Wehrbein H. Efficacy of 3 toothbrush treatments on plaque removal in orthodontic patients assessed with digital plaque imaging: a randomized controlled trial. *Am J Orthod Dentofacial Orthop.* 2013;143(6):760-6.
2. O'Reilly MT, Vinas JD, Hatch JP. Effectiveness of a sealant compared with no sealant in preventing enamel demineralization in patients with fixed orthodontic appliances: a prospective clinical trial. *Am J Orthod Dentofacial Orthop.* 2013;143(6):837-44.
3. Stefanovic N, El H, Chenin DL, Glisic B, Palomo JM. Three-dimensional pharyngeal airway changes in orthodontic patients treated with and without extractions. *Orthod Craniofac Res.* 2013;16(2):87-96.
4. Bremen J, Wagner J, Ruf S. Correlation between body mass index and orthodontic treatment outcome. *Angle Orthod.* 2013;83(3):371-5.
5. Sandhu SS, Sandhu J. Orthodontic pain: an interaction between age and sex in early and middle adolescence. *Angle Orthod.* 2013 May 24. [Epub ahead of print].

An interview with

Jonas Capelli Júnior



- » PhD and Full Professor in Orthodontics, Rio de Janeiro State University (UERJ).
- » Associate Professor of Orthodontics, UERJ.
- » Director of the Brazilian Board of Orthodontics and Dentofacial Orthopedics (BBO).
- » Peer-reviewer of the following journals: *Archives of Oral Biology*, *Dental Press Journal of Orthodontics*, *European Journal of Orthodontics*, *Journal of Biomechanics*, *Journal of the World Federation of Orthodontists* and *The Angle Orthodontist*.

All young people have an idol to follow, which can be a rock star or a great professor. Many people, including the greatest professors, do not realize their positive influence in their students' education. When I started the specialization course in Orthodontics at the Rio de Janeiro State University (UERJ), I knew nothing about this specialty, dentist's offices or teaching, and I needed orientation. Having good-hearted and altruist professors determined the path I should follow. Among such professors, I would like to highlight Prof. Jonas Capelli Jr. — the expert I present in this interview. Being from the first class of the course, he has always been a model to us. Dr. Capelli Jr. is the Director of the Brazilian Board of Orthodontics and Dentofacial Orthopedics (BBO) and has received many awards, such as the CDABO Case Report of the Year, for the best case report published during 2007 in the AJO-DO. In addition, he has had more than 60 articles published in scientific journals. Therefore, coordinating this interview could not be more rewarding and satisfactory to me. I proudly claim that it will provide us with a wide range of expertise concerning our clinical and scientific practice within our beloved field. In addition, this interview will allow us to know more about the professor who has been considered a positive and inspiring milestone in his students' lives as well as in the history of Brazilian Orthodontics.

Sissy Maria Mendes Machado

How to cite this interview: Capelli Júnior J. Interview. *Dental Press J Orthod*. 2013 July-Aug;18(4):10-28.
Submitted: February 14, 2013 - **Revised and accepted:** March 7, 2013

» Patients displayed in this interview previously approved the use of their facial and intraoral photographs.

Is there any clinical difference in the quality of smile esthetics diagnosis performed by photographs and filming? Carlos Alexandre Câmara

In Orthodontics, three methods are commonly suggested when studying the smile, namely: Qualitative, semi-quantitative and quantitative methods. The qualitative method is strictly visual; the orthodontist looks at the patient's smile and assesses, for instance, the smile line height. In the semi-quantitative method, analysis of the smile is performed by means of photographs, while in the quantitative method, the smile line height is determined with the aid of measurement instruments and may vary from the simplest to the most sophisticated approaches.¹

Capturing the smile image through photography presents many drawbacks. Photograph standardization is difficult due to differences in camera positioning, distance control between the patient and the focal point, head angle and the impossibility of reproducing the same smile in different photography sessions.²

Capturing an image through filming, creating a video for subsequent analysis with computer software seems to be a very efficient method for the dynamic analysis of speech and smile.³

Clinically speaking, I believe that the quality of esthetic diagnosis may be well established through photography. Moreover, the orthodontist is in contact with the patient during the first appointment, which gives the specialist the opportunity to observe all variables involved in the process of diagnosis. On the other hand,

with regard to researches involving smile analysis at different time intervals, in which different measures are carried out, recording video images seems to be a valuable tool. Our studies with videos in which patients are encouraged to say a sentence and then smile seem to be highly efficient for analyzing the exposure of teeth and soft tissues at different time intervals.^{4,5}

These videos last for about 12 seconds, comprising a total of 360 frames per video. They are analyzed and split up – at rest, during speech and smile — in order to produce four static frames (corresponding to a photograph) for analysis of the least and the greatest exposure of the incisor, for example. Figure 1 demonstrates an example of this method.

What are the main esthetic parameters that guide your orthodontic treatment plan?

Carlos Alexandre Câmara

Our main parameters are listed below and illustrated in Figures 2 to 7:

1) Incisor exposure (Fig 2): Taking into account the length and elevation of the lip as well as the vertical height of the maxilla.

2) Negative lateral space or buccal corridor (Fig 3): There are many publications, comprising studies developed with digital image manipulation, which present different options of buccal corridor exposure. It seems to be common sense that minimal corridors are more attractive.^{2,3,5}

3) Smile arc (Fig 4): Taking into account that, in an ideal smile arc, the curvature of the incisal edge of the maxillary incisors coincides with the margin of the lower lip when smiling (“consonant”). The lower lip may touch, not touch or slightly cover the incisal edge of the maxillary incisors.

4) Upper lip curvature (Fig 5) — Three options: upward, when the commissure is higher than the center of the lip; straight, when the commissure and the center of the lip are leveled; downward, when the commissure is lower than the center of the lip. Upward and straight curvatures are considered more esthetic than the downward curvature. The upper lip curvature is guided by the facial muscles; therefore, it cannot be changed through orthodontic treatment.

5) Smile symmetry (Fig 6): Commissures move upward and laterally when smiling, but there may be some difference in amount and direction of movement

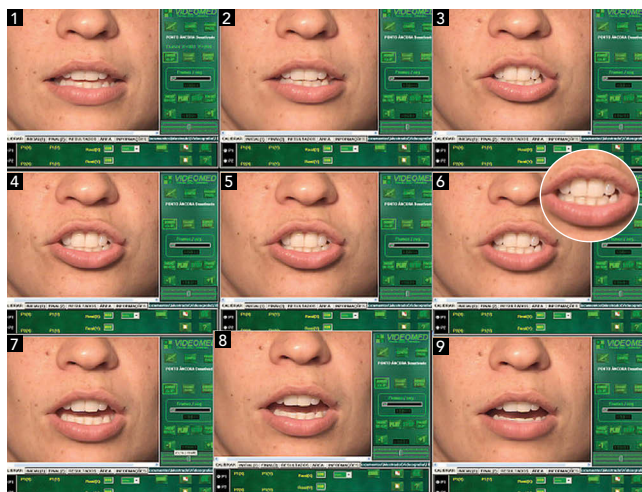


Figure 1 - Video split up into static frames. Frame number 6 (amplified) shows the maximum incisor exposure when patients pronounced the sound “Czech”, as in Czechoslovakia.

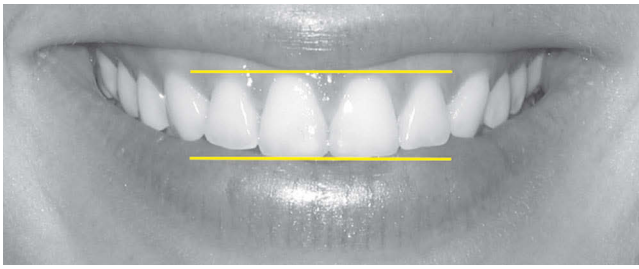


Figure 2 - Upper incisor exposure directly associated with both length and elevation of the upper lip.

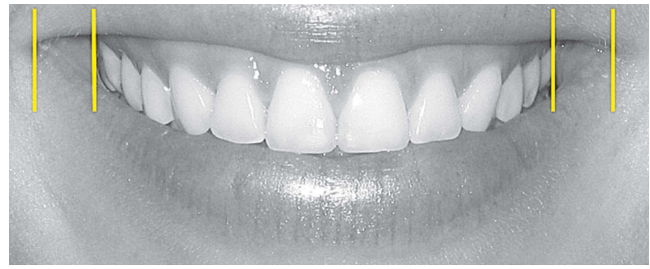

Figure 3 - Examples of negative lateral space or buccal corridor.

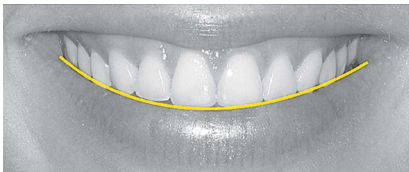


Figure 4 - Examples of consonant smile arcs.

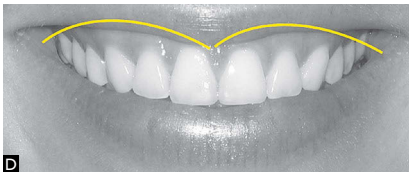
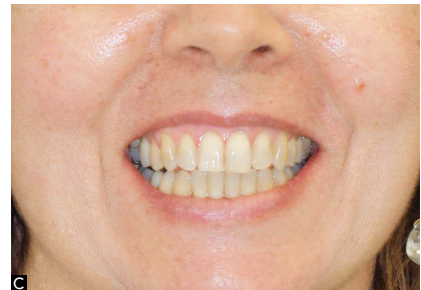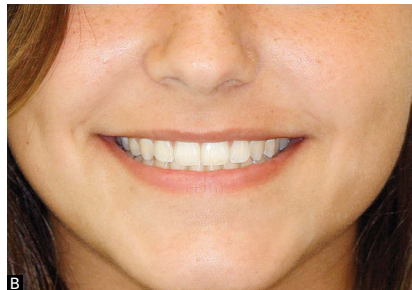
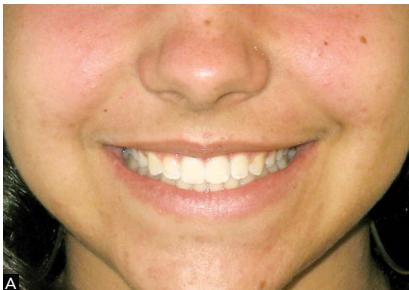

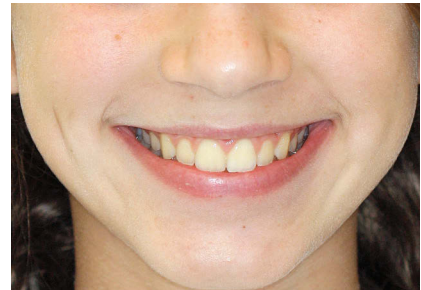
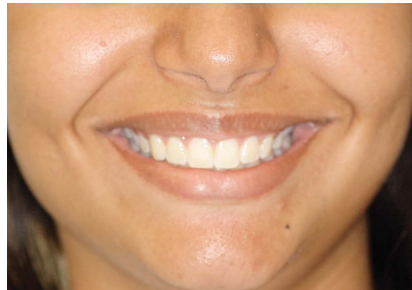Figure 5 - Upper lip curvature (D). Examples of the three types of curvature: Upward (A), straight (B) and downward (C).

between the right and the left sides. Should there be any significant difference, it may be due to deficiency of muscular tonus in one of the sides of the face.

6) Frontal occlusal plane (Fig 7): Represented by a line that goes from the incisal edge of the upper right canine to the incisal edge of the upper left canine. Transversal inclination may be caused by a difference in eruption time or due to skeletal asymmetry.

Clinical examinations are essential to perform a differential diagnosis to distinguish between smile asymmetry, occlusal plane inclination and facial asymmetry. The influence of the lower teeth on the smile cannot be seen in dental cast models.

7) Dental components: taking into account the size, shape, color, alignment, angulation and midline. There are great studies which comprise such content.⁹

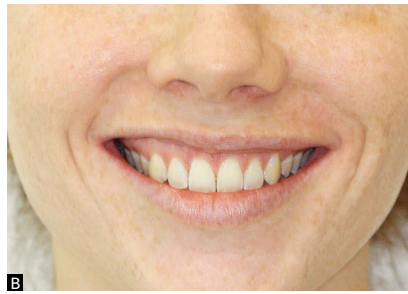
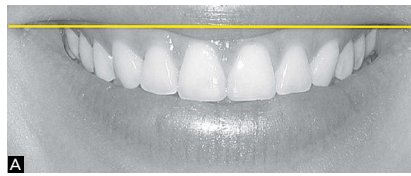

Figure 6 - In a symmetric smile (A), commissures move upward harmoniously. In B, asymmetry is remarkable, due to right commissure elevation being higher than the left one – such conditions cannot be changed through orthodontic therapy.

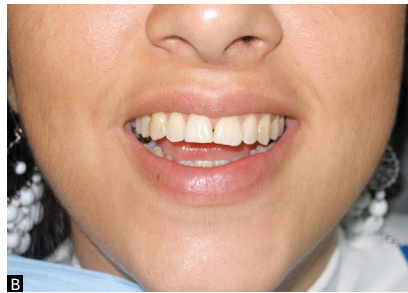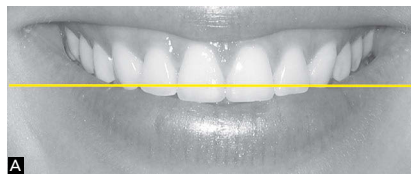


Figure 7 - Frontal occlusal plane represented by a line that goes from the right canine to the left canine (A). Transversal inclination may be caused by a difference between the time of eruption or skeletal asymmetry. In B, example of frontal occlusal plane inclination.

Patient's age is another esthetic parameter which I consider essential for treatment plan. Over time, men and women present less exposure of maxillary incisors and greater exposure of mandibular incisors, due to the fact that the length of the upper lip increases, while the length of the lower lip decreases with age. It has been proven that the amount of exposure of mandibular incisors after 60 years of age is equivalent to the amount of exposure of maxillary incisors before 30 years of age.¹⁰

With aging, the lips go through many changes which affect the exposure of teeth. For example, muscle atrophy that implies in decreased lip volume, changes in lip shape and increased length of the lips. Such changes highlight the importance of normative values according to age, allowing older patients to have their treatment plan objectively and precisely carried out.¹¹

After the age of 40, there is a 2 mm mean loss of muscle capacity to lift up the upper lip. This contributes to age one's appearance, since upper anterior teeth are hidden by the upper lip at smile.¹¹

When a patient of such age comes to me complaining about dissatisfaction concerning crowding of mandibular incisors, claiming that he/she is dissatisfied with his/her appearance in photographs and that he/she has recently noticed this situation, I suppose that such

crowding had already been there for a long time, but has been recently noticed.

Deepening of the nasolabial angle is another consequence of aging, causing great esthetic impact. As time goes by, there is loss of cheek prominence due to atrophy, making the skin loose. As the cheek becomes flaccid, the elevator muscles of the upper lip pull the nasolabial folds upward, resulting in a deep nasolabial angle.

When preparing the orthodontic treatment plan, the orthodontist should consider the patient's age, due to the fact that with aging, many changes concerning the exposure of incisors occur. Generally speaking, it is better to rejuvenate the patient's appearance than aging it. In severe overbite cases, especially in adult patients, it is more advisable to intrude mandibular incisors than maxillary incisors, in order to ensure a young and esthetic smile by the end of the treatment. Should it be necessary to intrude maxillary incisors, the orthodontist must assess not only the exposure of the incisors at rest and speech, but also the patient's age and sex, quantifying how much intrusion will be possible without compromising esthetics. With regard to excessive gingival display, it is generally better to treat gingival smile in a less aggressive way, due to the fact that aging will naturally reduce this feature.¹²

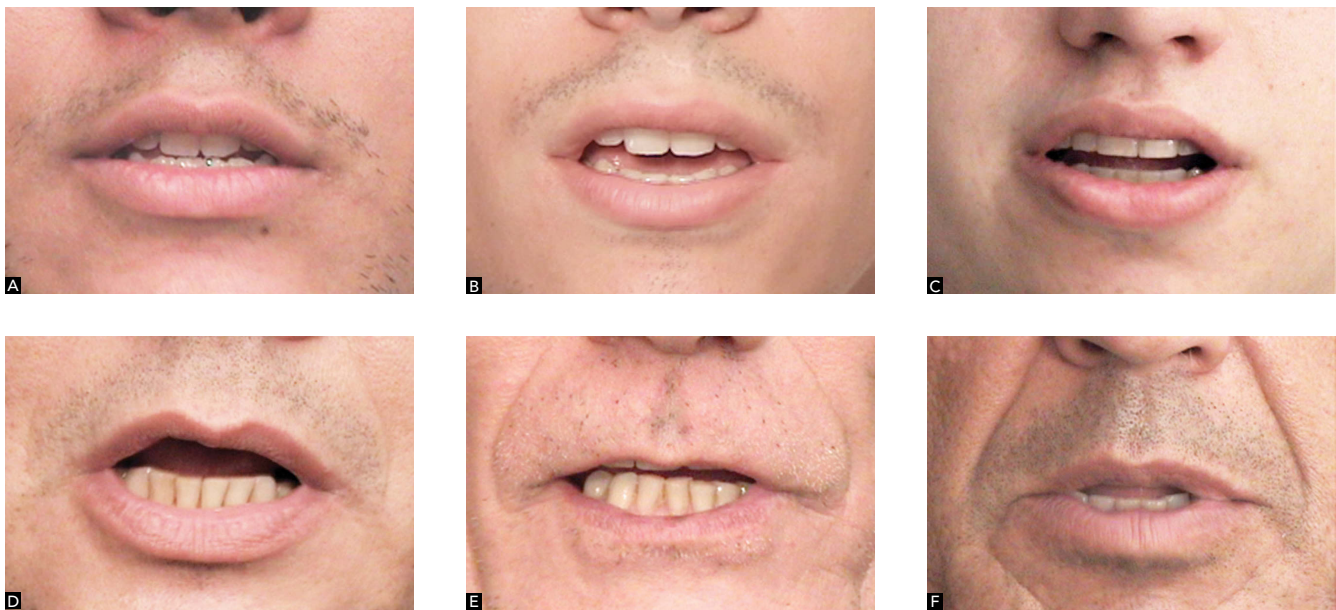

Figure 8 - Exposure of upper incisor is greater in younger individuals (A, B, C) while exposure of lower incisor is greater in elder individuals (D, E, F).

Our researches carried out at the Rio de Janeiro State University/Brazil (UERJ) also suggest that men are more likely to suffer the effects of aging than women. A comparative example regarding these differences is demonstrated in photographs of young and older men, as shown in Figure 8. Many factors may turn a young skin into a precociously aged skin, namely: sun exposure, smoking, stress, hormonal changes, medicines and unhealthy eating habits. The main villain has always been excessive sun exposure. Therefore, excessive sun exposure, due to sports practice or outdoor activities, without proper protection from UV radiation, may be one of the factors that influence the fact that men are more affected by the effects of aging. However, it is important to consider that smoking has been the main cause of early aging, as it directly acts upon the epithelium elastic fibers and collagen matrix.⁵

In the last few years, some authors have questioned how valid is to use a simple photograph to assess esthetics and determine the patient's treatment plan. They have suggested the use of dynamic images recorded in video. In your opinion, capturing dynamic images through filming, in order to use them for the diagnosis and treat-

ment plan in Orthodontics, is a valid method?

Sissy Mendes Machado

Smile analysis performed through standardized photographs may be used as a subsidiary method for diagnosing and planning orthodontic and surgical treatments, allowing assessments before and after the treatment. Additionally, it may be considered a reliable instrument for comparing pre and posttreatment phases. However, it is important to highlight that this technique may be considered dubious, as it does not represent a smile apex. Video recording may provide larger information for facial esthetic assessment.^{4,5}

Dynamic analysis of speech and smile has been made possible because of technology. Current low prices and popularization of digital cameras have facilitated access to this type of equipment. Photo editing programs are available in most computers. This facilitated the identification of both positive and negative aspects of facial esthetics, enabling, for example, observation of the effects of aging in the perioral soft tissues. Videography may be used in orthodontic practice with many purposes, such as diagnosis and treatment plan, communication between specialist and patient during appointments and communication between specialists.⁴

There has been increasing awareness among professors, researchers and clinicians about the importance of biology for orthodontic practice and this has been reflected in the curriculum of the main Orthodontics programs in the world. Why is it important for the orthodontist's formal education to be familiar with the biology of tooth movement? Ildeu Andrade Jr.

The postgraduate programs in Orthodontics have always favored formal education and training based on orthodontic mechanics, as all credit hours are spent with studies performed with typodont simulator. However, Orthodontic clinical practice is based in both mechanical and biological parameters. The mechanical approach is enough for treatments performed on the typodont, however, in clinical practice, knowledge of biology involved in the process is necessary. I am a die-hard fan of the mechanotransduction definition: Mechanical forces applied to teeth do not result in mechanical movement only, they also produce biological stimuli capable of promoting desirable tissue reactions in order to achieve a stable and long-lasting change in tooth position.¹³ The clinical practice of this definition lead us to question the claims concerning the types of brackets or techniques offering drastic reduction in treatment duration. Whenever I see an advertisement or a presentation stating this type of offer, I begin to think: Is this capable of promoting a differentiated biological stimulus? If not, what explains the hypothesis of reducing treatment duration?

The main orthodontic journals in the world have provided more opportunities for the publication of researches into biology of tooth movement. In your opinion, what are the benefits – for us, orthodontists and for our patients – of the increasing interaction between biological and clinical researches in Orthodontics? Ildeu Andrade Jr.

We have conducted a survey at PubMed, in March 2013, which reveals an increase in the number of publications available in the literature, when the keywords “orthodontic tooth movement” were used (data is shown in Fig 9).

There are many reasons for this increasing number of publications. First, the total amount of scientific journals has significantly increased, providing the opportunity for the publication of scientific findings. We are currently facing the dilemma of what we should read due to the

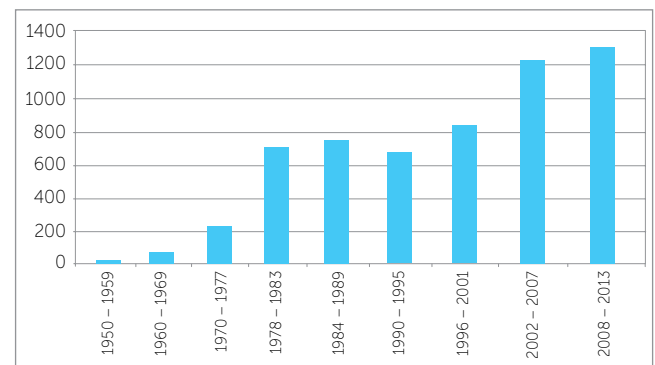


Figure 9 - Total number of publications available in the literature using “orthodontic tooth movement” as keywords. Source: www.ncbi.nlm.nih.gov/pubmed.

great amount of information that is available. However, I believe that the main reason for this increasing number of publications is the development of researches that have as final outcome the publication of their results. Researches carried out with biomarkers aim at studying not only orthodontic tooth movement in many different situations, but also root resorption as well as accelerated and decelerated tooth movement. Such researches, which frequently involve molecular biology analysis, have contributed for a significant increase in the number of publications in the 2000s, especially in the last five years.^{14,15} Our studies involving the quantification of different markers present in the gingival crevicular fluid while moving teeth aim at understanding what happens when we apply forces to induce tooth movement.¹⁶ As a researcher, I aim at understanding the cascade of biological events involved in tooth movement. The main benefit for the orthodontist is to understand why his patients react differently to the same mechanics, same appliances and same activations. Why do patients react differently towards the gains and sequelae of orthodontic treatment? Force modulation being the only variable used to answer that seems to be a simplistic approach towards a more complex issue.

In your opinion, what are the future prospects and the potential clinical impacts of researches on the cellular and molecular mechanisms involved in biology of tooth movement?

Ildeu Andrade Jr.

Our initial studies on gingival crevicular fluid (GCF) were based on Periodontology researches which claim that the GCF flow may increase by 30 times in periodontitis, when compared to healthy sulcus.¹⁷ As orthodontic tooth movement has inflam-

mation-dependent characteristics, we believe that the GCF volume would increase during this movement. However, we have observed that such data are not consistently expressed. The GCF volume does not seem to be a reliable biomarker used for the analysis of tissue remodeling during orthodontic treatment.¹⁸⁻²¹

With regard to periodontal patients, we based our studies upon previous evidence which claim that clinically healthy sites of patients with periodontitis have greater levels of GCF and periodontal pathogen biomarkers than clinically healthy sites of patients without periodontitis.²² In other words, periodontal patients would be considered as high-risk patients for orthodontic treatment, as pro-inflammatory markers originated from periodontal diseases have been superposed onto those markers activated by tooth movement. It is a chaotic scenario! However, a study carried out with periodontal patients undergoing tooth movement reveals that orthodontic movement of periodontally compromised teeth does not result in significant changes of matrix metalloproteinase in the GCF.²³ Clinically speaking, this is a great finding as it assures us that moving periodontally compromised teeth, yet healthy, is possible.

With regard to future prospects, it is necessary to have a better understanding concerning the molecular constituents of the gingival crevicular fluid which are more sensitive to orthodontic tooth movement, the meaning of GCF as well as its biological function. Studies on GCF have enabled non-invasive monitoring of tissue remodeling and may serve as a good tool for researches on tooth movement, root resorption or dental ankylosis. The more we know about the biological mechanisms of orthodontic tooth movement, the earlier we shall develop local administration methods of medication. Local application of bioactive agents associated with conventional biomechanics may be used to facilitate or hinder tooth movement.

In clinical practice, orthodontic treatment performed in adults is different from treatment performed in adolescents, as adults are more likely to have compromised dentitions. Based on your experience with biological studies on tooth movement, what would be the most appropriate treatment plan for adult patients with bone loss and clinical attachment loss caused by jeopardizing

the biological space or by previous periodontal diseases, taking into account biomechanical and functional properties? Sissy Mendes Machado

Orthodontic treatment of patients with periodontal disease may not be faced as a common treatment. All orthodontic cases require effective diagnosis and planning. However, this practice is more difficult in periodontal patients. We must bear in mind that all types of treatment must benefit the patient. When the periodontium is compromised and the orthodontic plan is defective, the chances of harming the patient, due to an improperly performed treatment, are high. Therefore, such cases require integration between specialists. The patient should not start orthodontic tooth movement without his periodontist's approval, and the periodontist must follow-up the periodontal situation during orthodontic treatment.^{25,26} Figures 10, 11 and 12 show a good example of tooth movement in a patient with little periodontal attachment.

Tooth movement should not be performed in patients with periodontal diseases for many reasons, namely: 1) It may cause periodontal abscess, especially in deep periodontal pockets; 2) After periodontal therapy, edema is eliminated and gingival collagen fibers consolidate, leading to tooth accommodation which may be favorable to tooth alignment and, thus, reduce the duration of a subsequent orthodontic treatment; 3) At the beginning of orthodontic treatment, it is important to know the height as well as the density of the bone surrounding the teeth. Such information may be observed by the periodontist during surgery and provided later on to the orthodontist.^{25,26}

The orthodontic treatment of patients with controlled periodontal diseases is usually shorter and direct. Reduction in the periodontium generates important implications for orthodontic tooth movement. There is a direct linear relationship between the alveolar support and the localization of the center of resistance. As the alveolar bone support reduces, the center of resistance moves apically. Both the intensity and the point of force application during orthodontic treatment must be adapted in such situations. The applied forces must be lower than those applied to healthy periodontium. In order to control tooth movement — due to the fact that the center of resistance is apically located — all accessories must be bonded closer to the gingiva.

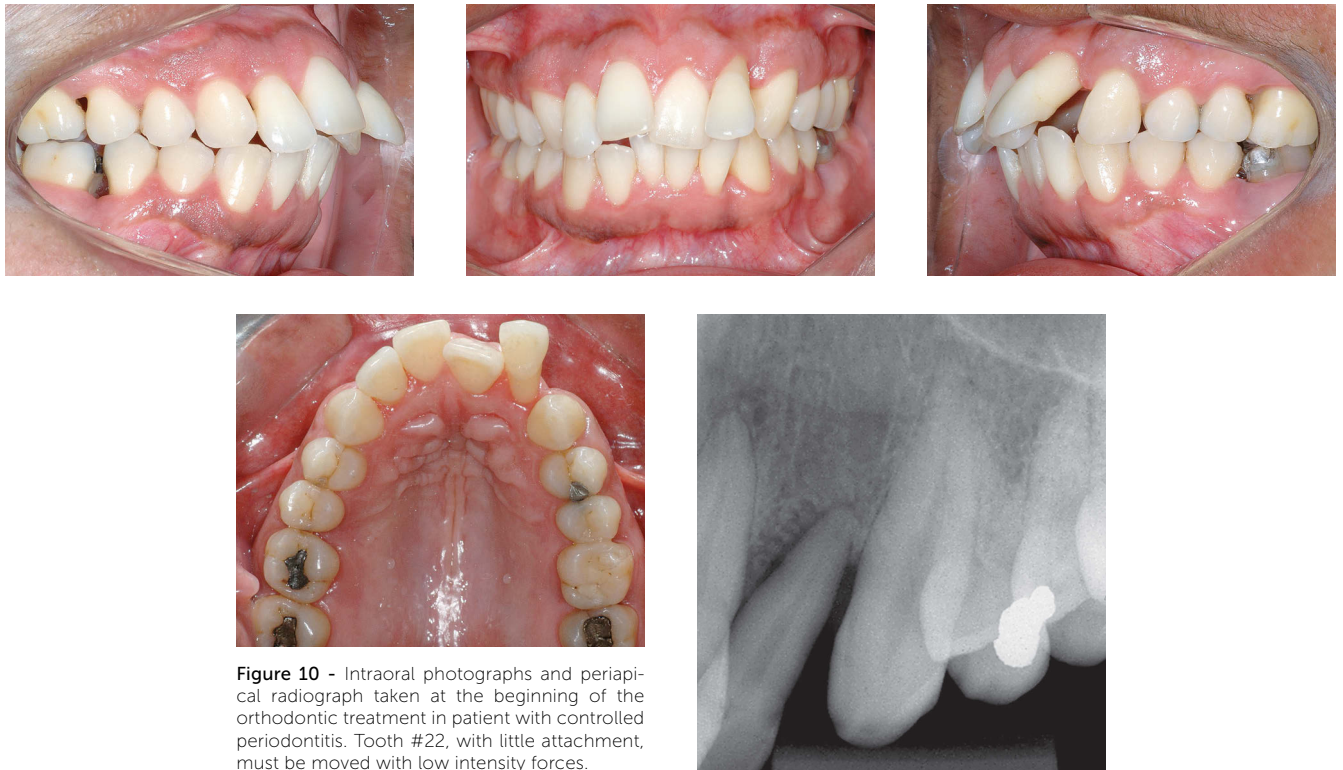


Figure 10 - Intraoral photographs and periapical radiograph taken at the beginning of the orthodontic treatment in patient with controlled periodontitis. Tooth #22, with little attachment, must be moved with low intensity forces.

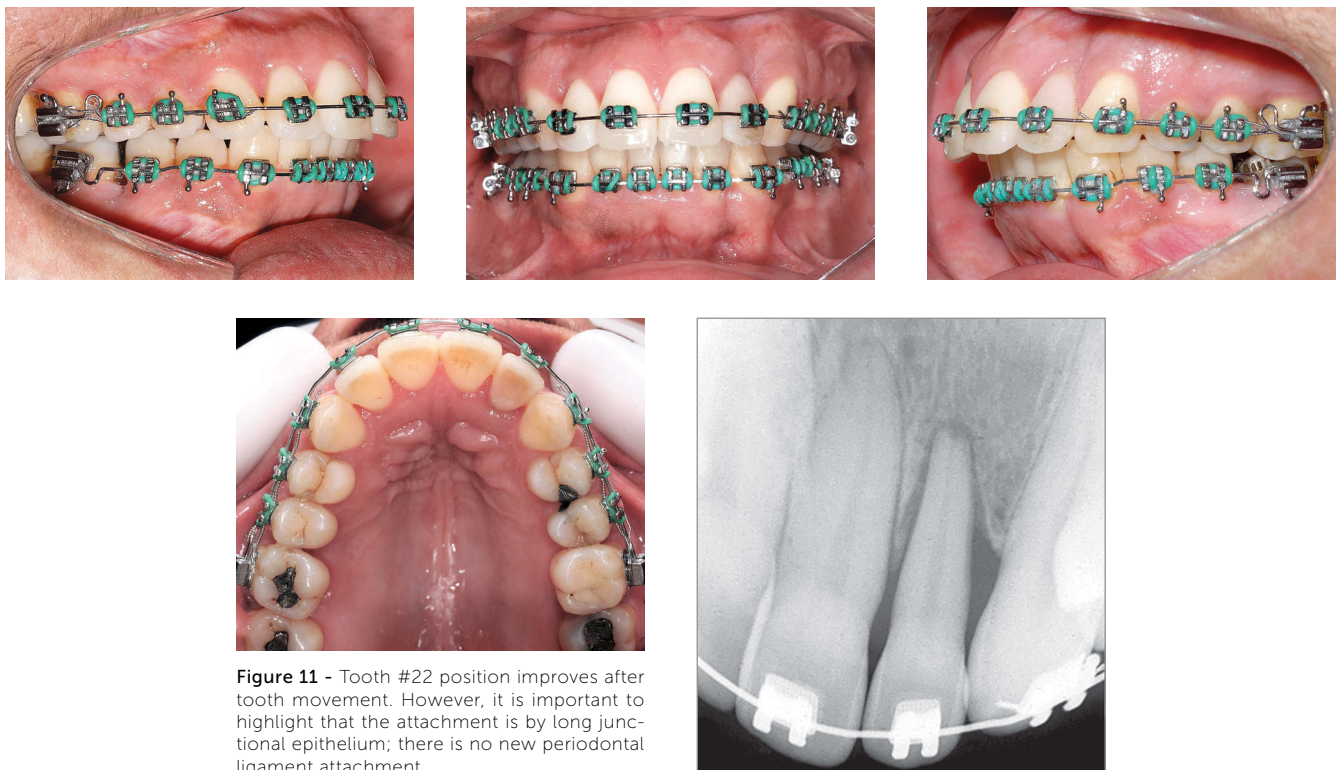


Figure 11 - Tooth #22 position improves after tooth movement. However, it is important to highlight that the attachment is by long junctional epithelium; there is no new periodontal ligament attachment.

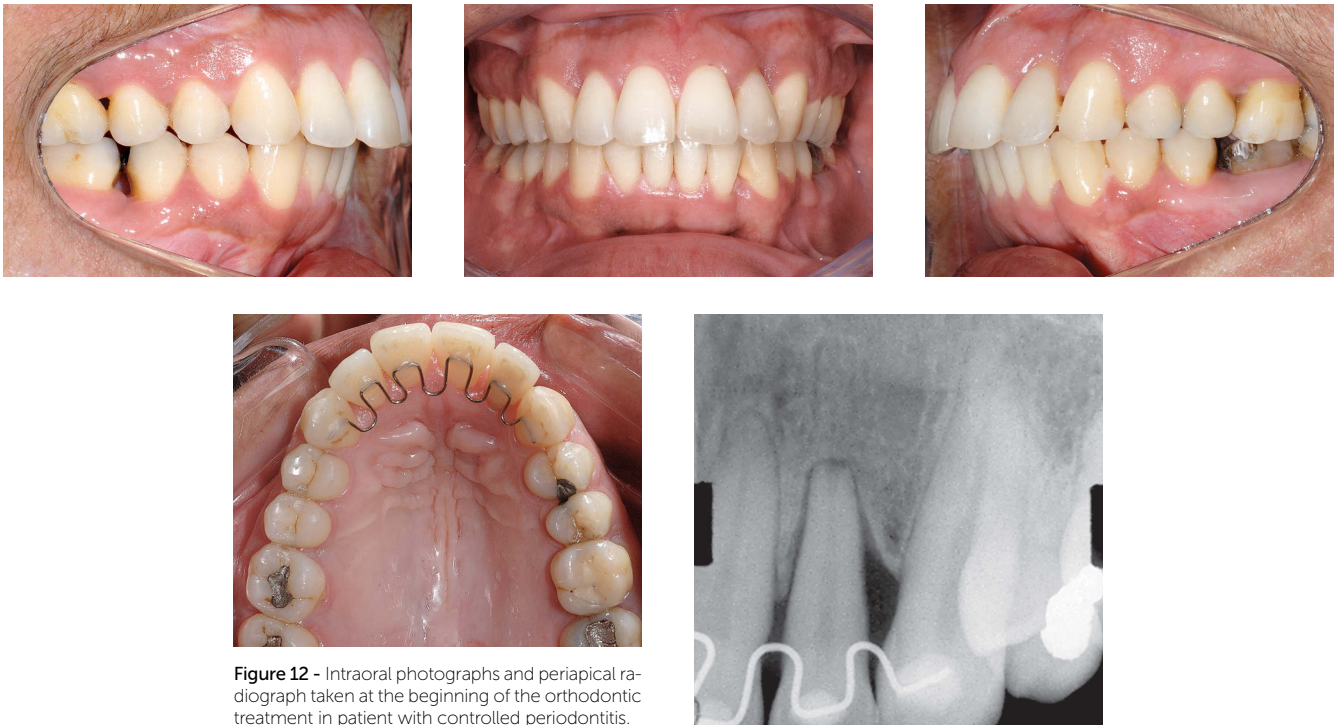


Figure 12 - Intraoral photographs and periapical radiograph taken at the beginning of the orthodontic treatment in patient with controlled periodontitis.

For adult patients, the orthodontic plan with ideal objectives must be reconsidered when the periodontium is compromised, when there is great tooth loss or other limiting conditions. Such patients need an objective and directed treatment in order to have their problem quickly and efficiently solved. Three factors must be taken into account at this moment, namely: 1) Simplification — seek mechanics to favor patient’s oral hygiene. 2) Goals — ponder which would be the best result taking esthetics, stability and functional occlusion into account. Patients usually seek improvements in esthetics, which does not always provide stable results. Therefore, the specialist must discuss with the patient in order to reach a

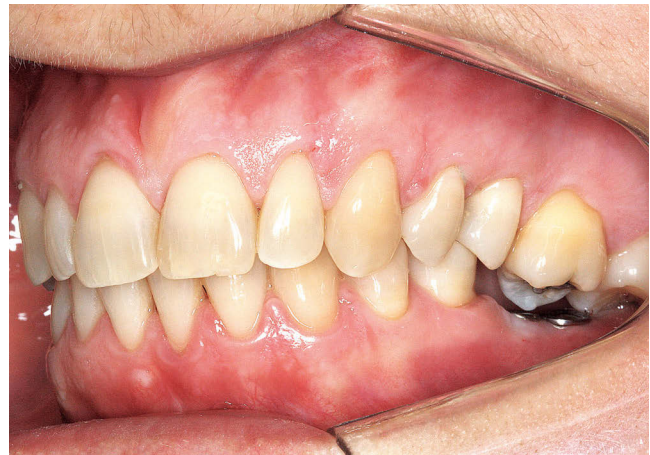

Figure 13 - Example of an objective and directed treatment. Need for intrusion of right mandibular molars to place the crowns over the implants in the antagonist area.

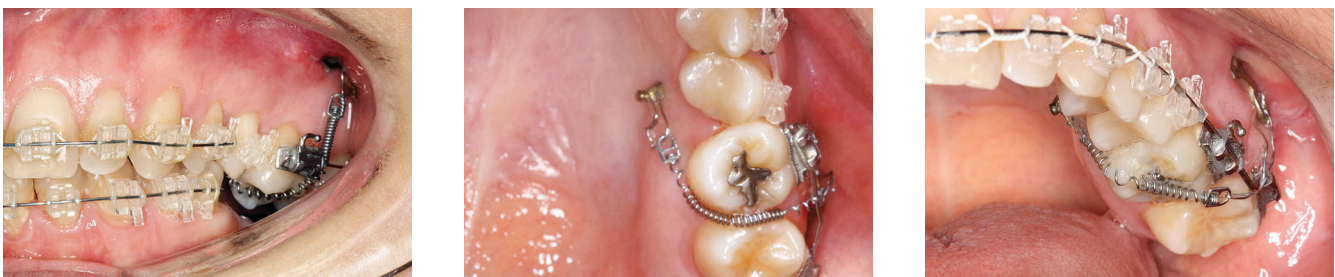

Figure 14 - Placement of miniplate (buccal) and mini-implant (palatal) for anchorage; NiTi spring for intrusion.

mutual agreement on the final outcome. 3) Risk-cost/benefit — talk to the patient about the benefits of the treatment. The costs involve not only the financial value, but also pain, discomfort and tooth mobility. Risks are seen as the possibility of creating problems which did not exist in the first place, such as decalcification, root resorption, mucogingival problems and even tooth loss. At this moment, the orthodontist must also notify the patient about the risks of not taking the treatment.²⁵ Figures 13 to 16 illustrate a case with a realistic objective: the need for intrusion of left mandibular molars for prosthetic restoration of antagonist teeth.

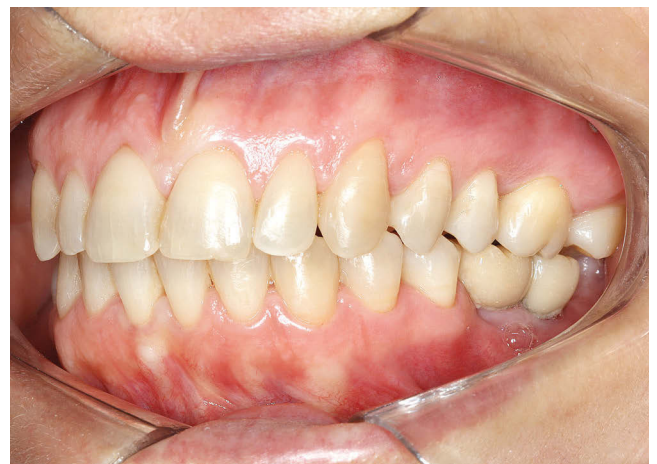

Figure 15 - After intrusion and placement of crowns over the implants.

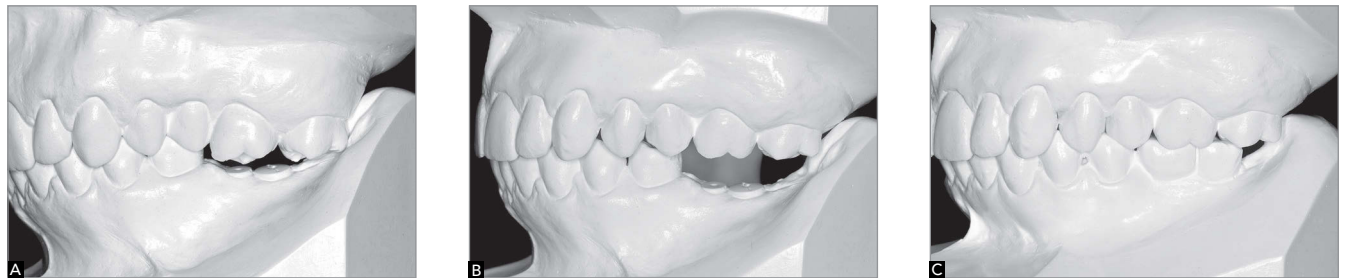

Figure 16 - Study models demonstrating the performed treatment: Initial (A); after intrusion of teeth #26 and #27 (B); crowns placed over implants in the mandibular arch (C).

What is your opinion about early orthosurgical treatment with esthetic and psychosocial purposes? Carlos Alexandre Câmara

When treating Class III, we have good results in patients from 7 to 10 years old with mild to moderate malocclusion and in patients from 17 to 19 years old undergoing the renowned orthosurgical treatment, or in cases with little maxillomandibular discrepancies in which we have the option of orthodontic camouflage.⁶ In clinical practice, I have always noticed a gap concerning the treatment of Class III patients from 12 to 14 years old with dental and facial deformities: it is too late for an interceptive approach and too early for surgery. Awaiting growth to end prior to starting orthosurgical treatment is sometimes extremely difficult

for patients suffering from severe facial deformities. It is difficult to explain to them and their guardians that treatment will happen after 4 or 5 years, only. Therefore, orthosurgical treatment may be performed during the active growth phase, in cases of severe skeletal disharmonies in which patients present significant functional, esthetic or psychosocial issues⁷ — as shown in Figures 17 to 21. To indicate this therapy, orthodontic criteria, such as mild intramaxillary discrepancy and the possibility of preoperative preparation without major dental repositioning, must be met. A second orthosurgical treatment will probably prove necessary after growth has ended. This treatment should not be considered as routine, but rather as a therapeutic option in carefully selected cases.^{7,8}

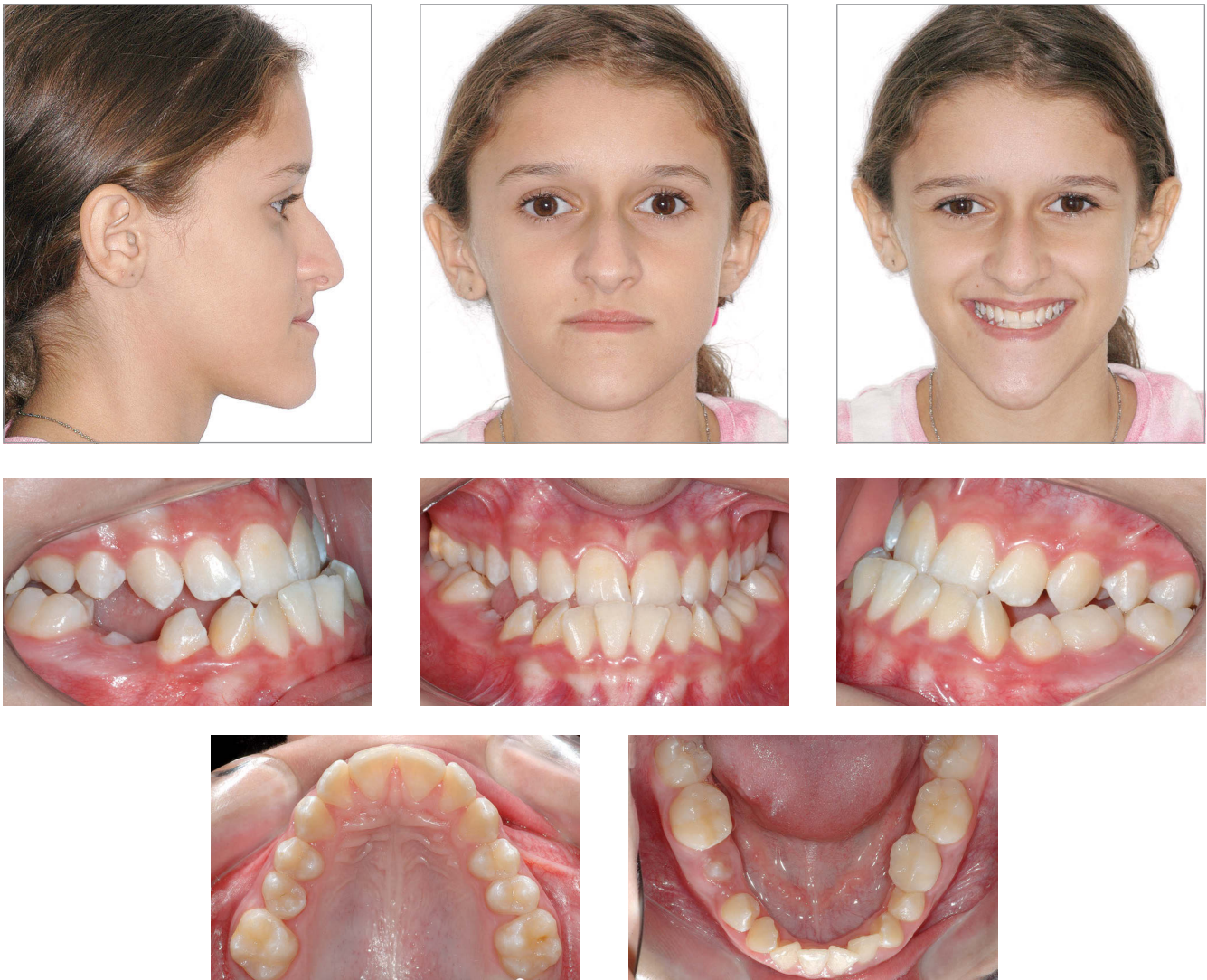

Figure 17 - Facial and intraoral photographs taken at the beginning of the orthodontic treatment in patient aged 13, with Class III dental and skeletal relationship.

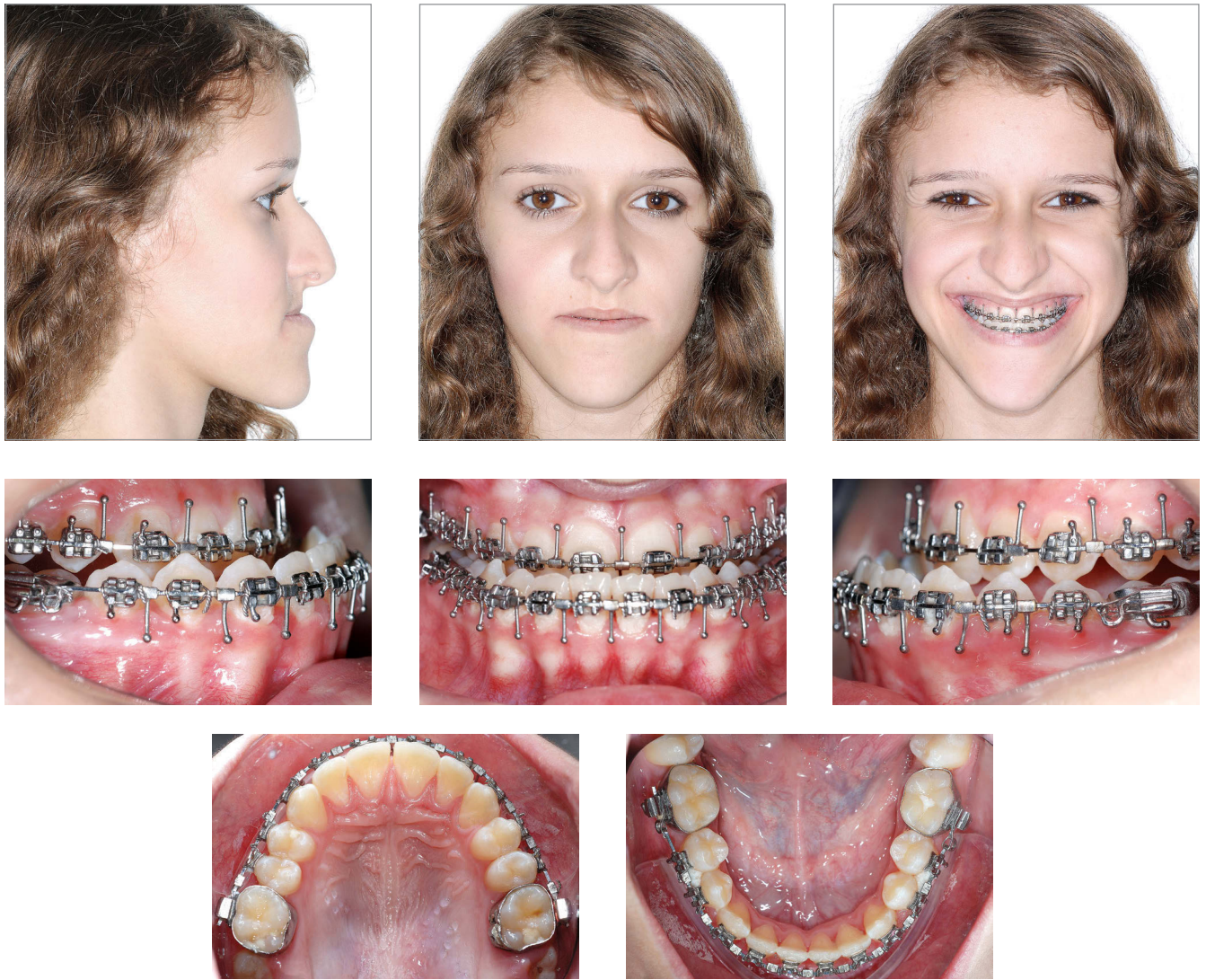

Figure 18 - Facial and intraoral photographs after orthodontic preparation for orthognathic surgery.

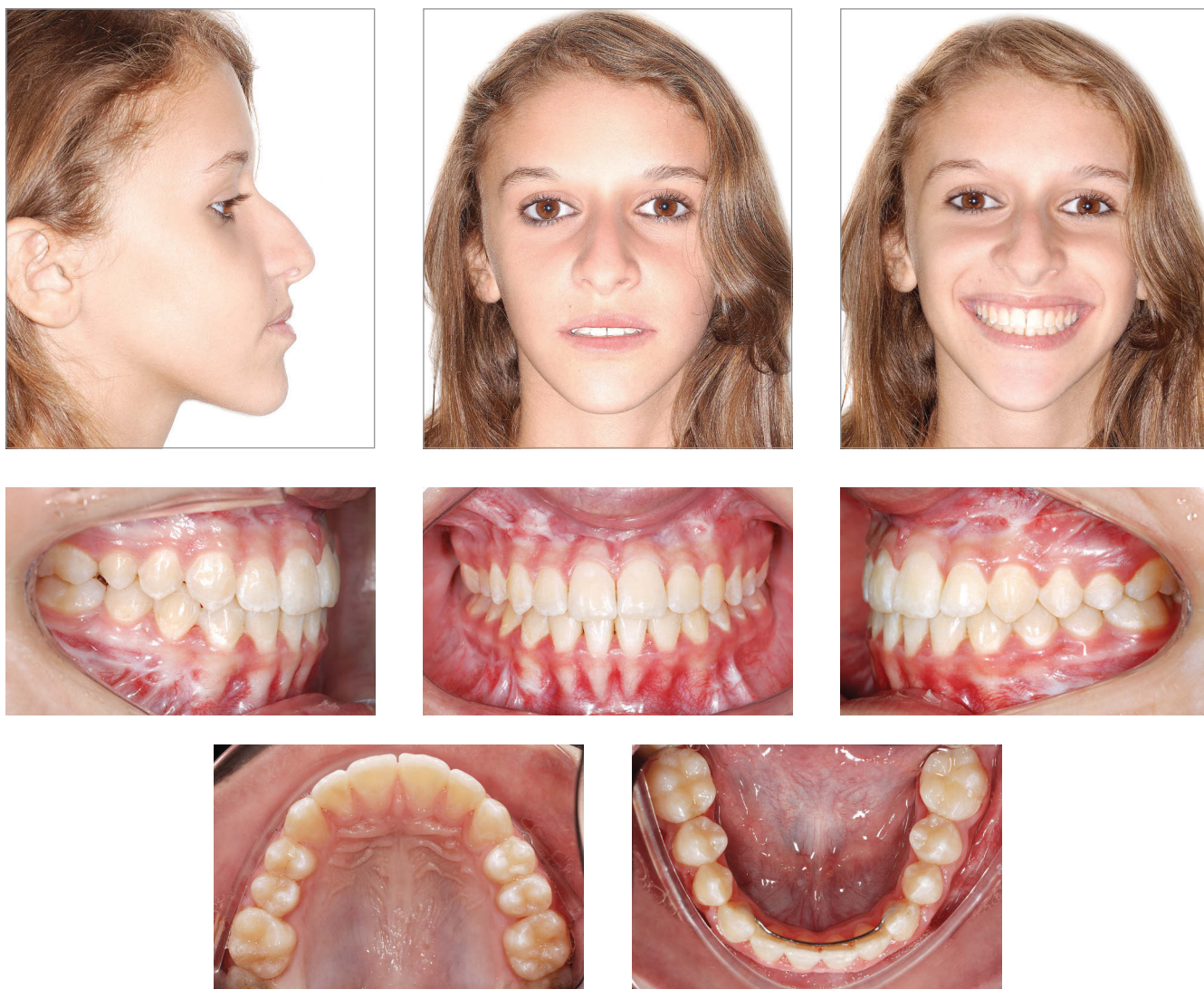

Figure 19 - Facial and intraoral photographs taken at the end of treatment (surgery performed by Dr. Henrique Martins).

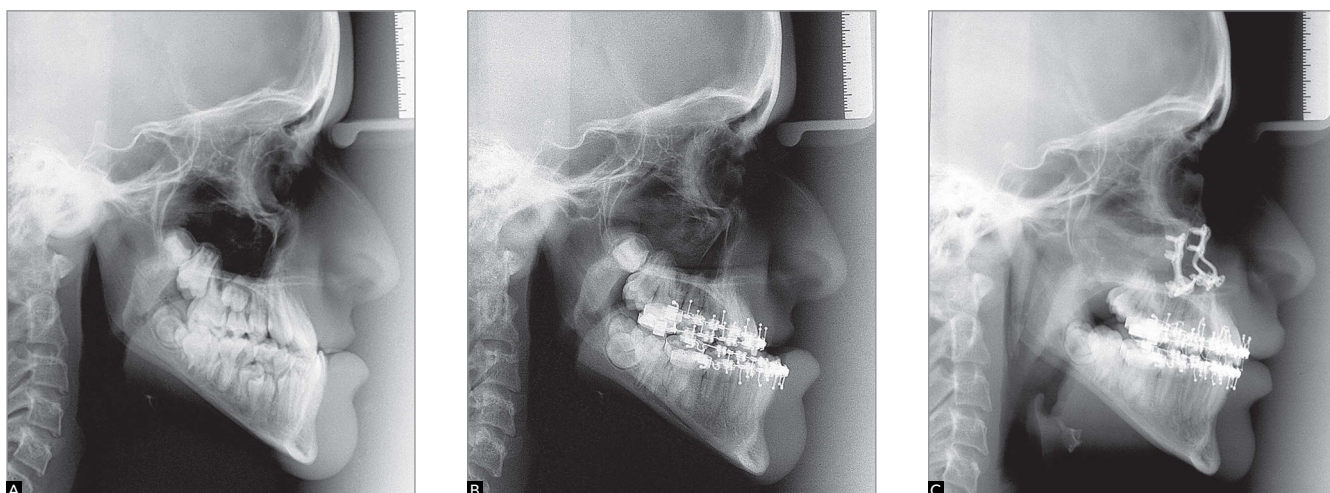


Figure 20 - Cephalometric radiographs at initial (A), presurgical (B) and postsurgical (C) phases.

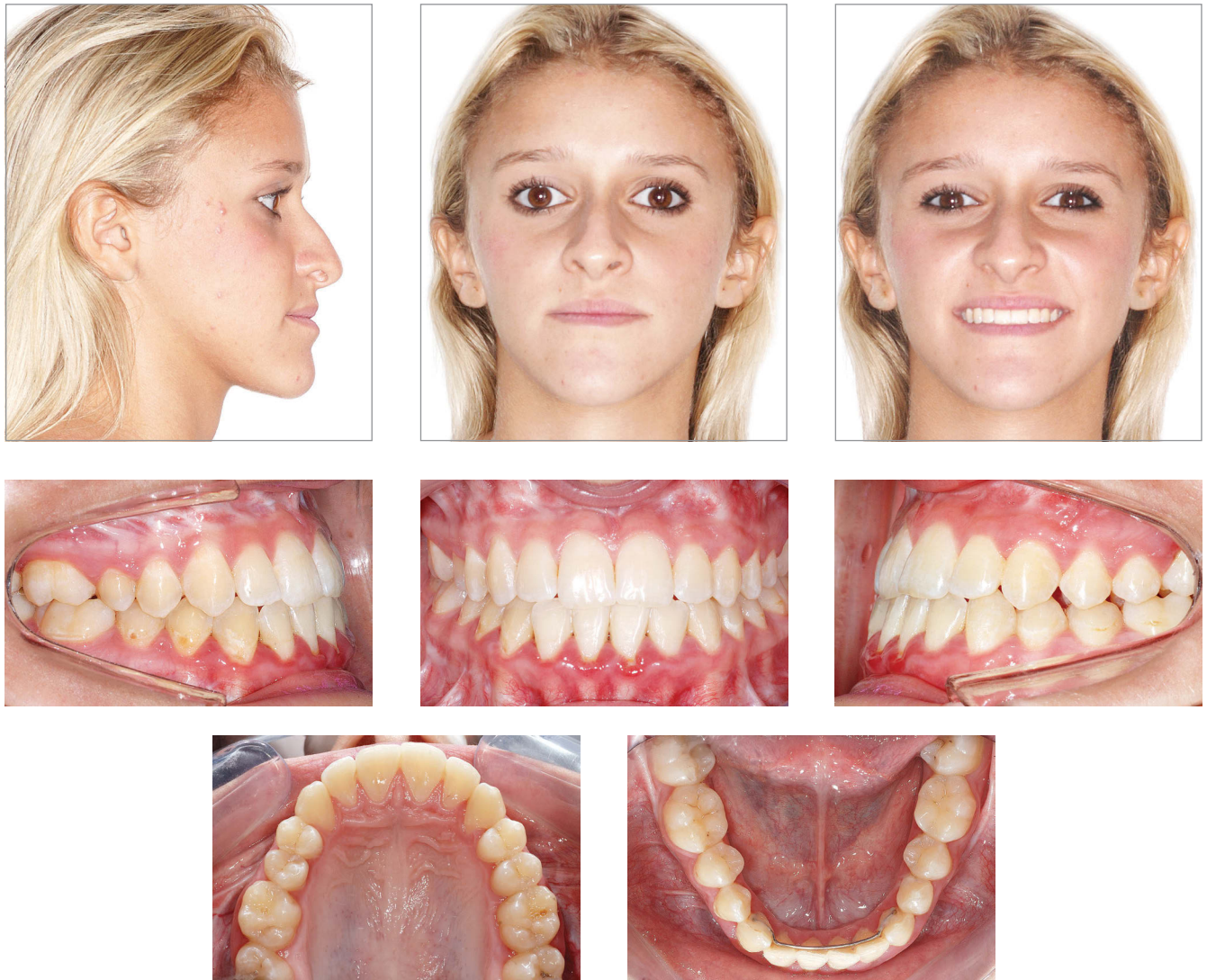

Figure 21 - Facial and intraoral photographs of patient aged 18. Five years after the surgery, we notice good facial esthetics and, again, dental compensation in the anteroinferior segment. Potential need for a new surgery shall be assessed at the age of 21.

Is there a minimum age required to indicate orthognathic surgery for growing patients? If so, what would it be concerning the different types of deformities? [Carlos Jorge Vogel](#)

The minimum age required to indicate orthognathic surgery for growing patients is directly associated with the development of dentition. Therefore, the dental development stage is decisive for surgical procedures involving all kinds of facial deformities in which early surgery is recommended — mandibular hyperplasia or hypoplasia, maxillary hypoplasia or maxillary vertical hyperplasia. The development degree of maxillary canines is important to assess the viability of maxillary surgery with no harm to the dental structure.

Mandibular advancement surgery is recommended after mandibular second molar eruption. However, the ideal would be to have the surgery performed after all permanent teeth have erupted, except for the third molars. We sometimes have to wait to perform the surgery in order to assure a greater dental development. Figures 22 to 26 show an example of a patient treated at age 12 when dental development allows all necessary surgical procedures. It is not advisable to recommend, for this or any other reason, the surgery for a Class III patient aged between 15 or 16. This does not seem to be a sensible approach. It would be correct to wait until the patient turns 18 to perform the Class III traditional orthosurgical treatment.

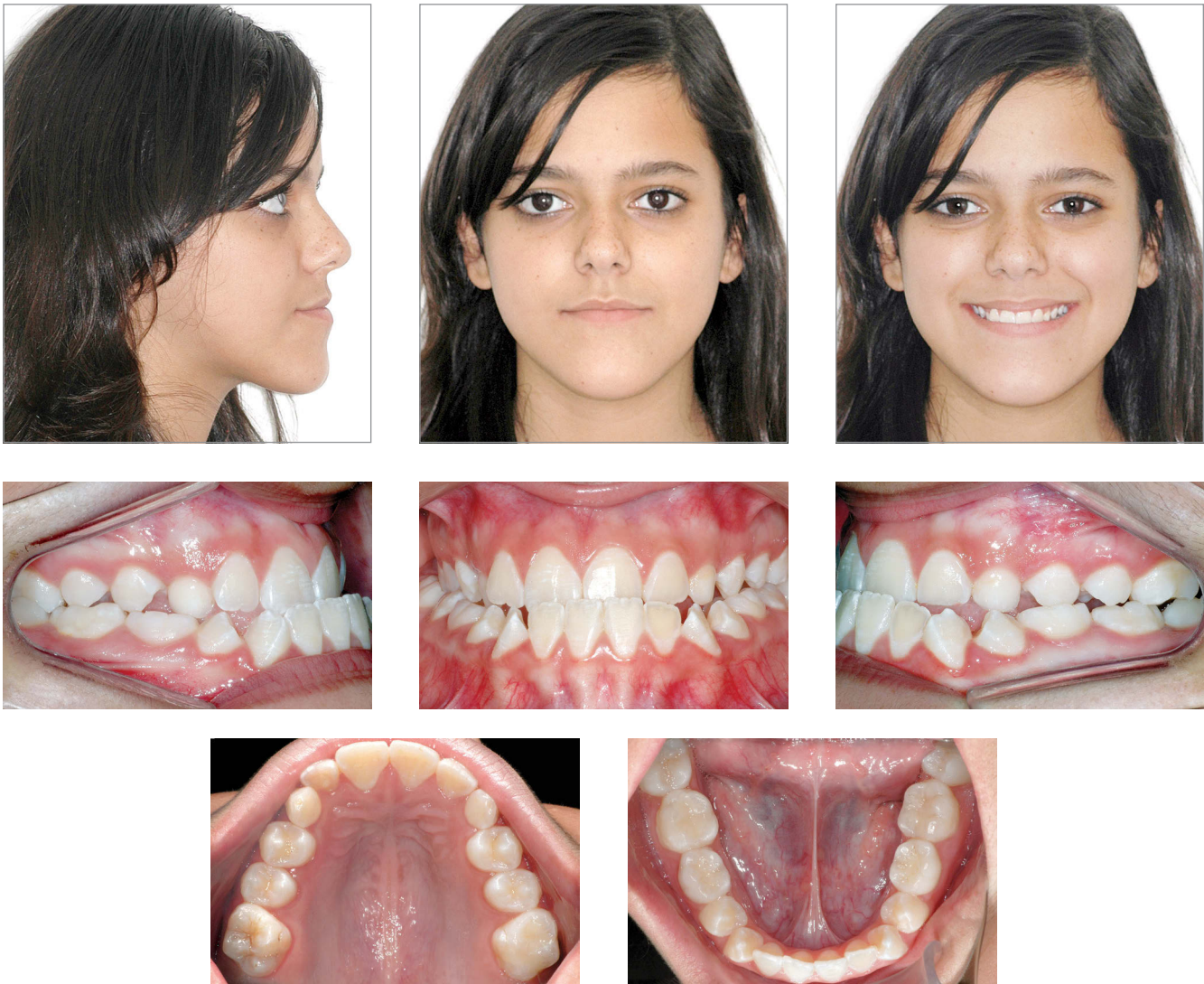

Figure 22 - Facial and intraoral photographs taken at the beginning of the orthodontic treatment in patient aged 12, with Class III dental and skeletal relationship.

Is surgical treatment indicated for mandibular asymmetry cases during growth?

Carlos Jorge Vogel

The mandibular asymmetry cases in which surgery is indicated during growth are, mainly, the condylar hyperplasia ones. In this asymmetric growth process, accentuated by the age of 13, the hypothesis of high condylectomy procedure must be taken into account. Some surgical maneuvers that section the upper part of the mandibular condyle, which grows increasingly, have presented good results for a subsequent balanced mandibular growth process.

Which surgery cases are more likely to succeed: Correction of hypoplasia or hyperplasia?

Carlos Jorge Vogel

The cases of Class III patients with severe anteroposterior deformities are commonly composed of maxillary hypoplasia and mandibular hyperplasia. One may predominate over the other; however, we have always found a combination of both. Maxillary advancement surgeries have presented stable results. In addition, significant mandibular setback surgeries can cause some damage, such as narrowing of the upper airways. Although we started treating cases in which the mandibular setback surgery

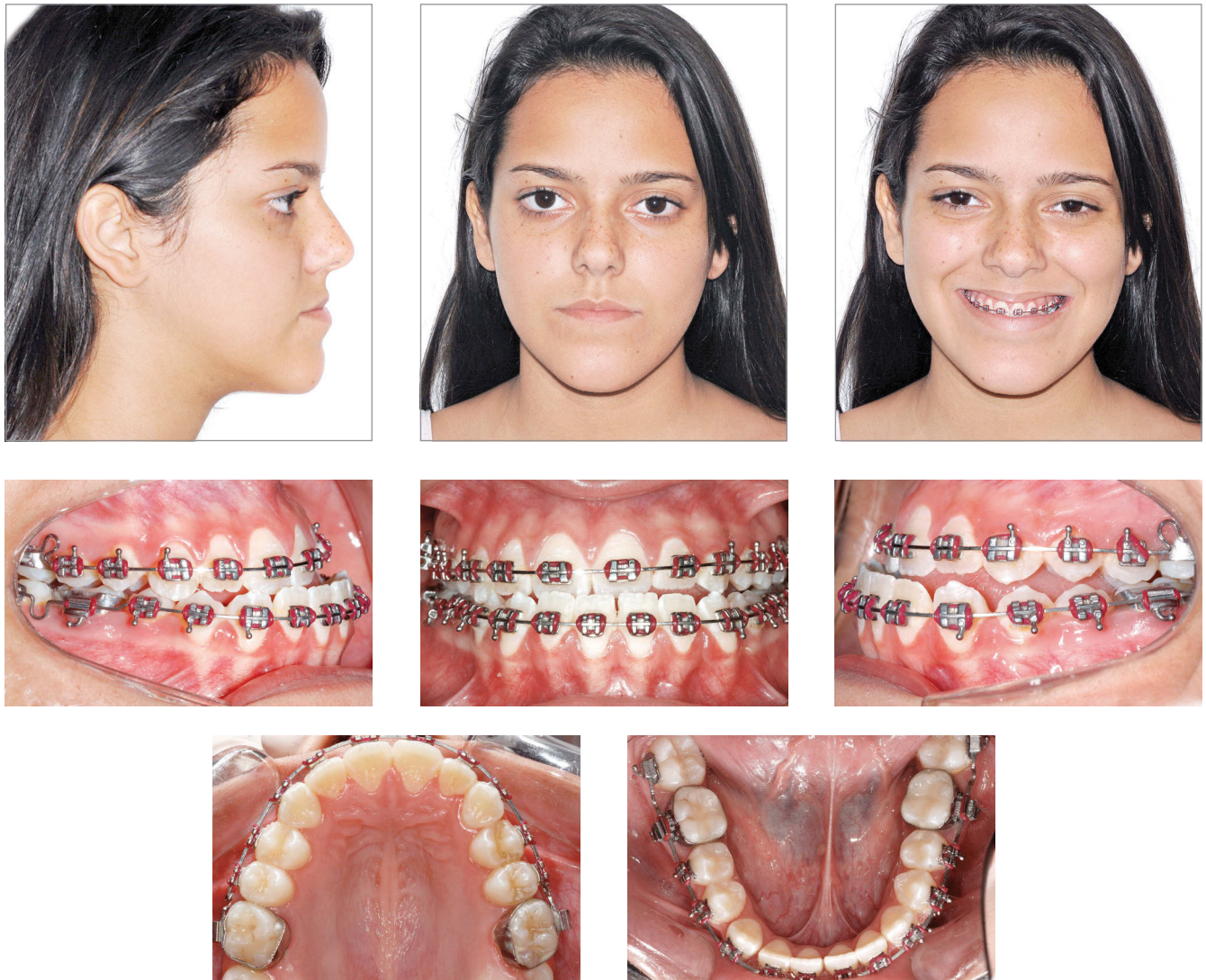

Figure 23 - Facial and intraoral photographs after orthodontic preparation for orthognathic surgery.

alone was considered satisfactory, currently many Class III cases that are treated with an early surgical approach undergo more maxillary advancement surgeries than mandibular setback surgeries.^{7,24}

The Anticipated Benefit orthognathic surgery has presented many advantages, such as the reduction of about 40 to 50% in conventional treatment estimated total time. Based on your experience, do you also see such advantage? If so, what are the causes of this reduction in time?

Sissy Maria Mendes Machado

The expression “Anticipated Benefit” was created by my colleague Dr. Jorge Faber.²⁷ It refers to an approach towards orthosurgical treatment in which there

is an inversion of stages: From Orthodontics prior to Surgery to Surgery prior to Orthodontics.

The “surgery-first” approach refers to a process in which orthognathic surgery is performed prior to orthodontic treatment, while the “Orthodontics-first” approach refers to a process in which orthodontic treatment is implemented prior to orthognathic surgery. Presurgical orthodontic treatment aims at aligning both upper and lower dental arches in order to coordinate their respective skeletal bases, eliminating dental compensations. Orthodontic treatment performed at the presurgical phase is proved very important to yield the best results with the least relapse.^{6,28}

The surgery-first approach treats facial esthetics prior to occlusion, while the traditional approach treats occlu-

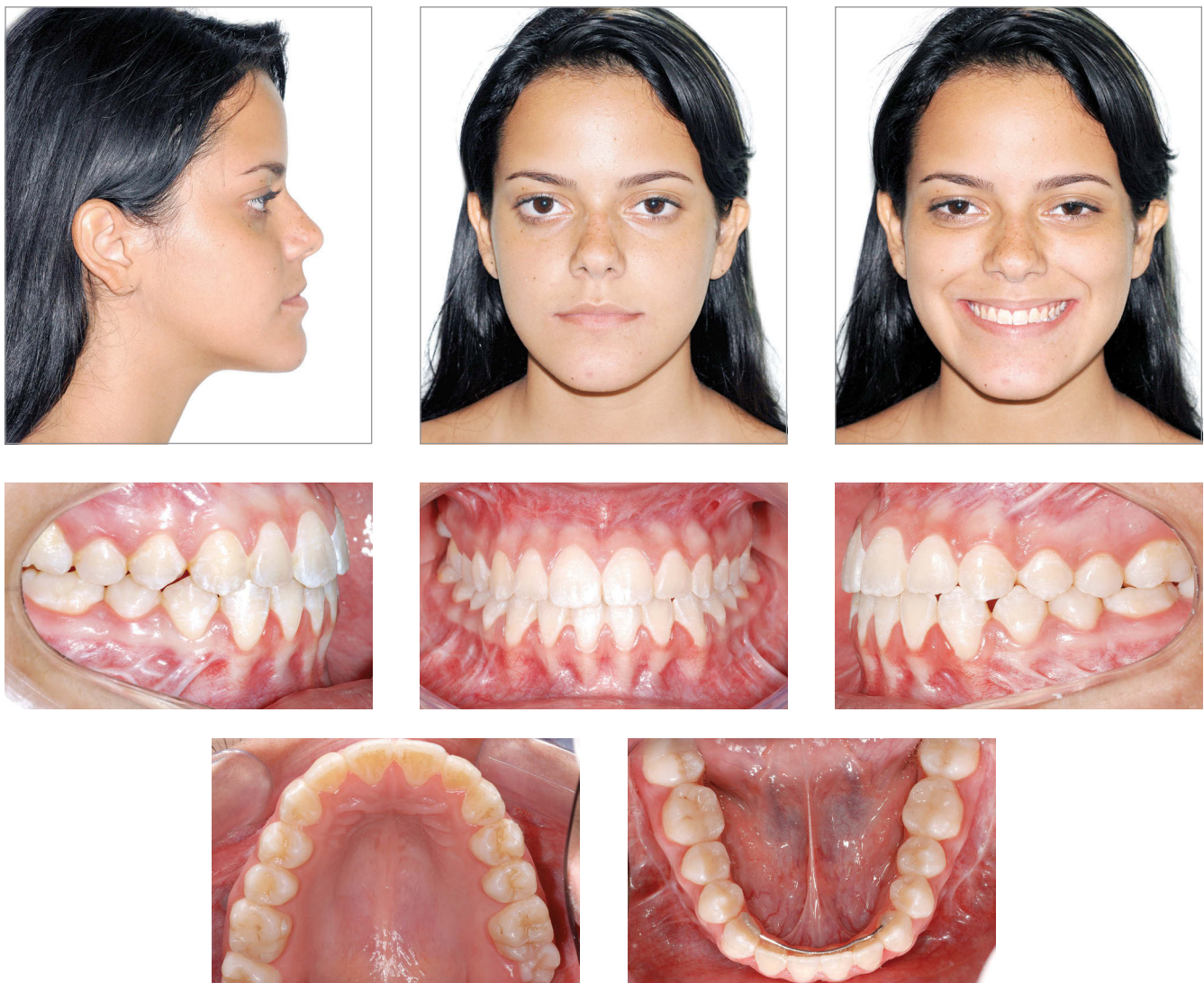

Figure 24 - Facial and intraoral photographs taken at the end of treatment. Combined surgery was performed, with 5 mm of maxillary advancement and 2 mm of mandibular setback (surgery performed by Dr. Henrique Martins).

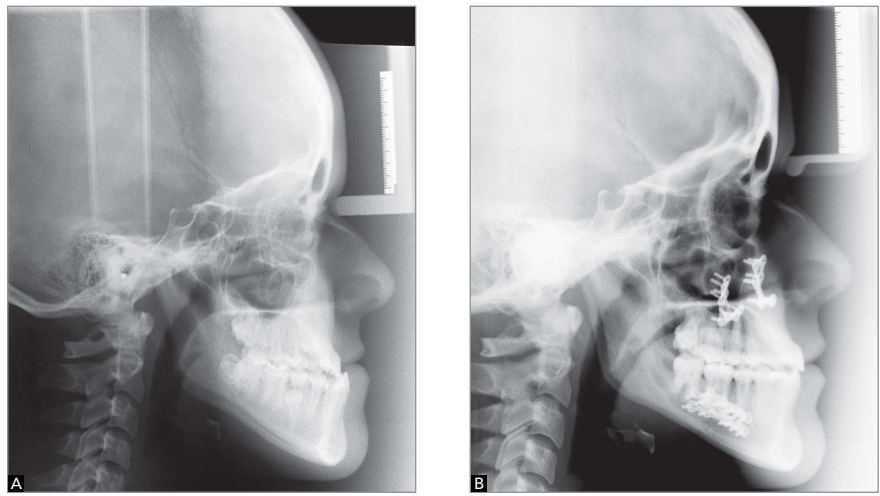


Figure 25 - Cephalometric radiographs at initial (A) and final (B) phases.



Figure 26 - Patient's photographs taken during a photo shoot, demonstrating patient's great self-esteem by the end of adolescence.

sion prior to facial esthetics. The surgery-first approach solves, at the same time, skeletal problems despite occasional dental compensations, and a transitional occlusion is corrected after surgery. The surgery-first approach is recommended for cases with no need of significant decompensation or presurgical orthodontic alignment. Such cases include: 1) properly aligned or slightly crowded teeth; 2) mild curve of Spee and 3) incisor inclination ranging from normal to slightly buccal or retroclined.²⁸

The main reported advantages are: 1) improvement in patient's chief complaint (dental function) and facial esthetics right at the beginning of treatment; 2) reduction in treatment total time, depending on the complexity of the orthodontic treatment; 3) reduction in complexity and duration of orthodontic treatment due to accelerated orthodontic tooth movement at the presurgical phase.²⁸

Answering your question, we presume that reduction in total treatment time can be associated with recommending the surgery-first approach for less complex cases. When comparing the average total time of the surgery-first approach with the average total time of the traditional approach, which includes all types of orthosurgical treatments, we found that the average time for the former is shorter.

However, we should also pay attention to the fact that tooth movement was faster immediately after surgery. An increase in osteoclastic activity and metabolic changes in the dentoalveolar region, with higher expression of bone activity markers — such as alkaline phosphatase (ALP) and C-terminal telopeptide (CTX-1) — are valid reasons for such accelerated bone remodeling.²⁹ It is as if orthognathic surgery worked as the injury caused by the selective alveolar corticotomy. This is an interesting finding which requires further research.

During the ABOR (Brazilian Association of Orthodontics and Facial Orthopedics) congress, held in the city of Belo Horizonte/MG, the Brazilian Board of Orthodontics and Dentofacial Orthopedics (BBO) promoted the pilot project for the certification process of recent graduates and students in the last year of the post-graduation course in Orthodontics. What are your expectations towards those participating in this activity? What are the plans for the future?

Carlos Jorge Vogel

The participants in this activity should follow criteria such as: 1) minimum 12-month graduate from a post-graduation course in Orthodontics with a minimum of 2,000 credit hours; 2) student attending the last year of a post-graduation course in Orthodontics with a minimum of 2,000 credit hours; 3) member of a state-owned entity affiliated with the ABOR.

The chairman of the ABOR invited the coordinators of the courses with a minimum of 2,000 credit hours to take part in this pilot project.

The 47 candidates who applied passed the pilot project examination (equivalent to Phase I). Once they have passed the examination, they have up to 10 years to sit in for Phase II of the certification exam. Should they pass it, they will become a BBO Diplomate, being approved in the “Clinical Excellence” examination.

It is highly likely that a similar exam will be held in Natal/RN (Brazil), during the next ABOR Congress.

As for the BBO, our expectations obligatorily lay on our young colleagues: They shall decide the future of our specialty.

REFERENCES

1. Van der Geld PAAM, Oosterveld P, Van Waas MAJ, Kuijpers-Jagtman AM. Digital videographic measurement of tooth display and lip position in smiling and speech: Reliability and clinical application. *Am J Orthod Dentofacial Orthop.* 2007;131(3):301.e1-8.
2. Ackerman MB, Ackerman JL. Smile analysis and design in the digital era. *J Clin Orthod.* 2002;36(4):221-36.
3. Sarver DM, Ackerman MB. Dynamic smile visualization and quantification: Part 1. Evolution of the concept and dynamic records for smile capture. *Am J Orthod Dentofacial Orthop.* 2003;124(1):4-12.
4. Cosendey VL, Drummond S, Capelli Jr J. Capture, analysis and measurement of images of speech and smile dynamics. *Dental Press J Orthod.* 2012;17(5):151-6.
5. Drummond S. Exposição dos incisivos durante a fala e o sorriso: correlação com a idade e o gênero [dissertação]. Rio de Janeiro (RJ): Universidade do Estado do Rio de Janeiro; 2011.
6. Franco A, Cosendey V, Almeida MA, Capelli Jr J. Tratamento da Classe III: cirurgia ou camuflagem? *Orthod Sci Pract.* 2012;5(19):333-45.
7. Capelli Jr J, Almeida RC. Orthosurgical treatment of patients in the growth period: at what cost? *Dental Press J Orthod.* 2012;17(1):159-77.
8. Wolford LM, Karras SC, Mehra P. Considerations for orthognathic surgery during growth, Part I: Mandibular deformities. *Am J Orthod Dentofacial Orthop.* 2001;119(2):95-101.
9. Câmara CA. Aesthetics in orthodontics: six horizontal smile lines. *Dental Press J Orthod.* 2010;15(1):118-31.
10. Vig G, Brundo C. The kinetics of anterior tooth display. *J Prosthet Dent.* 1978;39(5):502-4.
11. Desai S, Upadhyay M, Nanda R. Dynamic smile analysis: changes with age. *Am J Orthod Dentofacial Orthop.* 2009 ;136(3):310.e1-10; discussion 310-1.
12. Escossia N. Utilização de toxina botulínica do tipo A para minimizar o sorriso gengival. [monografia]. Rio de Janeiro (RJ): Universidade do Estado do Rio de Janeiro; 2012.
13. Consolaro A. Movimentação dentária induzida: biologia aplicada à prática clínica. In: Consolaro A. Reabsorções dentárias nas especialidades clínicas. Maringá: Dental Press; 2005. cap. 11, p. 303-52.
14. Krishnan V, Nair S, Ranjith A, Davidovitch Z. Research in tooth movement biology: the current status. *Semin Orthod.* 2012;18:308-16.
15. Andrade I, Taddei S, Souza P. Inflammation and tooth movement: the role of cytokines, chemokines, and growth factors. *Seminars in Orthod.* 2012;18(4):257-69.
16. Capelli Jr J, Kantarci A, Haffajee A, Teles RP, Fidel R Jr, Figueredo CM. Matrix metalloproteinases and chemokines in the gingival crevicular fluid during orthodontic tooth movement. *Eur J Orthod.* 2011;33(6):705-11.
17. Ulitto VJ. Gingival crevice fluid: An introduction. *Periodontol 2000.* 2003;31:9-11.
18. Capelli Jr J, Fidel Jr Rivaíl, Figueredo CM, Teles RP. Change in the gingival fluid volume during maxillary canine retraction. *Dental Press J Orthod.* 2010;15(2):52-7.
19. Drummond S, Canavaro C, Perinetti G, Teles R, Capelli Jr J. The monitoring of gingival crevicular fluid volume during orthodontic treatment: a longitudinal randomized split-mouth study. *Eur J Orthod.* 2012;34(1):109-13.
20. Almeida RC, Santos D, Teles R, Capelli Jr J. Gingival crevicular fluid volume evaluation in patients with controlled periodontal disease submitted to orthodontic treatment. *J World Fed Orthod.* 2012;22:e 9-12.
21. Perinetti G, Primozic J, Castaldo A, Di Lenarda R, Contardo L. Is gingival crevicular fluid volume sensitive to orthodontic tooth movement? A systematic review of split-mouth longitudinal studies. *Orthod Craniofac Res.* 2013;16(1):1-19.
22. Teles R, Sakellari D, Teles F, Konstantinidis A, Kent R, Socransky S, et al. Relationships among gingival crevicular fluid biomarkers, clinical parameters of periodontal disease, and the subgingival microbiota. *J Periodontol.* 2010;81(1):89-98.
23. Almeida R C. Efeito do movimento dentário nos níveis de metaloproteínas da matriz no fluido gengival de pacientes com periodontite controlada [tese]. Rio de Janeiro (RJ): Universidade do Estado do Rio de Janeiro; 2012.
24. Teixeira A, Medeiros P, Capelli Jr J. Intervenção ortocirúrgica em paciente adolescente com acentuada displasia esquelética de Classe III. *Rev Dental Press Ortod Ortop Facial.* 2007;12(54):55-62.
25. Almeida RC, Martins CC, Capelli Jr J. Inter-relação Periodontia-Ortodontia. In: Ortodontia em um contexto multidisciplinar. Maringá: Dental Press; 2013. cap. 4, p. 85-120.
26. Heasman PA, Millett D, Chapple I L. The periodontium and orthodontics in health and disease. Oxford: Oxford University; 1996. p. 137-59.
27. Faber J. Benefício antecipado: uma nova abordagem para o tratamento com cirurgia ortognática que elimina o preparo ortodôntico convencional. *Dental Press J Orthod.* 2010;15(1):144-57.
28. Liou EJ, Chen PH, Wang YC, Yu CC, Huang CS, Chen YR. Surgery-first accelerated orthognathic surgery: orthodontic guidelines and setup for model surgery. *J Oral Maxillofac Surg.* 2011;69(3):771-80.
29. Liou EJ, Chen PH, Wang YC, Yu CC, Huang CS, Chen YR. Surgery-first accelerated orthognathic surgery: postoperative rapid orthodontic tooth movement. *J Oral Maxillofac Surg.* 2011;69(3):781-5.

Carlos Alexandre Câmara

- » Specialist in Orthodontics, UERJ.
- » Director of the College of Diplomates of the Brazilian Board of Orthodontics and Dentofacial Orthopedics (CDBBO).
- » Peer reviewer, Revista Dental Press de Estética.

Ildu Andrade Jr.

- » MSc and Specialist in Orthodontics, Marquette University, USA.
- » PhD in Cell Biology, UFMG.
- » Professor of the Masters course in Orthodontics, PUC-MG.

Carlos Jorge Vogel

- » PhD in Orthodontics, USP. MSc in Orthodontics, University of Illinois, USA.
- » Member of the Angle Society, USA.
- » Former Director of the Brazilian Board of Orthodontics and Dentofacial Orthopedics (BBO).

Sissy Maria Mendes Machado

- » Specialist in Orthodontics, UERJ.
- » Specialist in Occupational Dentistry, Faculdade São Leopoldo Mandic.
- » MSc in Dentistry, Dental Materials, UFPA.
- » Professor at the Specialization course in Orthodontics at ABO-PA.

Acknowledgments

I would like to thank Dental Press Journal of Orthodontics, represented by its editor-in-chief Dr. David Normando as well as its associate editor Dr. Telma Martins de Araújo, for the invitation. I also would like to thank Dr. Sissy Mendes for organizing this interview, and my colleagues Dr. Carlos Jorge Vogel, Dr. Carlos Alexandre Câmara and Dr. Ildu Andrade Jr for the questions, giving me the opportunity of expressing some of my thoughts. Thank you very much! (Jonas Capelli Jr.)