

Cone beam tomographic study of facial structures characteristics at rest and wide smile, and their correlation with the facial types

Luciana Flaquer Martins¹, Julio Wilson Vigorito²

Objective: To determine the characteristics of facial soft tissues at rest and wide smile, and their possible relation to the facial type.

Methods: We analyzed a sample of forty-eight young female adults, aged between 10, 19 and 40 years old, with a mean age of 30.9 years, who had balanced profile and passive lip seal. Cone beam computed tomographies were performed at rest and wide smile postures on the entire sample which was divided into three groups according to individual facial types. Soft tissue features analysis of the lips, nose, zygoma and chin were done in sagittal, axial and frontal axis tomographic views.

Results: No differences were observed in any of the facial type variables for the static analysis of facial structures at both rest and wide smile postures. Dynamic analysis showed that brachifacial types are more sensitive to movement, presenting greater sagittal lip contraction. However, the lip movement produced by this type of face results in a narrow smile, with smaller tooth exposure area when compared with other facial types.

Conclusion: Findings pointed out that the position of the upper lip should be ahead of the lower lip, and the latter, ahead of the pogonion. It was also found that the facial type does not impact the positioning of these structures. Additionally, the use of cone beam computed tomography may be a valuable method to study craniofacial features.

Keywords: Diagnosis. Cone beam computed tomography. Smile.

» The patient displayed in this article previously approved the use of her facial and intraoral photographs.

¹Visiting professor, Ciodonto College.

²Full professor of Orthodontics, University of São Paulo (USP).

How to cite this article: Martins LF, Vigorito JW. Cone beam tomographic study of facial structures characteristics at rest and wide smile, and their correlation with the facial types. *Dental Press J Orthod.* 2013 Nov-Dec;18(6):38-44.

Submitted: September 15, 2010 - **Revised and accepted:** September 15, 2011

» The authors report no commercial, proprietary or financial interest in the products or companies described in this article.

Contact address: Luciana Flaquer Martins
Rua das Caneleiras, 1074. B. Jardim, Santo André/SP—Brazil— CEP: 09.090-050
E-mail: luflaquer@uol.com.br

INTRODUCTION

One of the first facial esthetic concepts in Orthodontics was conceived by Angle,¹ who related perfect tooth intercuspation to the existing harmony between dental skeletal and facial structures. Case² has stated that even in face of lack of tooth contact and adequate masticatory function cases, patients could occasionally present reasonable facial esthetics. He also observed that all “beautiful” faces exhibited the following features: passive labial seal, good relation between the zygoma and the upper lips, lower lips slightly retracted in relation to the upper lips, and protruded chin.

Diagnosis and orthodontic planning were developed based on cephalometric studies, using lines, planes and angles aiming at quantifying the features of the craniofacial complex in addition to determining normality parameters and goals to be achieved at the end of the orthodontic treatment.³⁻⁶

From the 70's onwards, esthetic parameters assessments have been described as essential to treatment planning, associating Orthodontics to Orthognatic Surgery. Nevertheless, using cephalometric radiographs only is considered insufficient, since soft tissue characteristics would be better visualized by pictures.⁷⁻¹²

The incorporation of cone beam computed tomography (CBCT) techniques to Dentistry allowed comparison between soft and hard tissue structures, without overlaps or magnifications, providing data that correspond to the patient's real measurements.^{14,15}

The possibility of a better appreciation of craniofacial structures improved not only the accuracy in landmarks demarcation, but also the precision of conventional cephalometric analysis^{16,17,18,19,20,21} and it is likely that new assessment techniques might come up and change the current craniofacial analysis paradigms.^{16,17,19}

Our purpose in this paper was to assess the soft tissue features of the face, nose, lips, zygoma and chin, both at rest and during wide smile positions, and their possible relation to the facial type. In order to accomplish that, we used cone beam computed tomographies, once they provide us with a better visualization and a more comprehensive approach for orthodontic diagnosis when compared with traditional methods.¹⁸⁻²¹

MATERIAL AND METHODS

The project for this article was approved by the University of Sao Paulo College of Dentistry Institutional

Review Board, under report number 17/2008. This research assessed 48 female subjects aged between 19.10 and 40 years old, with a mean age of 30.9 years old, caucasian, who had passive lip seal. None of the patients had previously taken part on research activities, facial surgeries (plastic or orthognatic) and had never undergone any facial esthetic intervention.

Facial Index was used to determine each patient's facial type. Patients' faces were photographed with facial soft tissues at rest and with guided NHP,²² according to Vigorito e Martins.²⁶

Each patient's image was inserted into the Radiocef Studio 2 computer software (Radio Memory Ltda, Belo Horizonte — Brazil), by means of which the facial type was obtained according to the anthropometric Facial Index.

Calculations were done using the following formula:

$$N^{\circ}\text{-Me}^{\circ}\times 100 / \text{ZiR}^{\circ}\text{-ZiL}^{\circ}$$

Once Facial Index had been determined, patients were classified as brachifacial, mesofacial or dolico-facial according to the following parameters:^{23,26}

- Brachifacial: between 80.0 and 84.9%.
- Mesofacial: between 85.0 and 89.9%.
- Dolico-facial: between 90.0 and 95.0% or higher.

Following the aforementioned proportions, sample was subdivided into three groups with sixteen subjects each (Brachifacial, Mesofacial and Dolico-facial).

After the facial type had been determined, cone beam computed tomographies were taken by an i-Cat (Imaging Sciences International Hatfield, PA — USA) digital tomography scanner, at two stages: 1- With facial soft tissues at rest; 2- Wide smile.

All measurements were obtained through the i-CAT Vision (Imaging Sciences International Hatfield, PA — USA) computer software at the MPR visualization screen, (multi-plane reconstruction).

For the purpose of this study, true horizontal determination was chosen by means of a single intracranial landmark (Sela), tracing a perpendicular line departing from it, this being the true vertical.²⁴ This technique, together with guided natural head position, is suggested to avoid that possible variations between intracranial planes and lines diverge from the true horizontal line.^{23,24}

For frontal assessment visualization, the 3DVR 5.0 (Imaging Sciences International Hatfield, PA — USA) 3D computer software was used.

Variables used in tomographic soft tissue cephalometric assessment

Axial section (Fig. 1):

1) Zygomatic thickness (Zygoma point; zygomatic soft tissue point, left and right sides); 2) Nose width (left and right alar); 3) Base of the nose width (left to right nasal base)

Sagittal section (Fig. 2):

1) Snv-UI (upper lip position in relation to the vertical subnasal line); 2) Snv-LI (lower lip position in relation to the vertical subnasal line); 3) Snv-Pog' (pogonion position in relation to the vertical subnasal line); 4) H-nose (distance from the tip of the nose to line H); 5) Nose height (distance from pro-nasal to the true horizontal line); 6) Collumela height (distance from collumela to true horizontal); 7) Upper lip height (distance from the stomion to subnasal point); 8) Lower lip height (distance from stomion to mental lip point); 9) Upper lip thickness (distance between vertical prosthion to the tip of the upper lip); 10) Lower lip thickness (distance from

vertical infradentale to the tip of lower lip); 11) Distance between labial apices (distance between upper and lower lip width lines); 12) E-LI (distance from line E and the lower lip).

Frontal view (Figs 4 and 5):

1) Upper lip vermilion height (distance between the most central upper lip point to the stomion, marked over the midline); 2) Lower lip vermilion height (distance between the stomion and the inferior portion of the lower lip, marked over the midline); 3) Distance between right and left labial comissures; 4) Labial height (distance between the upmost part of the upper lip and the lowest part of the lower lip, marked over the midline); 5) Labial index (proportional distance between comissures and labial height, at rest); 6) Smile index (proportional distance between the comissures and labial height, at wide smile); 7) Teeth exposure area.

STATISTICAL METHOD

Facial structures movements were calculated for each patient by subtracting the value at rest from the

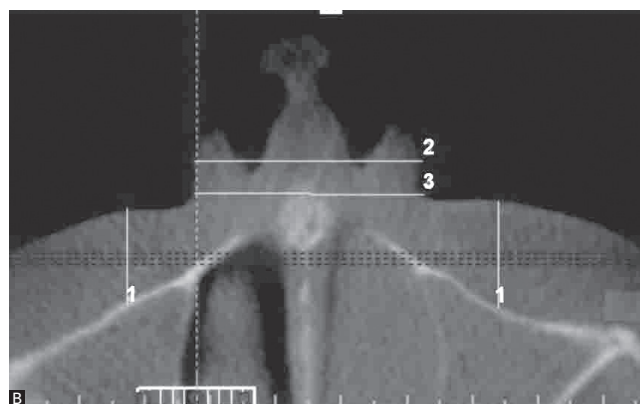
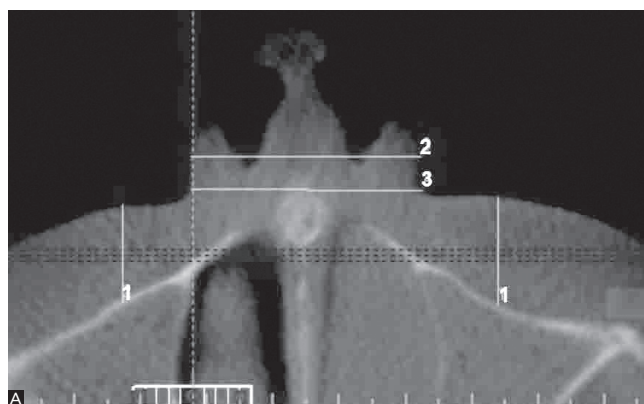


Figure 1 - Variables studied in axial section at rest (A) and wide smile (B).

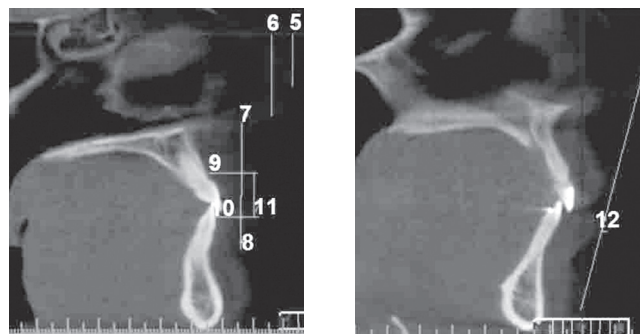
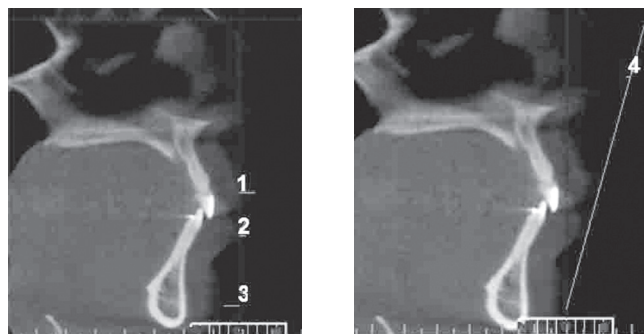


Figure 2 - Variables studied in sagittal section at rest.

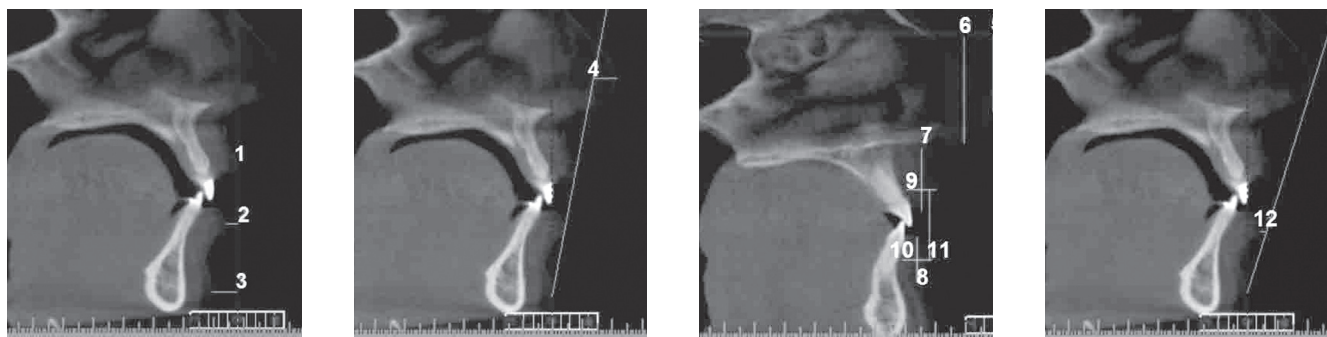


Figure 3 - Variables studied in sagittal section during wide smile.

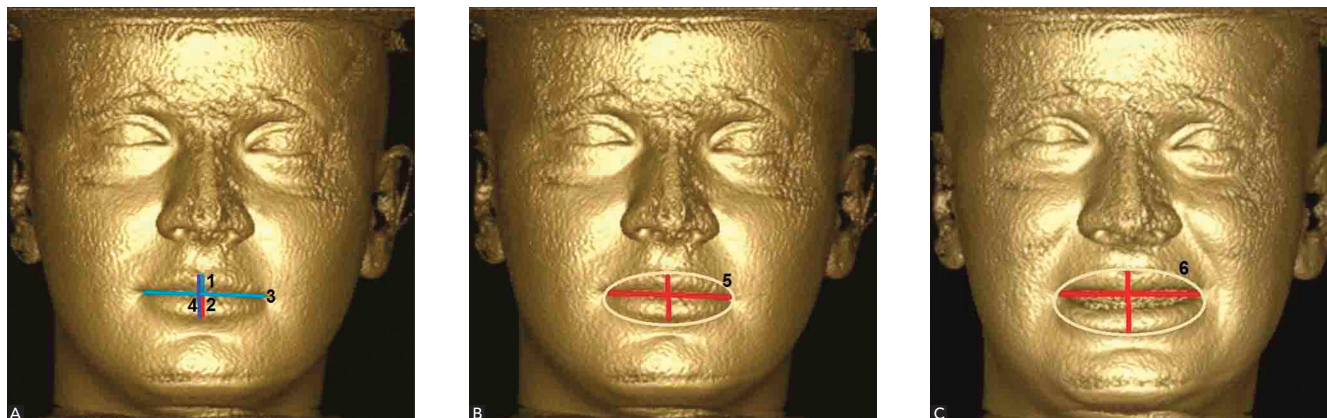


Figure 4 - Variables studied in tridimensional view of the face at rest (A and B) and during wide smile (C).

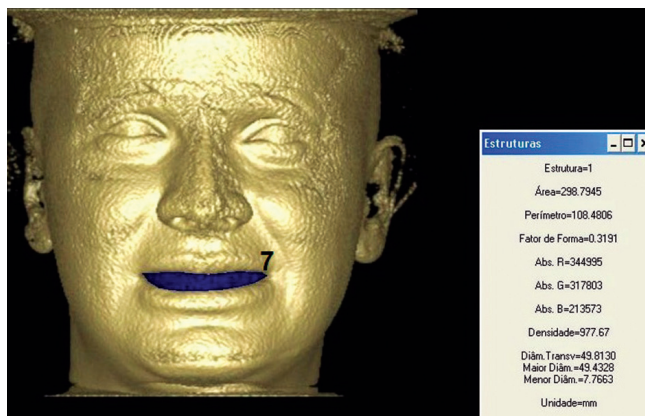


Figure 5 - Tooth exposure area, calculated by tridimensional view of the face during wide smile.

wide smile value. Each facial movement measurement was compared between facial types by means of analysis of variance (one-way ANOVA),²⁵ followed by Bonferroni²⁵ multiple comparisons when the ANOVA presented statistically significant differences while checking which facial types presented distinct facial movement.

In order to assess the relationship between smile index and teeth exposure area, Pearson's correlations were calculated separately for each face type, for the whole sample.

RESULTS

Results are shown in Tables 1 to 8.

Table 1 - ANOVA analysis of variance of the difference between facial types at rest and wide smile, in axial tomographic section.

Variable	Facial type						P
	Brachifacial		Mesofacial		Dolicofacial		
	Mean ± SD	n	Mean ± SD	n	Mean ± SD	n	
Left zygomatic thickness	5.11 ± 2.48	16	3.93 ± 2.28	16	3.11 ± 1.64	16	0.04
Right zygomatic thickness	5.25 ± 2.34	16	3.83 ± 2.22	16	3.17 ± 1.84	16	0.027
Nose width	4.42 ± 3.54	16	3.74 ± 2.83	16	3.12 ± 2.59	16	0.479
Nasal base width	5.24 ± 2.68	16	4.3 ± 1.93	16	4.13 ± 2.12	16	0.336

Table 2 - Bonferroni analysis of measurements presenting statistically significant differences between rest and wide smile, in axial tomographic section.

Variable	Comparison	Mean difference	Standard Error	P	CI (95%)	
					Lower	Upper
Left zygomatic thickness	Brachifacial Mesofacial	1.18	0.76	0.388	-0.72	3.08
	Brachifacial Dolico-facial	2	0.76	0.036	0.1	3.9
	Mesofacial Dolico-facial	0.82	0.76	0.87	-1.08	2.72
Right zygomatic thickness	Brachifacial Mesofacial	1.42	0.76	0.203	-0.47	3.3
	Brachifacial Dolico-facial	2.08	0.76	0.026	0.2	3.97
	Mesofacial Dolico-facial	0.66	0.76	1	-1.22	2.55

Table 3 - ANOVA analysis of variance of the difference between facial types at rest and wide smile, in sagittal tomographic section.

Variable	Facial type						P
	Brachifacial		Mesofacial		Dolico-facial		
	Mean \pm SD	n	Mean \pm SD	n	Mean \pm SD	n	
Nose Height	-0.24 \pm 3.57	16	-0.1 \pm 3.53	16	0.67 \pm 4.25	16	0.767
Collumela Height	-0.23 \pm 3.13	16	-0.01 \pm 4.17	16	0.18 \pm 4.54	16	0.959
Upper Lip Height	-4.78 \pm 2.23	16	-4.51 \pm 1.97	16	-4.84 \pm 1.71	16	0.879
Lower Lip Height	-0.85 \pm 1.64	16	-1.26 \pm 1.99	16	-1.97 \pm 1.98	16	0.245
Upper Lip Thickness	-4.66 \pm 1.37	16	-3.39 \pm 1.58	16	-3.56 \pm 1.21	16	0.027
Lower Lip Thickness	-5.2 \pm 1.74	16	-5.11 \pm 1.58	16	-4.62 \pm 1.66	16	0.57
Distance between Labial Apexes	6.59 \pm 2.4	16	8.33 \pm 2.81	16	7.51 \pm 1.96	16	0.137
Upper Lip Position	-3.2 \pm 1.42	16	-1.32 \pm 1.76	16	-2.23 \pm 1.54	16	0.007
Lower Lip Position	-3.86 \pm 2.23	16	-3.13 \pm 2.03	16	-4.11 \pm 2.24	16	0.417
Pogonion	-0.74 \pm 2.99	16	1.29 \pm 3.28	16	-1.01 \pm 3.02	16	0.083
Line E-Li	-2.89 \pm 4.46	16	-4.28 \pm 2.13	16	-2.94 \pm 1.83	16	0.35
H-Nose	5.96 \pm 1.93	16	5.87 \pm 2.8	16	4.13 \pm 5.86	16	0.335

Table 4 - Bonferroni analysis of measurements presenting statistically significant differences between rest and wide smile, in sagittal section.

Variable	Comparison	Mean difference	Standard Error	p	CI (95%)	
					Lower	Upper
Upper Lip Thickness	Brachifacial Mesofacial	-1.27	0.49	0.04	-2.49	-0.04
	Brachifacial Dolico-facial	-1.11	0.49	0.089	-2.33	0.12
	Mesofacial Dolico-facial	0.16	0.49	1	-1.06	1.39
Upper Lip Position	Brachifacial Mesofacial	-1.87	0.56	0.005	-3.26	-0.48
	Brachifacial Dolico-facial	-0.96	0.56	0.274	-2.35	0.43
	Mesofacial Dolico-facial	0.91	0.56	0.335	-0.48	2.3

Table 5 - ANOVA analysis of variance of the difference between facial types at rest and wide smile, in frontal view.

Variable	Facial type						p
	Brachifacial		Mesofacial		Dolico-facial		
	Mean \pm SD	n	Mean \pm SD	n	Mean \pm SD	n	
Distance between commissures	12.37 \pm 5.75	16	9.6 \pm 4.04	16	9.6 \pm 4.85	16	0.197
Labial Height	5.75 \pm 3.32	16	7.09 \pm 3.3	16	7.77 \pm 2.88	16	0.198
Upper lip Vermilion Height	-1.29 \pm 1.21	16	-1.25 \pm 0.99	16	0.09 \pm 0.93	16	0.001
Lower lip Vermilion Height	-0.81 \pm 1.04	16	-0.93 \pm 0.75	16	-0.37 \pm 0.43	16	0.113
Labial/Smile Index	-0.02 \pm 0.42	16	-0.25 \pm 0.25	16	-0.27 \pm 0.26	16	0.059

Table 6 - Bonferroni analysis of upper lip vermilion height presenting statistically significant differences between facial types at rest and wide smile, in frontal view.

Variable	Comparison		Mean difference	Standard Error	p	CI (95%)	
						Lower	Upper
Upper lip vermilion Height	Brachifacial	Mesofacial	-0.04	0.37	1	-0.96	0.89
	Brachifacial	Dolicofacial	-1.38	0.37	0.002	-2.3	-0.45
	Mesofacial	Dolicofacial	-1.34	0.37	0.002	-2.26	-0.42

Table 7 - ANOVA analysis of variance of teeth exposure area between different facial types, in frontal view.

Variable	Facial type						p
	Brachifacial		Mesofacial		Dolicofacial		
	Mean ± SD	n	Mean ± SD	n	Mean ± SD	n	
Teeth exposure area	288.7 ± 158.4	16	435.04 ± 101.38	16	431.9 ± 102.14	16	0.002

Table 8 - Bonferroni analysis of teeth exposure area that presented statistically significant difference between facial types at rest and wide smile, in frontal view.

Variable	Comparison		Average Difference	Standard Error	p	IC (95%)	
						Lower	Upper
Teeth exposure area	Brachifacial	Mesofacial	-146.37	43.69	0.005	-255.01	-37.73
	Brachifacial	Dolicofacial	-143.21	43.69	0.006	-251.85	-34.57
	Mesofacial	Dolicofacial	3.16	43.69	1	-105.48	111.8

DISCUSSION

Considering the fact that the methodology applied to assess facial soft tissues is considerably different from the methodologies described in the literature, the discussion of this paper is restricted to a description of the findings, supplying data so that further researches may be developed and compared to the present one.

For the study of axial section tomographic images, for both rest and wide smile positions, measurements presented no statistically significant difference between the three facial types.

In the dynamic assessment of these structures, determined by the axial section, it was verified that neither the nose width nor the nose base width suffered any changes in different facial types. On the other hand, soft tissues thickness around the zygomatic structures was influenced by wide smile position when comparing different facial types, suggesting that brachifacial subjects present greater muscle movement, translated by increased thickness around the zygoma if compared with dolico-facial subjects (Tables 1 and 2).

When comparing all variables assessed by the sagittal section, both at rest and wide smile, no statistically significant differences were found between facial types.

However, it was found that at both rest and wide smile, upper lip, lower lip and pogonion positions remained invariable: the lower lip with discrete retrusion

if compared with the upper lip, and the pogonion slightly retruded if compared with the lower lip, as reported by the literature.^{2,4,5,8,24}

Except for the tip of the nose, the nasal collumela and the pogonion, dynamic assessment revealed that height and width of both upper and lower lips as well as the esthetic positioning of these structures, presented significant difference between the two phases (Table 3). Except for upper lip thickness and positioning, which tend to thin out as the smile expands in brachifacial subjects, other measurements did not particularize any facial type.

In frontal view, at rest and wide smile, lips and their features were analyzed and no statistical difference was found between measurements and the facial types.

Dynamic assessment of different variables in frontal view revealed a peculiar behavior with regard to the facial types, as follows:

» Brachifacial, the distance between lip commissures and lip height presented significant alteration. Lower lip vermilion height decreased due to vertical muscle contraction (Table 4).

» Mesofacial, all variables studied revealed significant alteration (Table 4).

» Dolico-facial, wide smile measurements were higher than at rest, but the difference between smile and labial indexes pointed out that rest measurements exceeded the wide smile ones. (Table 4).

The dynamic behavior between labial and smile indexes presented a statistical significant difference for mesofacial and dolico-facial types, with labial index exceeding the smile index. These results demonstrate that although muscle movements take place during wide smile, they do not equally involve vertical and horizontal lip distancing, with a larger distance for horizontal distancing if compared with the vertical one.

Bonferroni analysis of upper lip vermilion height (Table 5) revealed that the upper lip vermilion height was greater for brachifacial patients than for dolico-facial ones, and when comparing dolico-facial with mesofacial subjects, this parameter was higher for mesofacial individuals.

On comparing the tooth exposure area variable between facial types, as an attempt to distinguish their features, it was observed that there was a statistical significant difference (Table 6) that, when submitted to Bonferroni analysis (Table 7), demonstrated that brachifacial subjects presented lower values if compared with mesio and dolico-facial ones, with no significant difference between the two latter patterns.

Observation of tooth exposure behavior in comparison with the smile index showed no relation between

those two variables (Table 8). That confirms the fact that the range of lip movement does not impact total tooth exposure.

CONCLUSION

The results obtained from this research led to the conclusion that in balanced faces, the facial type does not distinguish lip, nose, pogonion or zygoma positioning in soft tissues, neither at rest nor at wide smile position.

That reinforces the importance of orthodontic planning that in addition to being based on bone structures relation, facial growth and dental intercuspation, should also be able to assess soft tissue accommodation towards dental and skeletal tissues as well as facial esthetics, always seeking for the balance between these structures as a final goal of the treatment.

The use of cone beam computed tomography may be a great adjuvant in diagnostic studies that attribute equal weight to both hard and soft tissues analysis, since it allows the assessment of lateral, sagittal and coronal views as well as frontal and profile appreciations of the facial soft tissues.

REFERENCES

1. Angle EH. Treatment of malocclusion of the teeth. 7a ed. Philadelphia: SS White; 1907.
2. Case CS. Orthodontic principles of diagnosis and general rules of treatment of all malocclusions. Chicago: CS Case; 1921.
3. Tweed CH. The Frankfort-mandibular plane angle in orthodontic diagnosis, classification, treatment planning, and prognosis. *Am J Orthod Oral Surg.* 1946;32(4):175-230.
4. Downs WB. Analysis of the dentofacial profile. *Angle Orthod.* 1956;26(4):191-212.
5. Holdaway RA. Changes in relationships of points A and B during orthodontic treatment. *Am J Orthod.* 1956;42(3):176-93.
6. Ricketts RM. Planning treatment on the basis of the facial pattern and an estimate of its growth. *Angle Orthod.* 1957;27(1):14-37.
7. Legan HL, Burstone CJ. Soft tissue cephalometric analysis for orthognathic surgery. *J Oral Surg.* 1980;38(10):744-51.
8. Lündstrom A, Forsberg CM, Peck S, McWilliam J. A proportional analysis of the soft tissue facial profile in young adults with normal occlusion. *Angle Orthod.* 1992;62(2):127-33; discussion 144-4.
9. Cox NJ, van der Linden FPGM. Facial harmony. *Am J Orthod Dentofacial Orthop.* 1971;60(2):175-83.
10. Wylie GA, Fish LC, Epker BN. Cephalometrics: a comparison of five analyses currently used in the diagnosis of dentofacial deformities. *Int Adult Orthodon Orthognath Surg.* 1987;2(1):15-36.
11. Jacobson A. Planning for orthognathic surgery-art or science? *Int J Adult Orthod Orthognath Surg.* 1990;5(4):217-24.
12. Matteson SR, Deahl ST, Alder ME, Nummikoski PV. Advanced imaging methods. *Crit Rev Oral Biol Med.* 1996;7(4):346-95.
13. Farman AG, Scarfe WC, Hilgers MJ, Bida O, Moshiri M, Sukovic P. Dentomaxillofacial cone beam CT for orthodontic assessment. *Int Congress Series.* 2005;1281:1187-90.
14. Sukovic P. Cone beam computed tomography in craniofacial imaging. *Orthod Craniofac Res.* 2003;6(1):31-6.
15. Schulze D, Heiland M, Schmelzle R, Rother UJ. Diagnostic possibilities of cone beam computed tomography in facial skeleton. *Int Cong Series.* 2004;1268:1179-83.
16. Halazonetis DJ. From 2-dimensional cephalograms to 3-dimensional computed tomography scans. *Am J Orthod Dentofacial Orthop.* 2005;127(5):627-37.
17. Farman AG, Scarfe WC, Hilgers MJ, Bida O, Moshiri M, Sukovic P. Dentomaxillofacial cone beam CT for orthodontic assessment. *Int Congress Series.* 2005;1281:1187-90.
18. Rino-Neto J, Accorsi MAO, Ribeiro A, Paiva JB, Cavalcanti MGP. Imagens craniofaciais em ortodontia: O estágio atual da documentação ortodôntica tridimensional. *Ortodontia SPO.* 2006;39(2):144-54.
19. Garib DG, Raymundo Jr R, Raymundo MV, Raymundo DV, Ferreira SN. Tomografia computadorizada de feixe cônico (Cone beam): entendendo este novo método de diagnóstico por imagem com promissora aplicabilidade na Ortodontia. *Rev Dental Press Ortod Ortop Facial.* 2007;12(2):139-56.
20. Kumar V, Ludlow JB, Cevidanes LH. Comparison of conventional and cone beam CT synthesized cephalograms. *Dentomaxillofac Radiol.* 2007;36(5):263-9.
21. Ludlow JB, Gubler M, Cevidanes L, Mol A. Precision of cephalometric landmark identification: Cone-beam computed tomography vs conventional cephalometric views. *Am J Orthod Dentofacial Orthop.* 2009;136(3):312.e1-10; discussion 312-3.
22. Paiva JB, Rino-Neto J, Lopes KB. Análise do lábio superior após o tratamento ortodôntico. *Ortodontia.* 2004;37(2):8-13.
23. Daruge E, Zalaff CF. A biometria aplicada na identificação. *RGO.* 1985;33(2):153-5.
24. Lopes KB. Avaliações tegumentares, esqueléticas e dentárias do perfil facial [dissertação]. São Paulo (SP): Universidade de São Paulo; 2004.
25. Neter J, Kutner MH, Nachtsheim CJ, Wasserman W. Applied linear statistical models. Illinois: Richard D Irwing; 1996.
26. Vigorito JW, Martins LF. Análise fotométrica aplicada na determinação do tipo facial. *Dental Press J Orthod.* 2012;17(5):71-5.