

Location of the apical foramen and its relationship with foraminal file size

Ronaldo Araújo **SOUZA**, DDS, MSc, PhD¹
José Antônio Poli de **FIGUEIREDO**, DDS, MSc, PhD²
Suely **COLOMBO**, DDS¹
João da Costa Pinto **DANTAS**, DDS, MSc¹
Maurício **LAGO**, DDS¹
Jesus Djalma **PÉCORÁ**, DDS, MSc, PhD³

ABSTRACT

Aim: This article analyzed the location of the apical foramen and its relationship with foraminal file size in maxillary central incisors. **Methods:** Eighty four human maxillary central incisors were used in this study. K-files of progressively increasing diameters were inserted into the root canal until it got snugly fit and the tip was visible at the apical foramen. The files were removed and teeth were cross-sectioned 10 mm from the root apex. The files were then reinserted, fixed with a cyanoacrylate-based adhesive, and sectioned at the same level as the root. The root apices were examined using a scanning electron microscope set at

140x magnification, the images were captured digitally and the results were subjected to Chi-square test. **Results:** It was observed that 63 (75%) of the apical foramen emerged laterally to the root apex and 21 (25%) coincided with the apex. The results presented statistically significant differences ($\chi^2=22.1$; $p=0.00$). **Conclusions:** Lateral emergence of the apical foramen is more common than coincidence of the foramen with the apex in maxillary central incisors. This anatomical characteristic may have influence on determination of the foraminal file size.

Keywords: Apical patency. Apical foramen. Endodontic instruments.

Souza RA, Figueiredo JAP, Colombo S, Dantas JCP, Lago M, Pécora JD. Location of the apical foramen and its relationship with foraminal file size. *Dental Press Endod.* 2011 apr-june;1(1):64-8.

¹ School of Dentistry, Bahiana School of Medicine and Public Health, Salvador, Bahia, Brazil.

² Pontifical Catholic University of Rio Grande do Sul, Porto Alegre, Rio Grande do Sul, Brazil.

³ School of Dentistry of Ribeirão Preto, University of São Paulo, Ribeirão Preto, São Paulo, Brazil.

Received: January 2011 / Accepted: February 2011

Correspondence address: Ronaldo Araújo Souza
Av. Paulo VI, 2038/504, Ed. Villa Marta, Itaipara, Salvador/BA, Brazil
Zip code: 41.810-001. E-mail: ronaldoasouza@lognet.com.br

Introduction

Correlation between the presence of microorganisms in the cementum portion of root canal and the development of periapical lesions^{2,7,10,13,14} suggests the need for including instrumentation of this segment of the canal during endodontic therapy.¹⁶

Apical patency consists of the passive use of a small size file through the apical constriction without enlarging it³ and it is believed to promote cleaning of cemental canal.^{4,6,19}

According to Souza¹⁶, Hülsmann and Schäfer,⁵ it seems unlikely that the cementum portion of the canal can be cleaned by this procedure alone as it has been suggested by some authors.^{4,6,19} It may be necessary to employ larger instruments, with diameters more compatible with that of the cemental canal, in order to exert some pressure against its walls.¹⁶

Considering that lateral emergence of the apical foramen in relation to the root apex is a common occurrence,^{1,8,9,11,12,17,18} it is possible that the use of larger and less flexible instruments constitutes a challenge for the foraminal file.

The goal of this study was to analyze the lateral opening of the apical foramen and its relationship with the size of the foraminal file in maxillary central incisors.

Material and Methods

Eighty four human maxillary central incisors with complete roots were obtained from the tooth bank at the School of Dentistry of the Bahiana School of Medicine and Public Health. The criteria adopted for selection of the specimens were absence of complex external anatomy, accentuated curvature, incomplete root formation and apical resorption, observed by means of direct examination and periapical radiographs.

After access and preparation of the pulp chamber with a #3 carbide round bur (KG Sorensen, Cotia, Brazil) and Endo-Z bur (Maillefer, Ballaigues, Switzerland), canals were irrigated with 1 ml 2.5% sodium hypochlorite and explored with a #15 K-file (FKG Dentaire, La-Chaux-de-Fonds, Switzerland), inserted until the tip was visible at the apical foramen.

After that, K-files (FKG Dentaire, La-Chaux-de-Fonds, Switzerland) of progressively larger diameters were inserted with gentle watch-winding motion until

binding and the tip was visible at the apical foramen. Size was annotated and the file was removed.

Teeth were cross-sectioned 10 mm from the root apex with a double-face diamond disk (KG Sorensen, Cotia, Brazil) and the files were reintroduced up to the foramen and fixed with cyanoacrylate-based adhesive. After the adhesive was set, the files were sectioned at the same level as the root.

Roots were fixed in stubs and gold sputtered and a Scanning Electron Microscope (SEM) Philips XL-30 (Philips, Eindhoven, Netherland) was used at 140x magnification. The images were digitally captured in order to determine the position of the foramen in relation to the root apex and the results were subjected to Chi-square test at 5% significance for comparison of frequencies.

Results

It was observed that 63 (75%) apical foramen presented lateral emergence in relation to the root apex and 21 (25%) coincided with the apex (Figs 1 and 2). The results presented statistically significant differences ($\chi^2=22.1$; $p=0.00$). Table 1 shows the diameter and frequency of the files that bound at the cemental canal.

Table 1. Distribution, frequency, medium and median values of the files that bound in the cemental canal.

File	Number of canals	$\bar{X} \pm SD$	Median
25	5	37±7.74	35
30	21		
35	21		
40	17		
45	10		
50	7		
55	2		
60	1		

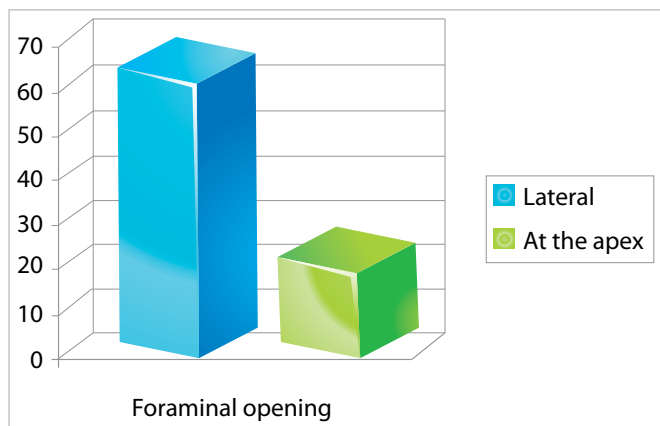


Figure 1. Apical foramen opening in relation to radicular apex.





Figure 2. Location of the apical foramen in relation to the root apex. **A)** Apical foramen emerging laterally. **B)** Apical foramen coinciding with the root apex.

Discussion

The endodontic literature has demonstrated the importance of infection control for therapy success.¹⁰ Mechanical action of the instruments against the root canal walls has been shown as fundamental to reach this aim.

Due to the lack of instruments that adequately fit the anatomy of the entire canal, instrumentation is normally carried out using files of sequentially larger diameters. Considering that mechanical action is an important factor to achieve cleanliness of dentin portion of the root canal, instrumentation of the cementum portion should deserve the same considerations. In other words, the instrument should exert pressure against the cemental canal walls in order to effectively achieve cleanliness.

Therefore, when instrumenting the cementum portion of the canal, using at least one file that binds against its walls is more effective than relying on a smaller instrument. Probably, sequential use of larger diameter instruments would contribute towards greater predictability of the results.^{15,16}

In order to achieve adequate contact between the endodontic files and the foramen opening, it is possible that instruments 3 to 4 sizes larger than the one that initially bound at the foramen should be employed.

In the present study, 63 (75%) of the apical foramen emerged laterally to the root apex, while only 21 (25%) coincided with the apex (Figs 1 and 2). Analysis of the data by the Chi-square test revealed statistically significant differences ($\chi^2=22.1$; $p=0.00$).

It should be kept in mind that in order to penetrate foramen emerging laterally, endodontic files have to be pre-curved. In the present study, we encountered no difficulties when exploring and accessing the apical foramen with a #15 K-file (FKG Dentaire). However, as the diameter of the instruments increased, to identify the instrument that better fit the apical foramen, it became progressively more difficult to penetrate into the foramen.

Once files with larger diameter are less flexible, these instruments may present more challenges for penetration into laterally-emerging foramen, a frequent occurrence in the present study. As observed in Table 1, the mean size of the files that bound at the foramen was 37 ± 7 , which corresponds approximately to a #35 K-file. It may be challenging to instrument the cementum portion of some canals with instruments 3 to 4 sizes greater than a # 35 file.

Knowing that in necrotic teeth this segment of canal is infected, especially when periapical lesions are present, instrumentation of this portion of the canal seems logical. Therefore, this step of treatment

is subjected to the rules of instrumentation, particularly to the recommendation that mechanical action should be ensured by physical contact of the files with the canal walls.

Still, it is important to bear in mind that numbers in endodontics should be considered as references, and should not be viewed as absolute requirements. Regarding instrumentation of the dentinal canal, its anatomy and the characteristics of the instruments employed should guide the principles of root canal instrumentation. Likewise, these same factors should be considered when performing instrumentation of the cementum portion of the canal. In other words, this step of endodontic therapy should not follow rigid pre-established principles, but rather, each clinical situation should be individually examined.

It should be remembered that it was not the aim of this study to analyze other anatomical aspects, such as the diameter of the apical foramen or its distance to the root apex. Our goal was solely to identify the location of the foramen in relation to the root apex.

Conclusion

We concluded that lateral emergence of the apical foramen is more common than foramen emergence at the root apex in maxillary central incisors and that this anatomical characteristic may interfere with foraminal file size determination. Further studies should be carried out in order to analyze the location of the apical foramen and its relationship with foraminal file size in other groups of teeth.

References

1. Arora S, Tewari S. The morphology of the apical foramen in posterior teeth in a North Indian population. *Int Endod J*. 2009 Oct;42(10):930-9.
2. Bergenholtz G, Spangberg L. Controversies in endodontics. *Crit Rev Oral Biol Méd*. 2004 Mar;15(2):99-114.
3. Buchanan LS. Management of the curved root canal. *J Calif Dent Assoc*. 1989 Apr;17(4):18-27.
4. Flanders DH. Endodontic patency. How to get it. How to keep it. Why it is so important. *NY State Dent J*. 2002 68(3):30-2.
5. Hülsmann M, Schäfer E. Apical patency: fact and fiction — a myth or a must? A contribution to the discussion. *Endo (Lond Engl)* 2009;3(4):285-307.
6. Lambrianidis T, Tosounidou E, Tzoanopoulou M. The effect of maintaining apical patency on periapical extrusion. *J Endod*. 2001 Nov;27(11):696-8.
7. Lin LM, Rosenberg PA, Lin J. Do procedural errors cause endodontic treatment failure? *J Am Dent Assoc*. 2005;136(2):187-93.
8. Marroquín BB, El-Sayed MAA, Willershausen-Zonnchen B. Morphology of the physiological foramen: I. Maxillary and mandibular molars. *J Endod*. 2004 May;30(5):321-8.
9. Martos J, Ferrer-Luque CM, González-Rodríguez MP, Castro LAS. Topographical evaluation of the major apical foramen in permanent human teeth. *Int Endod J*. 2009 Apr;42(4):329-34.
10. Nair PNR. On the causes of persistent apical periodontitis: a review. *Int Endod J*. 2006 Apr;39(4):249-81.
11. Ponce EH, Vilar Fernández JA. The cemento-dentino-canal junction, the apical foramen, and the apical constriction: evaluation by optical microscopy. *J Endod*. 2003 Mar;29(3):214-9.
12. Rahimi S, Shahi S, Yavari HR, Reyhani MF, Ebrahimi ME, Rajabi E. A stereomicroscopy study of root apices of human maxillary central incisors and mandibular second premolars in an Iranian population. *J Oral Sci*. 2009;51(3):411-5.
13. Ricucci D, Bergenholtz G. Histologic features of apical periodontitis in human biopsies. *Endod Topics*. 2004;8(1):68-87.
14. Ricucci D, Siqueira JF Jr, Bate AL, Pitt Ford TR. Histologic investigation of root canal-treated teeth with apical periodontitis: a retrospective study from twenty-four patients. *J Endod*. 2009 Apr;35(4):493-502.
15. Souza RA. Clinical and radiographic evaluation of the relation between the apical limit of root canal filling and success in endodontics. Part 1. *Braz Endod J*. 1998 3(1 Pt 1):43-8.
16. Souza RA. The importance of apical patency and cleaning of the apical foramen on root canal preparation. *Braz Dent J*. 2006 17(1):6-9.
17. Vertucci FJ. Root canal morphology and its relationship to endodontic procedures. *Endod Topics*. 2005;10(1):3-29.
18. Williams CB, Joyce AP, Roberts S. A comparison between in vivo radiographic working length determination and measurement after extraction. *J Endod*. 2006 Jul;32(7):624-7.
19. Wu M-K, Dummer PMH, Wesselink PR. Consequences of and strategies to deal with residual post-treatment root canal infection. *Int Endod J*. 2006;39(5):343-56.