

# Rehabilitation with dental implants and fixed prosthesis for esthetic and occlusal correction in partially edentulous patients

Euro Luiz **ELERATI\***

Mauricéa de Paula **ASSIS\*\***

Sérgio Carvalho **COSTA\*\*\***

Wanessa Cristina Filgueiras Batista dos **REIS\*\***

## Abstract

**Introduction:** Rehabilitation of partially edentulous patients using implant-supported fixed prostheses is now a predictable treatment and of proven success in the long term. **Objective:** The purpose of this paper is to outline a systematic approach to prosthetic rehabilitation of partially edentulous patients, exemplified by a clinical case with bone reconstruction and recovery of the vertical dimension of occlusion, occlusal plane leveling and correction of upside down smile. **Methods:** Oral rehabilitation of the patient was performed with dental implants and fixed partial prostheses. **Conclusion:** Treatment was able to restore function, comfort and aesthetics.

**Keywords:** Dental implants. Dental occlusion. Dental prosthesis.

**How to cite this article:** Elerati EL, Assis MP, Costa SC, Reis WCFB. Rehabilitation with dental implants and fixed prosthesis for esthetic and occlusal correction in partially edentulous patients. *Dental Press Implantol.* 2013 Apr-June;7(2):91-8.

» The authors report no commercial, proprietary or financial interest in the products or companies described in this article.

## Contact address

**Euro Luiz Elerati**  
Av. Barão do Rio Branco, 2588  
CEP: 36.016-311 - Juiz de Fora/MG, Brazil  
E-mail: euroelerati@gmail.com

Submitted: September 05, 2011  
Revised and accepted: February 27, 2013

\* MSc in Oral Rehabilitation, UVA. Professor, specialization courses in Implantology and Periodontics/Prosthodontics, Brazilian Association of Dentistry/Juiz de fora.

\*\* Degree in Dentistry, UFJF.

\*\*\* PhD and MSc in Dentistry, USP/Bauru. Associate Professor, Prosthodontics, UFMG.

» Patients displayed in this article previously approved the use of their facial and intraoral photographs.

## Introduction

Dental loss or the use of inadequate prostheses may have a negative impact in quality of life, such as discomfort and psychological inability.<sup>1</sup> Partially edentulous patients usually seek for esthetic and functional rehabilitation through fixed prosthesis, which often requires a multidisciplinary approach.<sup>2</sup> Esthetic rehabilitation with fixed prosthesis entails the replacement and/or restoration of natural teeth with artificial elements fixed to the natural teeth or to osseointegrated implants.<sup>3</sup>

Implant dentistry based on osseointegration is among the most significant advances in dental science in the last 50 years.<sup>4</sup> In fact, Implant dentistry has become a reliable oral rehabilitation technique thanks to this progress and consistency of surgical techniques.<sup>5</sup>

Some patients have insufficient bone volume or bone quality for the successful placement of implants (for instance, after injury or after a long period using removable prosthesis). In order to overcome these obstacles, the residual bone crest can be augmented in width and/or thickness with bone grafts.<sup>6</sup> Bone defects in the anterior maxilla are usually reconstructed with autologous mono-cortical bone blocks, for the subsequent placement of the dental implants.<sup>7</sup> In the posterior maxilla, elevation of maxillary sinus floor was created to increase the required vertical height.<sup>8</sup>

In the rehabilitation of a partially edentulous patient, natural and artificial teeth must coexist in a harmonious way, both functionally and aesthetically. To achieve this result, the clinician must have a thorough understanding of the basic physiological factors that affect patient's occlusion.<sup>9</sup>

When oral rehabilitation is required, occlusal plane orientation must be restored.<sup>10</sup> Among the desirable occlusal characteristics is the incorporation of a physiological

vertical dimension of occlusion (VDO). This favors the achievement of a mutually protected occlusion, so that the transmission of occlusal forces resultant is directed along the long axis of the posterior teeth, with presence of posterior bilateral and simultaneous dental contacts, and adequate vertical dimension, as well as lateral and anterior guidance, in order to protect the rehabilitation.<sup>11</sup> Thus, posterior teeth protect anterior teeth through contacts during centric occlusion, and anterior teeth protect posterior teeth from horizontal forces originated in excursive movements through the anterior guidances. This type of occlusion respects the principles of ideal occlusion, and, therefore, it has been considered the most convenient occlusal scheme for prosthetic rehabilitation.<sup>12</sup>

The present paper describes the rehabilitation of a partially edentulous patient with tooth-implant supported fixed prostheses, using associated procedures to provide satisfactory function and aesthetics.

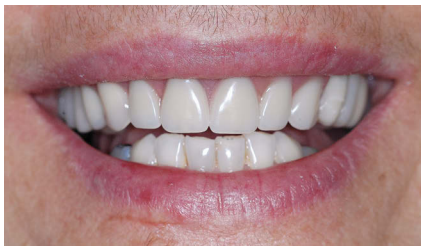## Case report

Female patient, 55 years old, using maxillary removable partial denture (RPD) and mandibular fixed partial denture (FPD), searched our clinic seeking to improve the aesthetic condition by means of fixed prosthesis (Figs 1, 2 and 3). Presented with Kennedy's Class IV partial edentulism in maxillary arch, due to the absence of maxillary anterior teeth and left first premolar — rehabilitated by means of a RPD. In the mandible, partial edentulism was Kennedy's Class III: Second premolars, first and second molars were absent in both sides, with the latter rehabilitated by FPDs. While examining the face and smile, it was observed that the occlusal plane of the maxillary anterior teeth (removable prosthesis) was higher than the plane of maxillary posterior teeth (natural teeth), altering the natural contour of upper teeth, which must match the curvature of the lower lip.<sup>3</sup> There were also changes in the vertical dimension of occlusion, which was measured with a Willis bite gauge,

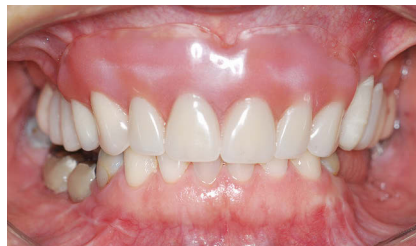according to technique described by Lytle and modified by Tamaki. Vertical dimension at rest was measured, resulting in the value of free working space, which was 4.5 mm, representing a reduced VDO<sup>29</sup> (Figs 4, 5 and 6).

Thus, rehabilitation planning began through confection of dental study models and diagnostic wax-up, with ap-

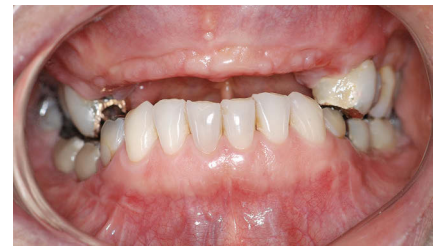propriate parameters of occlusion and occlusal plane (Fig 7). Panoramic radiograph was the first auxiliary resource in planning, giving an estimate of bone height in edentulous areas, which was approximately 4 mm in line 1, as show in Figure 8; 6 mm in line 2; 14.25 mm in line 3; 15 mm in lines 4 and 5; 12 mm in line 6, and between 9 and 11 mm in all the lower lines (Fig 8).



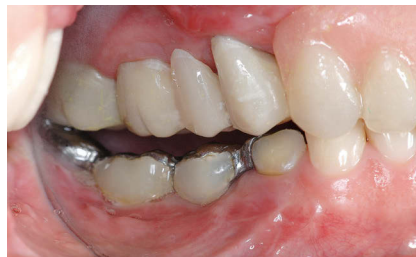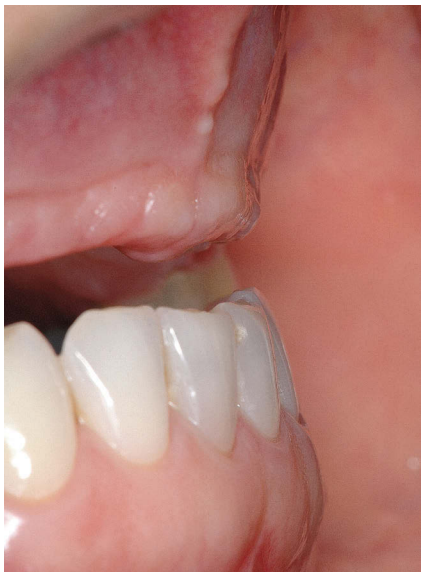**Figure 1** - Initial photograph of the smile.



**Figure 2** - Initial intraoral photograph wearing the prosthesis.

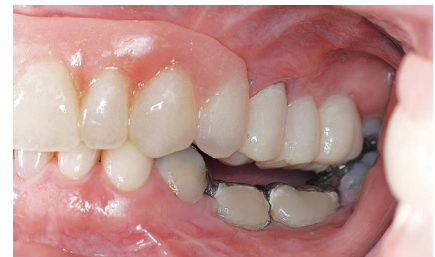

**Figure 3** - Initial intraoral photograph without the prosthesis.

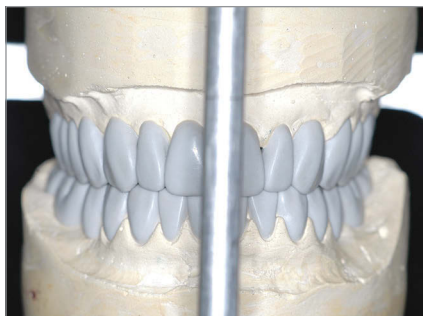

**Figure 4** - Reduced vertical dimension, due to the maxillary bone resorption.

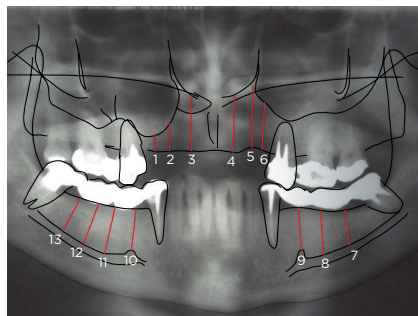
**Figure 5** - Right side intraoral photograph with maxillary provisional prosthesis.



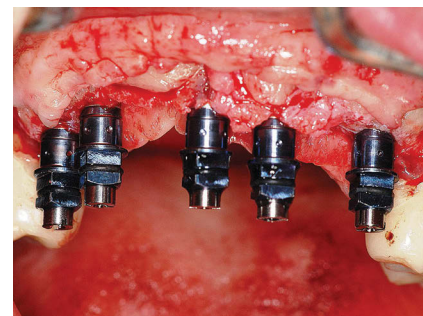
**Figure 6** - Left side intraoral photograph with maxillary provisional prosthesis.



**Figure 7** - Diagnostic wax-up.



**Figure 8** - Initial panoramic radiograph.



**Figure 9** - Maxillary implants in place.

There was no possibility of installing fixed prosthesis in the maxilla without the use of osseointegrated implants, nor appropriate bone thickness for this option. Grafting procedures were planned and executed in hospital setting in a single surgical procedure. Six blocks of autogenous bone gathered from the mandibular ramus, bilaterally on the oblique line region, were fixed in the anterior region of the maxilla (tooth #14 to tooth #23) with screws. Simultaneously, the right maxillary sinus underwent grafting for floor augmentation with lyophilized bovine bone in small granules (Bio-Oss®, Switzerland), associated with approximately 10% of particulate autogenous bone (which remained from the blocks removed for the grafts) and covered with collagen membrane (Surgidry Dental, Belo Horizonte, Brazil). After six months, bone thickness was sufficient for implant placement, at which time they were placed in outpatient surgery (Fig 9).

Maxillary implants had 3.75x15mm in teeth #14, #13, #11 and #21 regions; 4.0x11.5mm in tooth #15 region and 3.75x13mm in tooth #23 region (Conexão Sistemas de Prótese, São Paulo, Brazil). The primary stability, measured by means of the insertion torque, ranged from 50 to 65 N, except for the implant in tooth #15 region, which was 35 N (this implant was lost 40 days after placement). It was used a surgical guide obtained from the model with

diagnostic waxing to place implants in the proper position for prosthetic rehabilitation. The implant-supported metal-ceramic FPD was installed eight months later, and a tooth-borne FPD was placed in tooth #24 to tooth #26 region to solve the edentulous space in the #25 region. On tooth #15 region, where the implant was lost, we chose a cantilever to rehabilitate teeth #14 and #15 because the patient was not receptive to undergo further attempts to implant placement. Besides that, biomechanically, prosthesis length and the size of the other implants would favor occlusal forces distribution.

In the mandibular region, FPDs were inadequate and the incisal curvature of anterior teeth was higher than that of the posterior ones, causing inversion of the ideal occlusal pattern. Anterior teeth were subjected to clinical crown lengthening and occlusal plane leveling by means of stripping with diamond bur at high speed, to obtain the proper height, visualized using a wear guide made from the diagnostic wax-up. Edentulous spaces received implants (Conexão Sistemas de Prótese®, São Paulo/Brazil) with 3.75x13mm (tooth #45 region), 3.75x15mm (tooth #35 region), 5.0x10mm (#37 and #46 region) and 5.0x11.5mm (#36 region) replacing the existing pontics (Figs 10 and 11). Lower implants presented approximately 70 N of primary stability, measured by the installation torque,

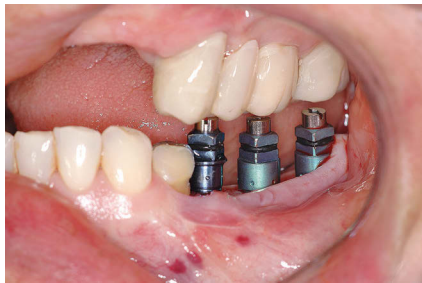allowing the placement of screw-retained temporary crowns immediately after surgery completion. Tooth #38 was extracted due to considerable bone loss, mobility and persistent endodontic lesion. Teeth #48, #44 and #34 received metal-ceramic crowns over self-tapping abutments, which replaced the old abutments (which presented inadequate size). Implant-supported metal-ceramic FPDs were installed 5 months after surgery.

After replacing the prostheses (Figs 12, 13 and 14), the VDO was restored and a mutually protected occlusion pattern was achieved. It can be observed an overbite, and the anterior prosthesis projected toward buccal region, due to the implants position. However this pattern was chosen because of patient's aesthetic necessity (overbite with lips at rest). As the lower teeth were extruded, teeth projection to buccal direction was necessary even after occlusal stripping and clinical crown lengthening in this region.

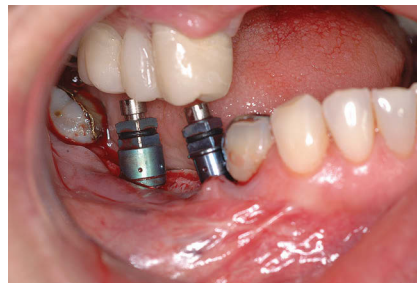The present case is in clinical and radiographic control after 3 years and it is observed maintenance of the achieved aesthetics and function, besides patient satisfaction and comfort (Figs 15 and 16).

### Discussion

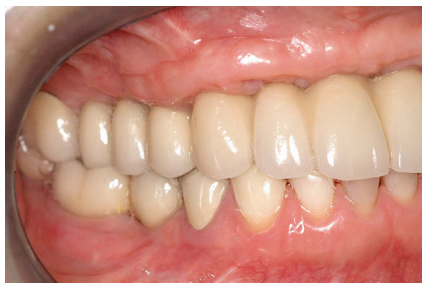The masticatory function reflects the impact of chewing capacity on food choice and pleasure in feeding, and is associated with quality of life and general well being of the individual<sup>11</sup>. Missing teeth and also the use of inadequate prosthesis implies in consequences as speech problems and acceptance of physical appearance, with serious consequences such as decrease in self-esteem, socialization difficulties, perception of aging and humiliation feeling.<sup>12</sup> The aesthetic perspective, being imbued with cultural values, is one of the main concerns of individuals, which implies in feelings of approval or rejection eventually, thus interfering with



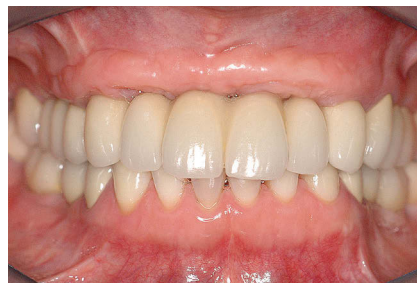**Figure 10** - Left side mandibular implants.



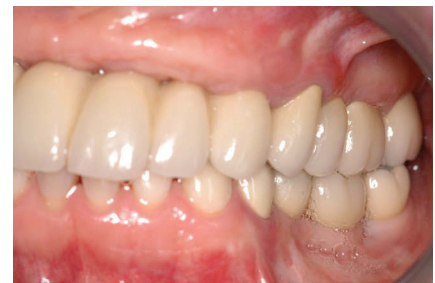**Figure 11** - Right side mandibular implants.



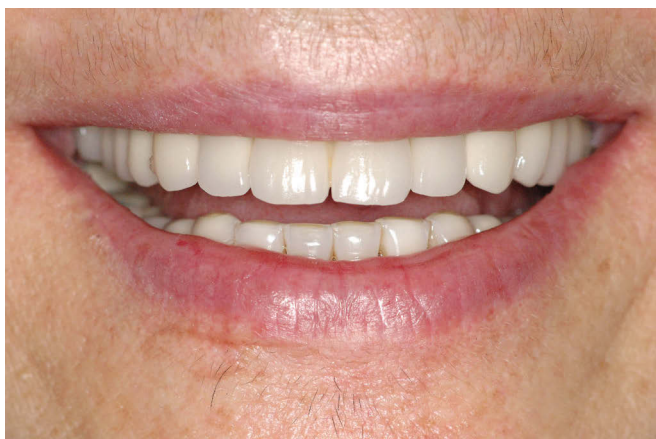**Figure 12** - Final left side intraoral photograph.



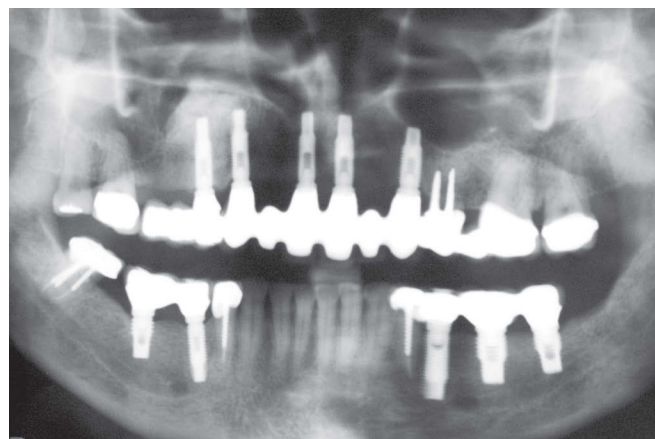
**Figure 13** - Final frontal intraoral photograph.



**Figure 14** - Final right side intraoral photograph.



**Figure 15** - Final smile photograph.



**Figure 16** - Final panoramic radiograph.

interpersonal relationships<sup>13</sup> Thus, expectations of the patients in the face of prosthetic replacement of teeth is related to the quality of the prosthesis, especially regarding stability and adaptation.<sup>12</sup> Currently, prosthetic rehabilitation counts on dental implants to fulfill functional and aesthetic demands.<sup>5</sup>

Advances in diagnostic imaging have contributed to more precise planning, thus providing potential for a significant reduction in complications with dental implants, exerting vital role in surgical planning as well as in routine postoperative evaluation.<sup>4</sup> One of the most useful techniques for diagnosis of patients seeking for fixed prostheses is the diagnostic wax-up, as it allows for recovery of edentulous space and articulation, besides atypical contours.<sup>14</sup> In the case described in the present article, the panoramic radiograph was used as an auxiliary resource in planning.

In some patients, there is not enough bone volume or quality to allow successful placement of implants (for example, after injury or after a long period using a removable prosthesis). To overcome these obstacles, residual bone crest can be increased in width and/or thickness with bone grafts.<sup>6</sup> Bone defects located in the anterior maxilla are

usually reconstructed with autologous mono-cortical bone blocks for subsequent placement of dental implants.<sup>7</sup> In the posterior maxilla, maxillary sinus floor elevation was designed to increase the required vertical height.<sup>8</sup>

Various graft materials have been used in maxillary sinus augmentation procedures, including: decalcified, dry and frozen autogenous bone; hydroxyapatite;  $\beta$ -tricalcium phosphate; deproteinized bovine bone mineral and the combination of these and other<sup>15</sup>. Although new techniques and bone-graft substitutes allow for viable prognostic to achieve the necessary amount of hard tissue augmentation, autogenous bone is the gold standard with regard to quantity, quality, and healing without complications, especially when used in blocks in the anterior maxilla.<sup>6,16,17</sup> To augment the maxillary sinus floor, from a clinical point of view, the use of autogenous bone is advantageous if the prosthetic rehabilitation (with functional load) is expected within nine months. When there is no sufficient amount of autogenous bone in the oral cavity region for grafting and the patient can not or will not accept the collection of bone tissue from extraoral donor sites, the use of deproteinized bovine bone mineral alone, or in combination with autogenous bone, seems to be preferable.<sup>15</sup>

The procedure seems to be simple, safe and effective for the treatment of alveolar ridge defects located in partially edentulous jaw<sup>6</sup>; however, exposure and/or infection of the graft can occur in less than 5% of cases, which eventually leads to bone graft loss.<sup>16</sup> To achieve success, some features should be assessed, as the size and location of the defect; however, the vascularization of the receiving area should be the primary concern of the surgeon, as this directly influences the successful grafting of both hard tissues (one should verify the good adaptation of graft to the receiving site, to prevent the formation of connective tissue in the gap) and soft tissues (the tissue margins should allow passive coaptation of tissue by the suture and promote vascularization in the region).<sup>16</sup> Appropriate donor area should be chosen, which should have intramembranous origin, as in mandible body and ramus, that undergoes less resorption than those with endochondral origin.<sup>17</sup>

Clinical success and longevity of dental implants are largely influenced by the mechanical medium in which they operate, being occlusion a critical component of this environment.<sup>18</sup> In prosthetic restorations of natural dentition, treatment goal is a mutually protected occlusion. The curve of Spee plays an important role in the development of the desired occlusal scheme.<sup>19</sup> Occlusal condition must be properly diagnosed, corrected or compensated, and integrated into the final restoration project.<sup>18</sup> Adjustments should be performed in centric relation to favor the recovery of the vertical dimension and to promote the physiological adaptation of the patient to a mutually protected occlusion.<sup>20</sup> In the present case, occlusion in centric relation was obtained by manual guide, using the unforced guided method.

Fixed prosthesis for partial or total edentulous patients usually consist of implants connected by a bar of metal alloy that supports the prosthetic coating. The loads induce stresses in both structures, prosthesis and bone tissue. An estimate of the reliability of prosthetic systems should consider the biological, chemical, clinical and biomechanical aspects. Biomechanical aspects are important to assess the risk of bone resorption.<sup>21</sup>

Treatment outcomes are improved when implants does not need to support excessive occlusal forces, are placed in dense bone, are used in larger number or diameter, and positioned so as to reduce flexural torque and to support fixed prosthesis.<sup>22</sup> Metal-ceramic FPDs are suitable to increase fracture strength, thus presenting greater clinical longevity. This type of prosthesis is primarily used when a large number of teeth replacement is required<sup>23</sup>. It is also important to maintain a small space for hygiene, however this should not interfere with patient phonation. In the case presented, there was no air leakage, promoting a natural phonation.

Carefully choosing components and the system to connect implants and prosthetic restorations must be considered as a parameter for long-term success of treatment.<sup>24</sup> For extensive dental rehabilitations, the use of screw-retained prosthesis may be the best choice, due to reversibility, which is useful for conducting periodic reevaluations and assessment of oral hygiene.<sup>26</sup> Splinting is also indicated as it is a biomechanically more proper option, promoting a better force distribution both in the implant/abutment system and the bone/implant interface.<sup>25</sup> Periodic appointments after placement of final restoration allow monitoring the current condition of the patient and performing an early diagnosis, which enables interception of problems that can arise, avoiding any possible failure of prosthetic rehabilitation.<sup>3</sup>

In the presented case, metal ceramic screw-retained implant-supported FPDs have been installed and are in regular clinical control. It could be verified treatment success and patient satisfaction.

## Conclusion

In conclusion, based on the reviewed literature and the case reported, oral rehabilitation with fixed prosthesis must be accomplished by careful planning according to patient needs, in a multidisciplinary approach, to restore patient function, comfort and aesthetics.

## REFERENCES

1. Silva MES, Villaça EL, Magalhães CS, Ferreira EF. Impacto da perda dentária na qualidade de vida. *Ciência Saúde Colet*. 2010;15(3):841-50.
2. Pini NIP, Khoury EMDA, Pascotto RC. Tratamento interdisciplinar para reabilitação estética do sorriso. *Rev Dental Press Estét*. 2010;7(2):40-50.
3. Fradeani M, Barducci G. Reabilitação estética em prótese fixa. Tratamento protético. 2ª ed. São Paulo: Quintessence; 2009.
4. Angelopoulos C, Aghaloo T. Imaging technology in implant diagnosis. *Dent Clin North Am*. 2011;55(1):141-58.
5. Merdji A, Bouiadja BB, Achour T, Serier B, Chikh BO, Feng ZO. Stress analysis in dental prosthesis. *Comp Mater Sci*. 2010;49:126-33.
6. Al-Khaldi N, Sleeman D, Allen F. Stability of dental implants in grafted bone in the anterior maxilla: longitudinal study. *Br J Oral Maxillofac Surg*. 2011;49(4):319-23.
7. Acocella A, Bertolai R, Colafranceschi M, Sacco R. Clinical, histological and histomorphometric evaluation of the healing of mandibular ramus bone block grafts for alveolar ridge augmentation before implant placement. *J Craniomaxillofac Surg*. 2010;38(3):222-30.
8. Hieu FD, Chung JH, Yim SB, Hong KS. A radiographical study on the changes in height of grafting materials after sinus lift: a comparison between two types of xenogenic materials. *J Periodontal Implant Sci*. 2010;40(1):25-32.
9. Ivanhoe JR, Cibirka RM, Parr GR. Treating the modern complete denture patient: a review of the literature. *J Prosthet Dent*. 2002;88(6):631-5.
10. Ogawa T, Koyano K, Umemoto G. Inclination of the occlusal plane and occlusal guidance as contributing factors in mastication. *J Dent*. 1998;26(8):641-7.
11. Kim Y, Oh TJ, Misch CE, Wang HL. Occlusal considerations in implant therapy: clinical guidelines with biomechanical rationale. *Clin Oral Implants Res*. 2005;16(1):26-35.
12. Alencar Jr FGP, Oliva EA. Conceitos atuais de oclusão e ajuste oclusal. In: Alencar Jr FGP. *Oclusão, dores orofaciais e cefaléia*. São Paulo: Ed. Santos; 2005. p. 253-68.
13. Brennan DS, Spencer J, Roberts-Thomson KF. Tooth loss, chewing ability and quality of life. *Qual Life Res*. 2008;17(2):227-35.
14. Silva MES, Magalhães CS, Ferreira EF. Perda dentária e expectativa da reposição protética: estudo qualitativo. *Ciênc Saúde Coletiva*. 2010;15(3):813-20.
15. Mori AT, Cardozo HF. Expectativas com relação aos resultados estéticos dos tratamentos odontológicos. *Rev Paul Odontol*. 2004;26(2):12-6.
16. Dalvit DL, Parker MH, Cameron SM. Quick chairside diagnostic wax-up. *J Prosthet Dent*. 2002;87(5):581-2.
17. Handschel J, Simonowska M, Naujoks C, Depprich RA, Ommerborn MA, Meyer U, et al. A histomorphometric meta-analysis of sinus elevation with various grafting materials. *Head Face Med*. 2009;5(12):1-10.
18. Chiapasco M, Zaniboni M. Failures in jaw reconstructive surgery with autogenous onlay bone grafts for pre-implant purposes: incidence, prevention and management of complications. *Oral Maxillofac Surg Clin North Am*. 2011;23(1):1-15.
19. Sittitavornwong S, Gutta R. Bone graft harvesting from regional sites. *Oral Maxillofac Surg Clin North Am*. 2010;22(3):317-30.
20. Prashanti E, Sumanth K, Reddy J. Components of implant protective occlusion: a review. *Int J Dent Sci*. 2009;7(2):8.
21. Marshall SD, Caspersen M, Hardinger RR, Franciscus RG, Aquilino SA, Southardf TE. Development of the curve of Spee. *Am J Orthod Dentofacial Orthop*. 2008;134(3):344-52.
22. Pokorny PH, Wiens JP, Litvak H. Occlusion for fixed prosthodontics: A historical perspective of the gnathological influence. *J Prosthet Dent*. 2008;99(4):299-313.
23. Natali AN, Pavan PG, Ruggero AL. Evaluation of stress induced in peri-implant bone tissue by misfit in multi-implant prosthesis. *Dent Mater*. 2006;22(4):388-95.
24. Şahin S, Çehreli MC, Yalçın E. The influence of functional forces on the biomechanics of implant-supported prostheses - a review. *J Dent*. 2002;30(7-8):271-82.
25. Piloto P, Alves A, Correia A, Campos JCR, Fernandes JCS, Vaz MAP, et al. Metal-ceramic fixed partial denture: fracture resistance. *Biodental Engineering*. 2009;5:125-8.
26. Reis AC, Ribeiro JCR, Moysés MR, Dias SC. Planejamento em reabilitação oral. In: *Reabilitação estética e funcional em odontologia*. São Paulo: Lovise; 2006. cap 1, p. 1-3.
27. Goodacre CJ, Bernal G, Kan J. Clinical complications with implants and implant prostheses. *J Prosthetic Dent*. 2003;90(2):121-32.
28. Zarone F, Sorrentino R, Traini T, Di Lorio D, Caputi S. Fracture resistance of implant-supported screw-versus cemented-retained porcelain fused to metal single crowns: SEM fractographics analysis. *Dent Mater*. 2007;23(3):296-301.
29. Farias Neto A. Avaliação clínica e comparativa da oclusão balanceada bilateral e desocclusão com guia canino a função mastigatória de usuários de prótese total removível [tese de doutorado]. Natal (RN): Universidade Federal do Rio Grande do Norte; 2009.