

# Mandibular osteonecrosis associated with bisphosphonate use after implant placement: Case report

Henrique Côrtes **MEIRA\***

Marcelo Matos **ROCHA\***

Vladimir Reimar Augusto de Souza **NORONHA\*\***

Evandro Guimarães de **AGUIAR\*\***

Alexandre Andrade de **SOUSA\*\*\***

Dimas João **RODRIGUES NETO\*\*\*\***

## Abstract

Oral rehabilitation of patients with single or multiple tooth loss using osseointegrated implants has become a successful treatment option. Nevertheless, a serious complication can affect the survival of these implants: osteonecrosis of the jaw associated with the use of bisphosphonates. Bisphosphonates are a class of drugs that have the function of inhibiting the activity of osteoclasts, interfering with bone remodeling and turnover. They are recommended to postpone bone impairment in some malign conditions such as multiple myeloma as well as metastatic breast cancer and prostate cancer, also in the treatment of Paget's disease and osteoporosis. Clinically, BRONJ (Bisphosphonate-Related Osteonecrosis of the Jaw) appears as loss of continuity of the oral mucosa with exposure of the underlying bone. It can be extremely painful, persistent and does not respond to conventional treatments. The objective of this paper is to conduct a literature review on the subject and report a case of BRONJ after implant placement.

**Keywords:** Osteonecrosis. Bisphosphonate-related osteonecrosis of the jaw. Dental implants.

**How to cite this article:** Meira HC, Rocha MM, Noronha VRAS, Aguiar EG, Sousa AA, Rodrigues Neto DJ. Mandibular osteonecrosis associated with bisphosphonate use after implant placement: Case report. *Dental Press Implantol.* 2013 Apr-June;7(2):107-14.

» The authors report no commercial, proprietary or financial interest in the products or companies described in this article.

## Contact address

**Henrique Côrtes Meira**  
Rua Kimberlita, 108 - Apt 102 - Santa Tereza - Belo Horizonte/MG, Brazil  
CEP: 31010-260 - E-mail: meirahc@hotmail.com

Submitted: April 25, 2013  
Revised and accepted: May 05, 2013

\* Specialist in Oral and Maxillofacial Surgery and Traumatology, Federal University of Minas Gerais (UFMG).

\*\* Professor of Oral and Maxillofacial Surgery and Traumatology, Federal University of Minas Gerais (UFMG).

\*\*\* Head and neck surgeon, Vila da Serra Hospital.

\*\*\*\* Professor of Dental Prosthesis, University of Southern Santa Catarina (UNISUL).

» Patients displayed in this article previously approved the use of their facial and intraoral photographs.

## Introduction

Oral rehabilitation of patients with single or multiple tooth loss using osseointegrated implants has become a highly successful treatment option. Nevertheless, a serious complication can affect the survival of these implants: osteonecrosis of the jaw associated with the use of bisphosphonates. Globally known as Bisphosphonate-Related Osteonecrosis of the Jaw (BRONJ), it is a disease characterized by necrotic bone exposure affecting both the mandible and the maxilla. Clinically, they arise as continuous loss of the oral mucosa with exposure of the underlying bone, similar to radiation-induced osteonecrosis, or osteoradionecrosis. They can be extremely painful and persistent, and do not respond to conventional treatment methods such as debridement, antibiotic therapy and hyperbaric oxygen therapy.<sup>1,2</sup>

Bisphosphonates are a class of drugs that have the function of inhibiting the activity of osteoclasts. They are strongly related to the bones, given that they interfere in bone remodeling and turnover and also possibly interfere in angiogenesis by hindering vascular endothelial growth factor.<sup>2</sup>

This condition hampers implant placement due to the fact that osseointegration process depends on normal bone physiology. In spite of that, bisphosphonates bring great benefits to patients' quality of life. They can be taken orally or intravenously, and are recommended to postpone bone impairment in some malign conditions such as multiple myeloma, breast and prostate cancer metastasis, as well as for the treatment of Paget's disease and osteoporosis. The most recent nitrogenous bisphosphonates, the aminobisphosphonates, are highly effective and present greater selectivity. The aminobisphosphonates most often used are: alendronate, risedronate, ibandronate, pamidronate and zoledronate.<sup>2,6</sup>

In the last few years, literature has described the association between osteonecrosis of the jaw and the use of bisphosphonates. The first case report was published in 1995, in a oral and maxillofacial surgery journal, and established a relationship between bisphosphonates and unsuccessful osseointegration of implants placed in the mandible of a patient who had been subjected to therapy with bisphosphonates to treat osteoporosis.<sup>3</sup>

The first extensive literature review focusing on the subject was published in 2003 by Marx et al,<sup>4</sup> and comprised 36 case reports of maxillary osteonecrosis associated with the use of pamidronate and zoledronate. Patients' mandible was affected in 80% of the cases, while their maxilla was affected in 14%, and in 6% of cases both were affected. The lesions were associated with dental extractions in 78% of cases, whereas in the remaining 22% they had been spontaneously developed.

Ruggiero et al<sup>5</sup> published an analysis of 63 cases of patients with osteonecrosis of the jaw associated with the use of bisphosphonates. The authors identified that, in most cases, the typical symptoms were pain and bone exposure where the tooth had been previously extracted. Additionally, they observed that only 14% of patients had not been subjected to any previous dental procedures, therefore, presenting spontaneous bone exposure.

Marx et al<sup>6</sup> analyzed 119 cases of osteonecrosis of the jaw, out of which 68.1% presented mandibular osteonecrosis, 27.7% maxillary osteonecrosis and 4.2% both mandibular and maxillary osteonecrosis. These patients were using different types of bisphosphonates to treat multiple myelomas (52.1% of cases), breast (42%) or prostate (3.4%) cancer metastasis and osteoporosis (2.5%). The causes of bone exposure were as follows: spontaneous exposure (25.2%), tooth extraction (37.8%), severe periodontitis (28.6%), periodontal surgery (11.2%), dental implants (3.4%) and endodontic surgery (0.8% of cases).

Rincón et al<sup>7</sup> analyzed 15 cases of osteonecrosis associated with the use of bisphosphonates, among which 10 were women (66.6%) and 5 were men (33.3%) with mean age of 64 years (41 to 75 years old). Tooth extraction was present in 6 cases. The most affected spot was the mandible (12 cases), followed by the maxilla (2 cases) and both (1 case). More severe complications were found in these patients: three cases of cutaneous fistula, two cases of oro-antral communication associated with maxillary sinusitis and one case of pathological mandibular fracture.

The risk of osteonecrosis of the jaw occurring in patients subjected to the use of bisphosphonate suggests that all elective surgical procedures, such as implant placement, must be avoided. Published data suggest that tooth extraction is the main etiological factor behind the development of BRONJ, and that only a few cases of osteonecrosis or unsuccessful implants were a consequence of surgical procedures performed for dental implant placement.<sup>8,9</sup>

Koka et al<sup>8</sup> carried out a survey in which 370 female/post-menopause patients older than 50 years of age and who had been subjected to implant placement surgery (818 implants) were included. Patients were divided into two groups: users of bisphosphonates for treating osteoporosis or osteopenia (BP group) and non-users of bisphosphonates (non-BP group), totaling 69 patients (with 148 implants) in BP group and 301 patients (with 670 implants) in non-BP group. Survival rates were generally excellent for both groups, with 120 out of 121 (99.17%) implants from BP group and 163 out of 166 (98.19%) implants from non-BP group.

Martin et al<sup>9</sup> also analyzed 8,572 individuals subjected to bisphosphonates therapy, out of which 589 claimed to have dental implants, including 130 who had the implants placed a year before. Implant failure was

observed in 16 individuals, all of which were women whose mean age was  $70.2 \pm 7.6$  years old. All of them had been subjected to alendronate therapy, orally taken, either to treat primary or secondary osteoporosis, or to prevent fractures. Within the subgroup comprising 16 patients with implant failure, a total of 44 implants were placed, out of which 26 were unsuccessful, with 8 implants presenting early loss ( $\leq 1$  year) and 18 presenting late loss ( $> 1$  year).<sup>9</sup>

In this context, the objective of this study is to report a case of a female patient presenting osteonecrosis of the jaw associated with the use of bisphosphonates after implant placement.

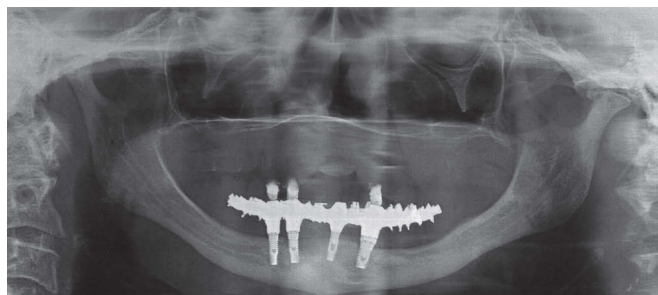
### Case report

A 78-year-old Caucasian female patient was referred to the Clinic of Oral and Maxillofacial Traumatology, School of Dentistry, Federal University of Minas Gerais, in November/2012, for evaluation of active mandibular infection between foramina, after loss of implants previously placed at unknown date. During the first interview, the patient reported having used medication to control arterial hypertension. The patient was once more questioned about the use of medication, and then she reported that was taking a medication which she considered to be unimportant, given that it was taken once a week, only. After thorough investigation, it was found that she made use of alendronate sodium, a type of bisphosphonate used to control osteoporosis. It had been orally taken, once a week, for four years.

Patient's previous dental history revealed placement of four implants in the interforaminal region of the mandible, in addition to prosthetic rehabilitation (Fig 1). With the definitive prosthesis already in place, the patient complained about discomfort in the region of implants. In order to further investigate this issue, a computed tomography was requested (Fig 2).

The exam revealed a hypodense area near one of the implants, suggesting bone rarefaction as well as peri-implant bone loss. After finding out about the alterations in the implants, the patient decided to stop using the bisphosphonate without communicating her doctor/dentist. Although she was no longer taking the medication, her clinical condition worsened, including inflammation, infection and loss of implants (Fig 3).

Later, the patient presented with acute abscess, with increased volume in the submandibular region, erythema, trismus, severe pain, dysphagia and active intraoral drainage in the inferior alveolar ridge (Figs 4 and 5).

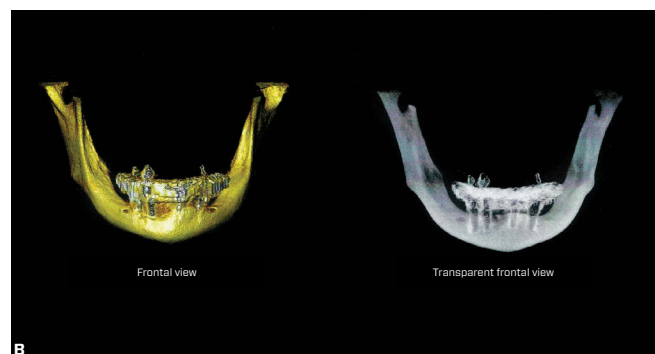
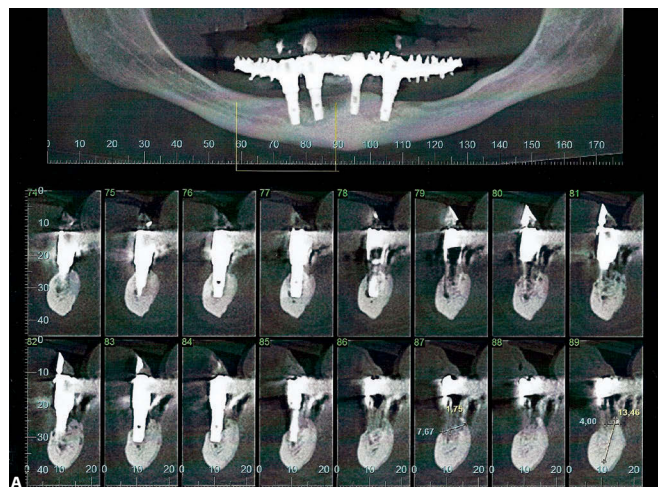


**Figure 1** - Panoramic radiograph revealing four implants placed and in masticatory function.

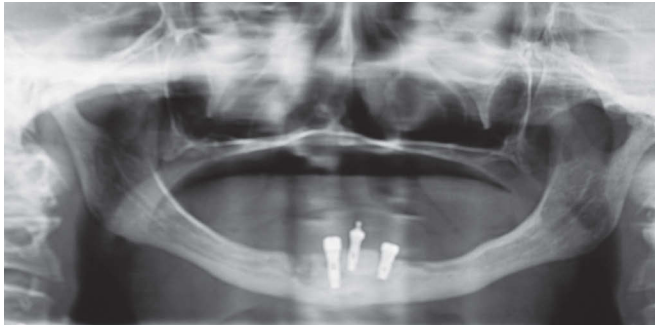
Analyzing a new CT scan (axial slices and 3D reconstruction) absence of implants and widespread destruction of the mandibular symphysis bone was noticed (Fig 6).

Initial treatment comprised antibiotic therapy with oral clindamycin, mouthwash with 0.12% chlorhexidine gluconate, as well as surgery for conservative debridement in the area (Fig 7). Since the expected results were not achieved, the patient was referred to the Service of Head and Neck Surgery and, 3 months after the initial appointment, she was submitted to surgery for en bloc resection of the anterior mandible, under general anesthesia and in hospital setting.

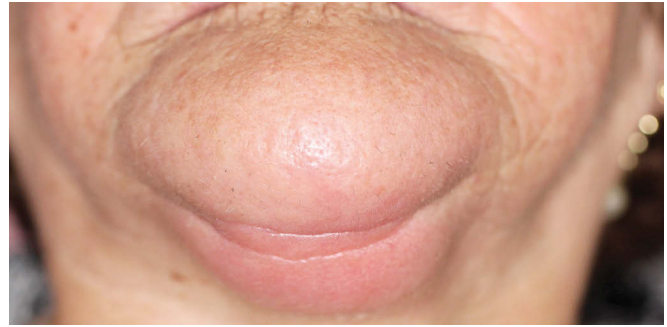The patient is currently under clinical and radiographic follow-up. A panoramic radiograph taken after two months (Fig 8) revealed absence of osteonecrosis signs, whereas clinical examinations reveal no signs of infection or further complications (Figs 9 and 10). The patient presents satisfactory mouth opening without limitations on feeding; does not complain about pain; reports improvements in her quality of life and is satisfied with treatment outcomes.



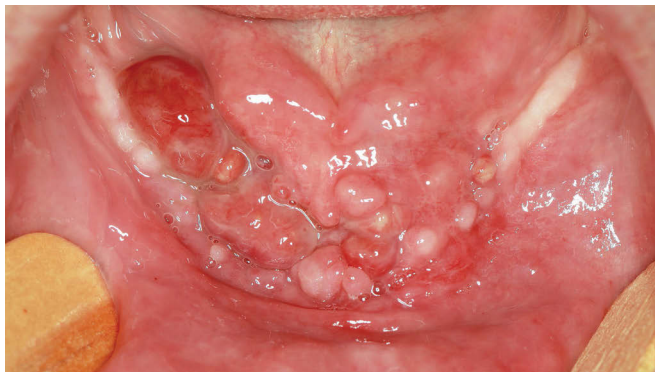**Figure 2** - **A)** Computed mandibular tomography, axial slices and panoramic reconstruction revealing hypodense area at slices 78 to 82, suggesting bone rarefaction near the implant. **B)** 3D reconstruction.



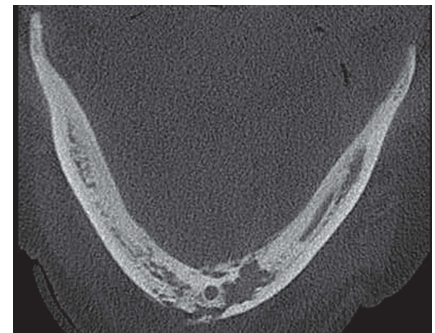
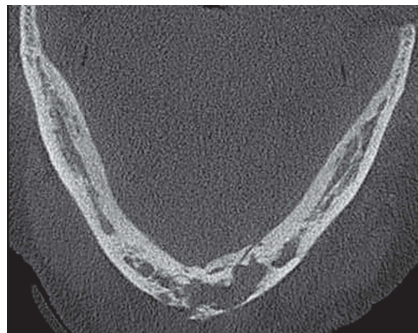
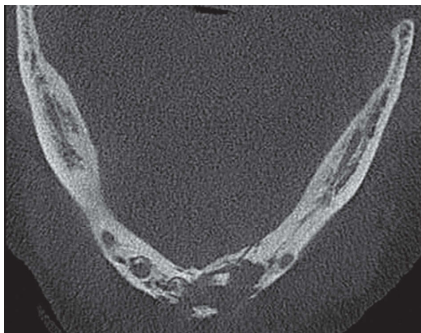
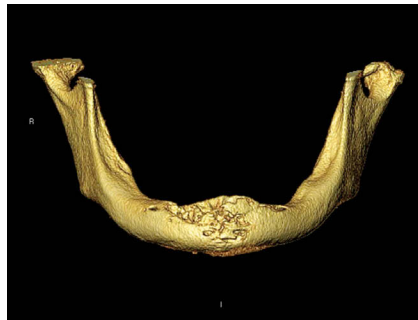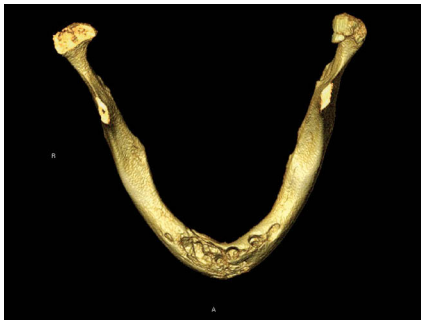**Figure 3** - Panoramic radiograph revealing loss of implants, associated with bone rarefaction.



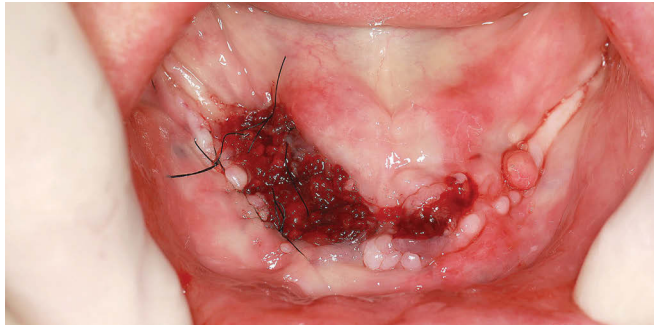
**Figure 4** - Extraoral view of abscess: increase in submandibular volume and erythema.



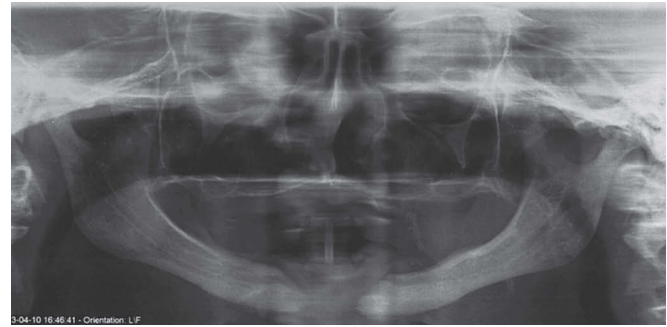**Figure 5** - Intraoral view: active drainage in the alveolar ridge, increase in volume and erythema.



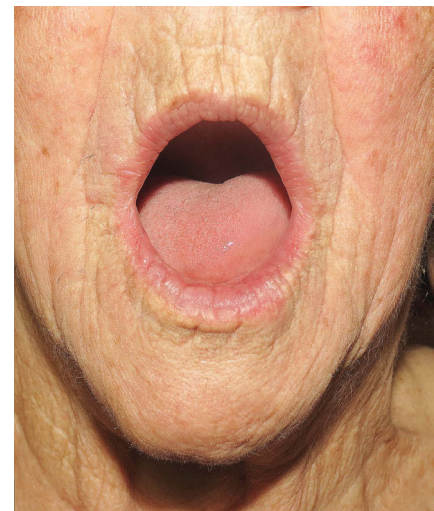
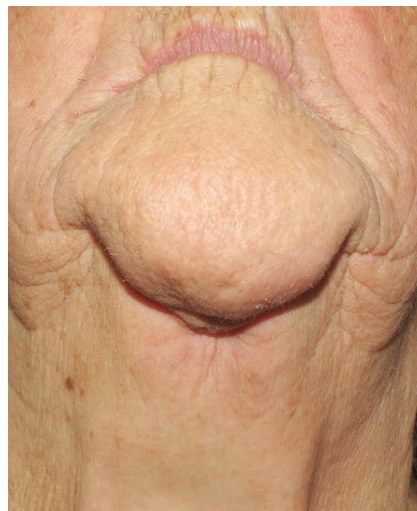
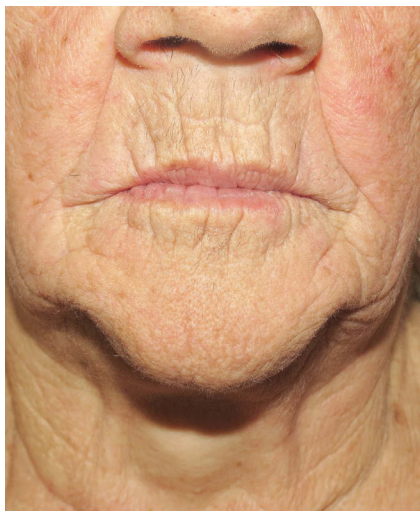
**Figure 6** - Computed tomography (axial slices and 3D reconstruction), revealing absence of implants and severe destruction of mandibular symphysis bone.



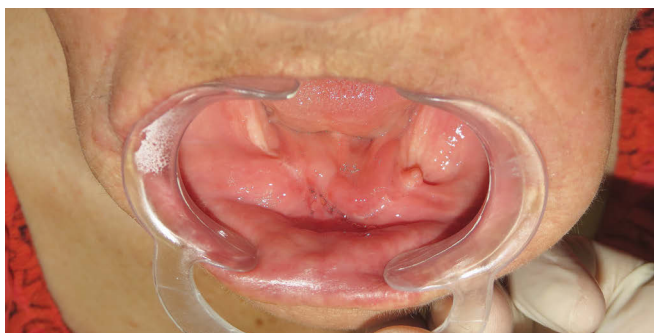**Figure 7** - Immediate postoperative intraoral view of debridement surgery.



**Figure 8** - Panoramic radiograph revealing resection of anterior mandible and absence of osteonecrosis symptoms.



**Figure 9** - Postoperative extraoral views two months after en bloc resection surgery. Good mouth opening, no signs of infection, deformities or complaints.



**Figure 10** - Postoperative intraoral view two months after en bloc resection surgery.

## Discussion

Although additional studies are needed to further investigate the relationship between osteonecrosis of the jaw and the use of bisphosphonates, a direct correlation between them cannot be ignored. Many cases have been reported in the literature, and show evidence that women comprise the majority of affected individuals,<sup>4-8</sup> as shown in the case reported herein. Additionally, it should be highlighted that there is a marked tendency of osteonecrosis occurs in the mandible<sup>4-8</sup> (which corroborates the present paper), and that the most common BRONJ clinical presentation consists of pain, incomplete or late tissue repair, soft tissue collapse, infection, bone necrosis and osteomyelitis.<sup>2</sup>

Many authors claim that most patients with maxillary osteonecrosis are under use of bisphosphonates to treat hypercalcemia associated with multiple myeloma and breast cancer, followed by osteoporosis and prostate cancer. Oral bisphosphonates are the most common osteoporosis therapy.<sup>2,6</sup> In the case reported herein, the patient made use of oral alendronate sodium, a type of aminobisphosphonate.

According to the literature, osteonecrosis can spontaneously occur, however, a precipitating event is present in the majority of cases.<sup>6</sup> Tooth extraction is the main etiologic factor, but implant placement can also lead to BRONJ, as in the case reported herein. Although many studies recommend rehabilitation with osseointegrated implants in patients under use of bisphosphonates,<sup>8,9</sup> this therapy must be carefully performed and multidisciplinary measures must be taken in order to minimize any potential risks. Additionally, it is required that clinicians carefully carry out the first interview with the patient and discuss with the doctor in charge about the feasibility of surgical interventions in these patients. Additional studies are required to further investigate the topic, given that it is a new condition for which no evidence-based protocol has been developed.

Moreover, whenever oral surgeries are necessary, the possibility of interrupting therapy conducted with bisphosphonates should be considered in order to prevent BRONJ. It must be done with the doctor's consent at least three months before and three months after surgery.<sup>2</sup> In the case reported herein, such recommendation was not followed before the first intervention, given that the patient did not inform her dental surgeon that she made use of alendronate sodium. Furthermore, the patient decided to stop using the medication without proper medical advice, since she believed that taking too much medication was the cause of the alterations. In spite of stopping the medication, she presented no regression of infection.

BRONJ therapy, whether conservative or radical, varies from author to author. Conservative treatment includes oral or intravenous antibiotic therapy, mouthwashes or wound irrigation to reduce bacteria and colonization in cases associated with infection; as well as surgical removal of bone sequestrum in symptomatic cases in which the painful bone necrosis area is a source of ongoing infection and does not respond to local and systemic antibiotic therapy. Should conservative treatment not be effective, some authors suggest bone resection with a safety margin, for which a more aggressive surgery is necessary.<sup>2</sup> In the present case, an attempt at conservative treatment was made, with oral and topic antibiotic therapy, in addition to two debridement interventions. Since conservative treatment was rendered unsuccessful, en bloc resection of the affected bone was carried out.

## Conclusion

Based on the results of the present study, it is reasonable to conclude that osteonecrosis of the jaw associated with bisphosphonates is a severe complication, difficult to be managed at a dental clinic and that may cause severe morbidity and sequelae to the patient.

Therefore, prevention is of paramount importance, and so is the dental surgeon, given that he will advise the patient who uses bisphosphonates with regard to oral hygiene and elimination of any potential infectious focus, establishing criteria for dental evaluation similar to those applied to patients undergoing head and neck radiotherapy. Furthermore, it is essential that the dental surgeon be aware of the risks of BRONJ, its consequences and treatment methods, so as to conduct his cases as satisfactory as possible.

## REFERENCES

1. Migliorati CA, Casiglia J, Epstein J, Jacobsen PL, Siegel MA, Woo SB. Managing the care of patients with bisphosphonate-associated osteonecrosis: an American Academy of Oral Medicine position paper. *J Am Dent Assoc.* 2005;136(12):1658-68.
2. Capelari MM. Osteonecrose dos maxilares associada à bisfosfonatos: revista de literatura e relato de caso [monografia]. Bauru (SP): Associação Paulista de Cirurgiões-Dentistas; 2010.
3. Starck WJ, Epkner BN. Failure of osseointegrated dental implants after bisphosphonate therapy for osteoporosis: a case report. *Int J Oral Maxillofac Implants.* 1995;10(1):74-8.
4. Marx RE. Pamidronato (Aredia) e Zoledronato (Zometa) induced avascular necrosis of the jaws: a growing epidemic. *J Oral Maxillofac Surg.* 2003;61:1115-7.
5. Ruggiero SL, Mehrotra B, Rosenberg TJ, Engroff SL. Osteonecrosis of the jaws associated with the use of bisphosphonates: a review of 63 cases. *J Oral Maxillofac Surg.* 2004;62(5):527-34.
6. Marx RE, Sawatari Y, Fortin M, Broumand V. Bisphosphonate-induced exposed bone (osteonecrosis/osteopetrosis) of the jaws: risk factors, recognition, prevention and treatment. *J Oral Maxillofac Surg.* 2005;63(11):1567-75.
7. Heras Rincón I, Zubillaga Rodríguez I, Castrillo Tambay M, Montalvo Moreno JJ. Osteonecrosis of the jaws and bisphosphonates. Report of fifteen cases. Therapeutic recommendations. *Med Oral Patol Oral Cir Bucal.* 2007;12(4):E267-71.
8. Koka S, Babu NMS, Norell A. Survival of dental implants in post-menopausal bisphosphonate users. *J Prosthodont Res.* 2010;54(3):108-11.
9. Martin DC, O'Ryan FS, Indresano AT, Bogdanos P, Wang B, Hui RL, et al. Characteristics of implant failures in patients with a history of oral bisphosphonate therapy. *J Oral Maxillofac Surg.* 2010;68(3):508-14.