

Behavior of peri-implant tissues in immediate implant with provisionalization: A literature review

Danielle Borges Nunes Fernandes **SILVA***

Leonardo da Costa **NEVES****

Enzo **QUERINO*****

José Carlos Martins da **ROSA******

Mauricio Andrade **BARRETO*******

Abstract

Introduction: Implantodontics has reached a level in which osseointegration alone is no longer enough for treatment success. Today, in addition to recovering function, the implant must be associated with esthetic restorations that are similar to natural dentition, in harmony with surrounding teeth and with other peri-implant structures. The healing process after tooth loss is unfavorable to soft tissues that follow bone remodeling, compromising esthetics. The use of immediate implants and provisionalization enables a treatment approach that aims at maintaining peri-implant tissues, replacing treatment of atrophy sequelae after extraction. **Objective:** The aim of this paper is to conduct a literature review in order to identify and discuss the determinants of morpho-esthetic-functional tissue peri-implant behavior in immediate implant placement with provisionalization. **Methods:** PubMed database was used as a research resource considering the period between 2003 and 2012. **Results:** Within the limits of this review, it was reasonable to conclude that the esthetic results in implant therapy are influenced by tissue biotype, especially in the peri-implant mucosa. The thin biotype revealed higher susceptibility to gingival recession. Conversely, tissue biotype revealed little influence over the height of the interproximal papilla. Filling the gap with autogenous bone graft contributed to the maintenance of the structures around the implant, but we can not affirm the existence of superiority between different graft materials. **Conclusion:** Subepithelial connective tissue graft seems to positively influence the level of marginal mucosa.

Keywords: Immediate dental implant loading. Tooth extraction. Single-tooth dental implants.
Tooth alveolus.

How to cite this article: Silva DBNF, Neves LC, Querino E, Rosa JCM Barreto MA. Behavior of peri-implant tissues in immediate implant with provisionalization: A literature review. *Dental Press Implantol.* 2013 July-Sept;7(3):41-51.

» The authors inform they have no associative, commercial, intellectual property or financial interests representing a conflict of interest in products and companies described in this article.

» The patients displayed in this article previously approved the use of their facial and intraoral photographs.

Submitted: March 04, 2012
Revised and accepted: February 27, 2013

* Professor, specialization course in Implantodontics, NPCL.

** Assistant professor, specialization course in Dental Prosthesis, ABO-BA.

*** Professor, specialization course in Implantodontics, BAHIANA.

**** Doctorate student of Implantodontics, SLMANDIC.

***** Professor, Masters course in Dentistry and Health Technology, BAHIANA.

Contact address: Leonardo da Costa Neves

R. José Bonifácio - 46 - Centro
CEP: 48.010-090 - Alagoinhas/BA - Brazil
E-mail: leonardo@nect.com.br

Introduction

Clinical success of prosthetic rehabilitation with implant-supported prostheses in the anterior maxilla depends on prostheses esthetically satisfactory for both the patient and the dentist.¹ Today, with the high survival rates of implants, the goal has been to create an esthetic restoration that is similar to the natural tooth and stable over time.^{2,3,4}

Implant placement in single edentulous patients is a highly described routine practice.⁵ Several procedures for bone and gingival augmentation are often recommended^{6,7} due to alveolar bone resorption that occurs during the first year after extraction and reaches its maximum rate during the first 6 months.⁸ Unfortunately, even with technological development, these approaches imply failures in the preservation of residual bone level and marginal gingival contour. These changes lead to short, medium and long-term unsatisfactory esthetic results.⁵

Dentists' approaches towards recommending single-tooth extraction has been broadened. Implantologists who, a few years ago, commonly received patients with no teeth, "ready" to receive an implant, have increasingly been able to decide the best time for extraction and implant placement, which can influence treatment outcomes. Knowledge of alveolar bone physiology and healing processes has changed the planning protocols for cases of extraction in esthetic areas. Chen and Busser⁹ didactically classified as Type 1, or immediate implants, implant placement at the time of extraction, as part of the same surgical procedure; as Type 2, or early implant, implants installed between four and eight weeks after extraction and after soft tissue healing with no clinically significant changes in bone; as Type 3, or early implant placement, implant placement between twelve and sixteen weeks after extraction, with major bone remodeling; as Type 4, or late implantation, implant placement six months after extraction, when the alveolus is completely healed.

Wöhrle¹⁰ innovatively recommended immediate implant placement in fresh alveoli and with immediate loading. Later on, many authors described and improved his technique, proving it to be useful.^{11,12,13} The technique of immediate implant and immediate loading seems to substantially contribute to the preservation of marginal architecture. Figures 1-6 show a case that illustrates the technique of immediate implants with provisionalization (Figs 1 to 6).

The presence of radicular fractures as well periodontal and/or endodontic complications is a challenging problem, since microbial and mechanical sequelae typically induce complete resorption of the labial bone plate. In these cases, the minimum requirements are hardly considered for implant placement and immediate loading. The techniques have been developed in order to associate alveolar bone augmentation procedures with immediate implant placement. However, the type of graft material as well as the surgical technique itself are far from reaching a degree of consensus, especially due to the large number of variables.

Kan et al⁵ report that extrinsic and intrinsic factors can interfere in the results of immediate implant and immediate loading. Extrinsic factors related to the surgical technique include three-dimensional positioning and angulation of the implant,¹⁴ placement time,^{9,15} placement or not of graft^{16,17} and the level of surgical trauma during extraction and implant placement.¹³ As for the prosthesis, shape, provisionalization and manipulation are correlated.¹⁸ With regard to implant design, macrogeometry, surface and implant/abutment interface are included.¹⁹ Intrinsic factors are related to the patient, including gingival biotype,^{5,12} periodontal disease, amount and quality of bone as well as oral health hygiene and maintenance.^{20,21,22}

The aim of this paper is to conduct a literature review in order to identify and discuss the morpho-esthetic-functional behavior of peri-implant tissue after immediate implant placement with immediate provisionalization.

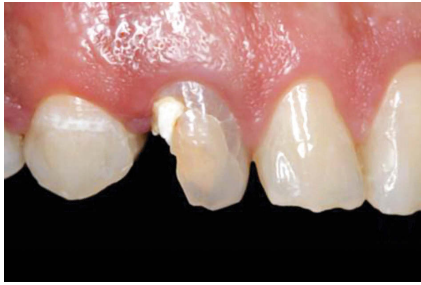

Figure 1 - Clinical image of a right maxillary canine subject to extraction. Note the discrete loss of distal papilla height.

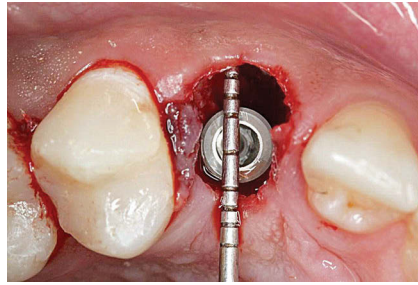


Figure 2 - Note the use of a millimeter probe to measure the space between buccal bone plate and implant surface.

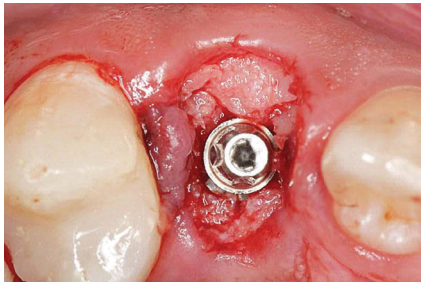


Figure 3 - Note the gap filled with autogenous bone graft collected from the tuberosity.

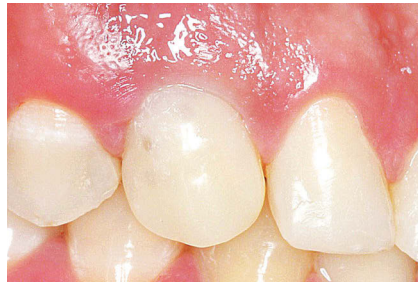

Figure 4 - Postoperative with provisionalization four months after the procedure. Note the distal papilla totally filled and the maintenance of the gingival margin.

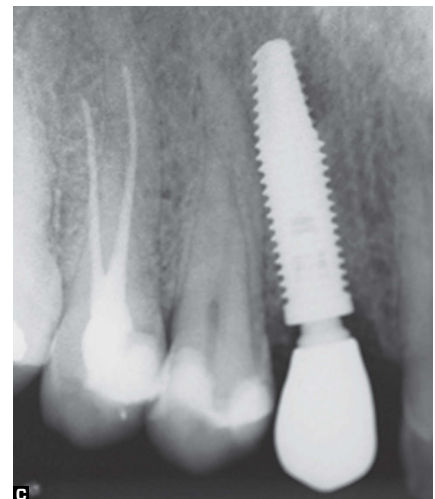
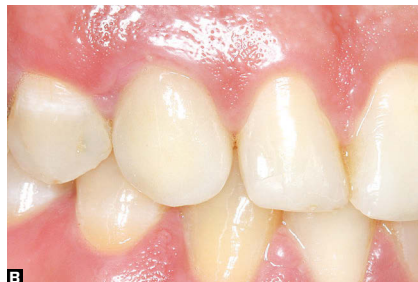
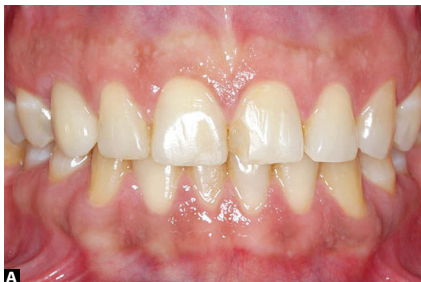Figure 5 - **A)** Final prosthesis. Note the esthetic peri-implantar tissue contour and its resemblance with the contralateral side. **B)** Final prosthesis. **C)** Final radiograph.

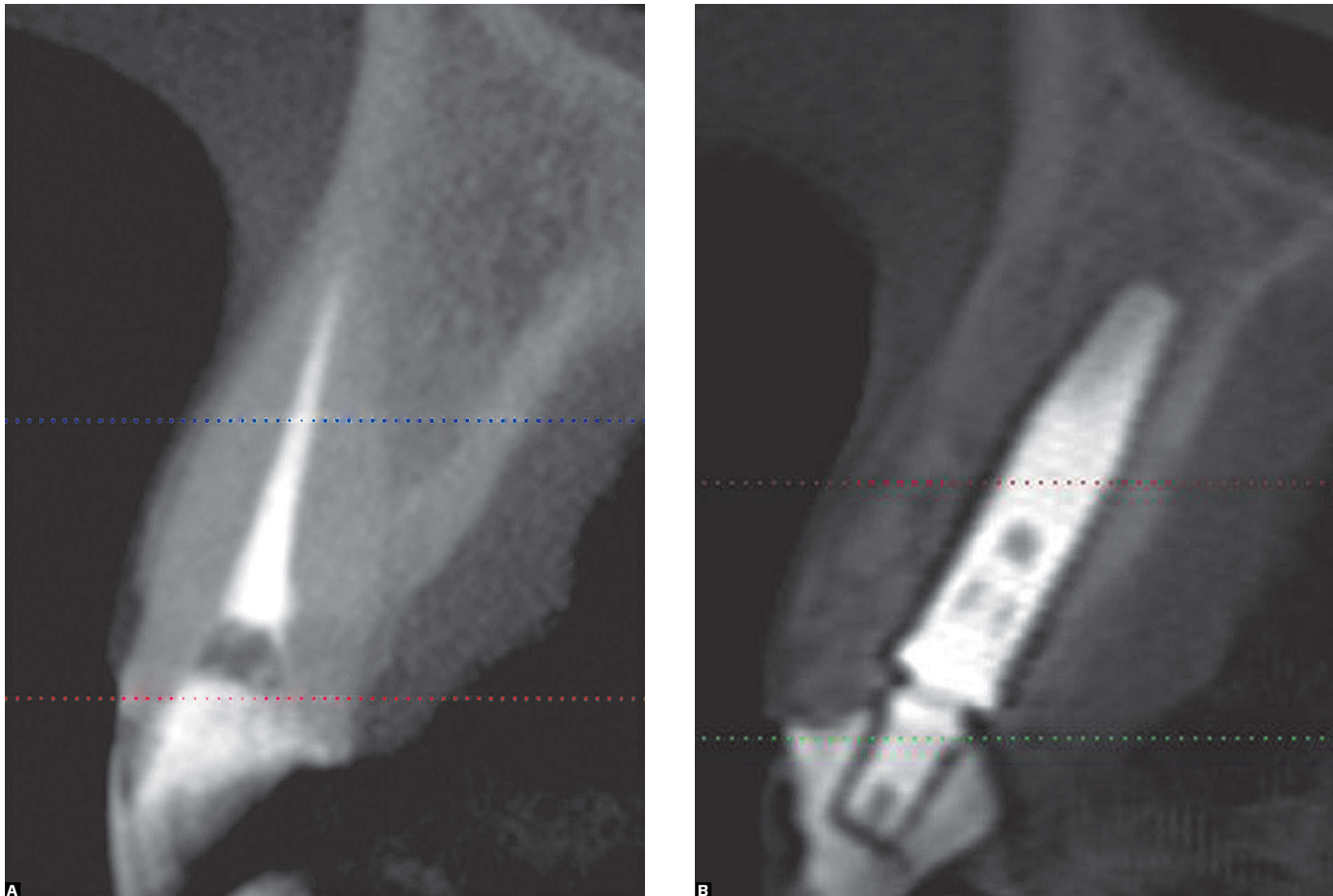


Figure 6 - A) Initial tomographic image. **B)** CBCT one year after final crown. Note appropriate bone volume around the implant, particularly in the buccal cortical zone.

Literature review

PubMed database was used as a research resource considering the period between 2003 and 2012 and the following keywords: provisionalization, bone graft and dental implant, immediate loading, tooth extraction, dental alveolus and single-tooth dental implants. Eighteen studies were selected and the result of this research is summarized in Table 1.

Discussion

In the literature, it is understood that bone remodeling after extraction and peri-implant changes are esthetic complications of implant treatment performed in the anterior region, in addition to suffering multifactorial influence. With regard to the first bone-implant contact, Kan et al⁵ and Raes et al²⁴ found losses in the mesial and distal crest in studies conducted with immediate implants

without graft. Conversely, studies by Cooper et al¹⁷ and Brown et al¹⁹ revealed increased bone level without bone graft. Tsuda et al¹⁶ also reported bone augmentation with xenogeneic (Bio-Oss®) and subepithelial connective tissue graft. However, Levin et al²⁸ used FDBA graft or biphasic calcium phosphate and found resorption of bone crest in the area corresponding to the first bone-implant contact, whereas De Rouck et al,¹² who also used Bio-Oss® graft, found mean mesial bone loss of 1.13 mm, and distal bone loss of 0.86 mm in three years. Intrinsic aspects of patients, study inclusion criteria, operators, graft material, lack of technical standardization and assessment methods may have yielded differences in the results.

Kan et al⁵ found buccal recession (average of 1 mm) immediately after implant placement without graft, a result that was also found by De Rouck et al¹² who used Bio-Oss® graft. Tsuda et al¹⁶ performed grafting with Bio-Oss® and connective tissue. In their study, gingival recession was obtained at a lower degree (0.05 mm), similarly to Cornelini et al³² who used collagen membrane as graft material (recession of 0.5 mm). Without any graft material, Cooper et al¹⁷ observed that the gingival margins were stable and increased in 83%; similarly to Brown et al,¹⁹ who also noticed stability, with gains not greater than 0.2 mm. Conversely, Raes et al²⁴ found stability of the gingival margin in most cases, but with recession in only 7% of cases. They also reported that the results of flapless surgeries showed less recession than those found in conventional surgeries of the same study. Miyamoto et al¹⁵ established a relationship between gingival recession and facial bone thickness greater than 2 mm; while Kan et al⁵ observed that areas of thick gingival biotype showed significantly little changes in the buccal margins (0.56 mm resorption) in comparison to areas of thin gingival biotype in which resorption was as great as 1.5 mm.

With regard to the maintenance of papillae, Kan et al⁵ and Cornelini et al³² reported decreased papillae. El-Chaar et al²⁰

obtained a reduction of around 0.3 and 0.5 mm in papillae after one year of follow-up. In contrast, Tsuda et al¹⁶ observed papillae filled with the Jemt's index²³ in 50% out of 80% of the sites assessed, relating the good results with the bone graft technique associated with connective tissue graft. Raes et al²⁴ found stability of papillae, corroborating the data obtained by Alberti et al.³⁹ On the other hand, the study by Brown et al¹⁹ revealed an increase in the height of the papillae, with changes in the Jemt's index²³ of 2 (85%) and 3 (24%) in 8 weeks (65%) and one year (43%), respectively. It is worth noting that in the study by Raes et al,²⁴ the gingival biotype of the sample was thick, while in the study by Brown et al¹⁹ the maximum gap was 1.5 mm, with intact alveoli walls. Alberti et al³⁹ reported that temporary adjustment favored papillae preservation.

Factors such as operators, methods for standardization of measures and selection of cases (gingival type, preservation of bone plate, bone thickness, implant-alveolus space, among other requirements) interfere in the results. In their study, Noelken et al³³ justify the maintenance of gingival architecture by a set of measures such as the palatal positioning of implants in relation to the residual alveolus, use of autogenous graft and bone reconstruction technique. According to the authors, these details contribute to yielding minimal inflammatory reactions, thus preventing significant bone resorption and collapse of soft tissues.

Huynh-Ba et al³⁴ report that, despite lack of general consensus, the minimum width of the labial bone plate required for bone maintenance would be around 2 mm. It is known that vestibular bone thickness interferes in the maintenance of vestibular bone crest vertical dimension. Also according to these authors, the use of graft would be justifiable due to compensation of the bone resorption expected, especially in the anterior region, which in most cases is not compatible with the bone volume recommended.

Table 1 - Summary of some articles on immediate implant and provisionalization.

Author/ year	Type of study	Follow-up time	Sample	Material and methods	Type of assessment
Kan et al ¹¹ 2003	Prospective	1 year	35 patients 35 implants	Immediate implant + provisionalization	Clinical and radiographic assessment pre, trans and postoperatively
Cornelini et al ³² 2005	Series of cases	1 year	22 implants 22 patients	Temporary/immediate implant with flap + collagen membrane defects larger than 2 mm	Clinical assessment of probing insertion, buccal gingival margin position, papilla position. Radiographic assessment
Ferrara et al ²⁹ 2006	Series of cases	4 years	30 implants 30 patients	Temporary/immediate implant in intact alveoli + autograft filling the gap	Radiographic and photographic assessment; 10-point scale to assess patient's satisfaction
Cooper et al ⁷ 2010	Prospective multicentric	12 months	139 patients 157 implants	Healed ridge X non-grafted fresh alveoli	Radiographs and photographs
Tsuda et al ¹⁶ 2011	Series of cases	1 year	10 patients 10 implants	Xenogeneic graft in the space between alveolar wall and implant + connective tissue graft	Clinical and radiographic assessment
Kan et al ⁵ 2011	Prospective	2 to 8 years, mean of 4 years	35 patients 35 implants	Implant + immediate provisionalization	Clinical and radiographic assessment pre, trans and postoperatively
Raes et al ²⁴ 2011	Clinical trial	52 months	39 patients 39 implants	Immediate implants (ITT) - 16 patients X Conventional implants (CIT) -23 patients without graft	Study models, photographs and radiographs
Galluci et al ²⁶ 2011	Prospective	2 years	20 patients 20 implants	Implant in healed ridge	Study models, photographs and radiographs
Brown et al ¹⁹ 2011	Case report	1 year	27 patients 27 implants	Immediate implant with platform angled at 12° + Temporary implant without graft	Study models, photographs and radiographs
El-Chaar et al ²⁰ 2011	Retrospective	Mean of 23 months	69 patients 162 implants	Immediate implant and immediate provisionalization without graft	Clinical and radiographic assessment
Becker et al ²⁷ 2011	Retrospective	1 year	100 implants 100 patients	Temporary/immediate implant without graft -Minimum Torque of 15 N - Minimum of 3 mm of bone around the apex of the implant	Clinical assessment

Results	Conclusions
<ul style="list-style-type: none"> · 0.55 ± 0.53 mm loss of buccal marginal gingiva · 0.53 ± 0.39 mm loss of mesial papilla · 0.39 ± 0.40 mm loss of distal papilla 	<p>Despite the changes in bone and gingival levels, patients were satisfied</p>
<ul style="list-style-type: none"> · Radiograph showed bone loss of 0.5 mm after 12 months · Gingival loss of 0.75 mm when compared to adjacent teeth · Jemt's index score 2 (61%) and 3 (39%) 	<p>Immediate implant proved to be safe and predictable. The success rate and clinical/radiographic results were comparable to the standard protocol</p>
<ul style="list-style-type: none"> · Success rate of implants: 93.93% · No loss of bone or papillae · Mean of esthetic score of 9.3 ± 0.65 after 4 years 	<p>The cosmetic results were satisfactory, without papilla or bone loss at 6 months and after 4 years</p>
<ul style="list-style-type: none"> · Fresh alveoli gain of 1.3 mm in the first bone-implant contact · Healed ridge, loss of 0.4 mm in the first bone-implant contact · Buccal gingival margin remained stable, or there was gain of 83% in fresh alveoli and 87% in healed ridges 	<p>Fresh alveoli = best results with increased bone level of 1.30 mm X loss of 0.40 mm in healed ridge</p>
<ul style="list-style-type: none"> · Radiograph showed gain of 0.1 mm in the first bone-implant contact · Analysis of study models showed buccal gingival margin recession of 0.05 mm · Jemt's papillary index: more than 50% of papillae filled 	<p>Ideal implant placement + bone grafts. Connective tissue graft favors esthetic results, minimizing risks of recession</p>
<ul style="list-style-type: none"> · Thick biotype showed buccal margin recession of 0.56 mm, while thin biotype showed gingival recession of 1.5 mm 	<p>Thick tissue biotype showed greater stability of buccal margins The effect of gingival biotype seems to be limited to the buccal gingiva, not influencing the levels of papilla and proximal bone crest</p>
<ul style="list-style-type: none"> · After 1 year, the papillae were stable · First bone-implant contact of 0.85 mm for ITT and 0.65 mm for CIT · Only 7% of cases presented advanced buccal gingival recession in ITT, whereas there was significant recession of 1 mm in CIT 	<p>Flapless surgery (IIT) induced less gingival recession</p>
<p>Papillary height, buccal gingiva, width of keratinized mucosa and bone crest level were assessed. Papillae and buccal recession increased after final crown placement, with stability after 1 and 2 years</p>	<p>Papillae and buccal gingival margin recession increased. Stability after 1 and 2 years</p>
<ul style="list-style-type: none"> · Gain of 0.78 mm in bone level at the first bone-implant contact · Gain of 0.2 mm in the buccal gingival margins · Increased papillae. Improvement of Jemt's index of 2 (85%) and 3 (24%) after 8 weeks for 2 (65%) and one year for 3 (43%) 	<p>Platform format favored esthetics. Gain in bone level and gingival margins, increased vestibular papillae</p>
<p>Success rate of 98.77%</p>	<p>Survival rates comparable to those reported with late-loading implants</p>
<ul style="list-style-type: none"> · Success rate according to Albrektsson's criteria: 99% · Minimal gingival recession 	<p>Immediate implants with provisionalization can be effective, but at least 3 mm of residual alveolar bone must be observed around the apex of the implant. Primary stability should be assessed, although there is no consensus regarding the minimum required torque</p>

Author/year	Type of study	Follow-up time	Sample	Material and methods	Type of assessment
Cosyn et al ³⁷ 2011	Prospective	3 years	25 patients 25 implants	Temporary/immediate implant minimum flap + xenogeneic graft filling the gap	<ul style="list-style-type: none"> · Esthetic assessment with PES and WES indexes · Radiographic standardization through occlusal feedback
Levin et al ²⁸ 2011	Retrospective	3 to 18 months	23 patients 30 implants	Allograft + collagen membrane	Radiographic assessment at implant placement and 12 weeks after the final prosthesis
Raes et al ³⁵ 2012	Prospective	52 months	48 patients 48 implants	Fresh alveoli without graft (IIT) X healed ridges without graft (CIT) X implants 4 months after graft with bovine biomaterial (GIT)	<ul style="list-style-type: none"> · Radiographic assessment (paralleling technique with device to standardize the position) · Assessment of patient's satisfaction through questionnaires (OHIP) · Assessment of pink esthetics through PES, and white esthetics through WES
Malchiodi et al ³⁶ 2012	Prospective	3 years	58 patients 58 implants	Filling the gap with autogenous bone collected through milling	Clinical and radiographic assessment in 3 stages: (surgery, six months and 2 years later)
Spinato et al ⁴⁰ 2012	Retrospective	32 months	41 patients 45 implants	Filling the space between implant and alveolar wall when greater than 2 mm with autogenous bone or bone substitutes (xenogeneic, allogeneic), or associations	Clinical and radiographic assessment in 3 stages: At implant placement, 6 months later and at the last visit
McAllister et al ³⁸ 2012	Prospective	24 months	55 patients 60 implants	<ul style="list-style-type: none"> · Use of thread design implant (Nobel) that favors increased primary stability · Minimum insertion torque of 35 N 	Clinical and radiographic assessment at T ₀ , 3 months, 6 months, 12 months and 24 months
Alberti et al ³⁹ 2012	Prospective	1 year	70 patients 70 implants	<ul style="list-style-type: none"> · 25 implants with provisionalization in fresh alveoli X 45 single implants in healed ridges · In cases of fresh alveoli, surgery was flapless. In healed ridges, surgery was with buccal mucoperiosteal flap · Minimum torque of 40 N · Gaps larger than 2 mm were filled with particulate bone · Temporary implants were made within a distance not greater than 5 mm between proximal bone crest and the contact point · After 8 weeks, adjustments were made in the crowns so as to favor esthetics of buccal margin gingiva 	<ul style="list-style-type: none"> · Clinical and radiographic assessment of patient's satisfaction through questionnaires · Use of a device to standardize the positioning of radiographs · Radiographic assessment at: T₀ (8 weeks) 6 months and 1 year

Results	Conclusions
<ul style="list-style-type: none"> · Mesial bone loss of 1.13 mm and distal of 0.86 mm in 3 years · Tendency towards papilla regrowth between 1 and 3 years · Mesial papilla recession of 0.05 mm, distal of 0.08 mm and buccal recession of 0.34 mm · Only 8% of cases showed buccal recession greater than or equal to 1 mm 	<p>A careful selection of cases excluding thin tissue biotype and buccal bone defect is essential to yield good results. A tendency towards papilla regrowth was identified along 3 years, thus demonstrating that they are not completely reshaped after one year</p>
<ul style="list-style-type: none"> · Implant survival rate of 100% · Bone maintenance of 83% 	<p>Bone maintenance of 83%</p>
<ul style="list-style-type: none"> · After 1 year, stability of buccal marginal gingiva in IIT and CIT, recession of 1 mm in GIT · After 52 months, buccal recession in 7% of IIT cases, 43% of CIT cases, and 22% of GIT cases 	<p>It is important to carefully select the method of treatment. The quality of life of patients who receive immediate implants in esthetic areas changes significantly</p>
<ul style="list-style-type: none"> · There was no significant crest remodeling within 3 years, but there was buccal recession · Gingival marginal level ranged between 0.5 and 0.6 mm, 40.6% showed no discrepancy while 12.5% showed variation greater than or equal to 1.5 mm 	<p>Increased distance between proximal bone crest and the contact point may impair soft tissue esthetics. Maintenance of hard and soft tissues around the implant are the key to obtaining satisfactory final results, for which correct implant positioning is necessary</p>
<ul style="list-style-type: none"> · There was no difference between groups with regard to implant stability, bone level and soft tissue level · Bone loss of 0.65 mm in 6 months, and 0.94 mm at T₂ in both groups · Presence of papillae in 93% of cases at T₁, in both groups, and 95% at T₂ 	<p>Provided that tissue biotype is thick, there are no significant differences between the materials used for filling the implant-alveolus space</p>
<ul style="list-style-type: none"> · Survival rate of 98.3% · Marginal bone loss of 0.22 mm ± 1.3 mm in 1 year · Bone gain of 0.12 mm ± 0.77 between 12-24 months · Papillary increase after 2 years 	<p>The result obtained after 2 years demonstrates that immediate implant is safe and that other factors such as sufficient bone volume and minimum insertion torque of 35 N should be considered. Implant design favors primary stability.</p>
<ul style="list-style-type: none"> · Survival rate of 100% · All papillae were preserved · No evidence of gingival recession · Patients reported high satisfaction 	<p>Inclusion criteria such as the use of long implants, treated surface, primary stability and implant positioning influence treatment outcomes. Adjustments to the temporary implant seem to favor papilla preservation</p>

Conclusions

1. There is no consensus among authors about the surgical technique, the graft materials, the type of implant and prosthetic procedure regarding immediate implant placement and provisionalization. However, the immediate implant technique seems to yield satisfactory clinical and esthetic results;
2. Tissue biotype influences the esthetics of implant therapy, especially the peri-implant mucosa. Thin biotype had greater susceptibility to recession;
3. Tissue biotype showed little influence over the height of the interproximal papilla;

4. Filling the gap with autogenous bone graft contributed to maintaining the structures around the implant. However, we can not affirm that some graft materials are superior to others;
5. Subepithelial connective tissue graft positively influences the level of buccal marginal mucosa;
6. Further long-term controlled clinical trials are needed to determine the real influences of intrinsic and extrinsic factors over the morpho-esthetic-functional behavior of peri-implant tissue in immediate implant placement with provisionalization.

REFERENCES

1. Smith DE, Zarb GA. Criteria for success of osseointegrated endosseous implants. *J Prosthet Dent.* 1989;62(5):567-72.
2. Kan JY, Rungcharassaeng K, Morimoto T, Lozada J. Facial gingival tissue stability after connective tissue graft with single immediate tooth replacement in the esthetic zone: consecutive case report. *J Oral Maxillofac Surg.* 2009;67(11 Suppl):40-8.
3. Becker W. Immediate implant placement: diagnosis, treatment planning and treatment steps/or successful outcomes. *J Calif Dent Assoc.* 2005;33(4):303-10.
4. Barreto M, Fransischone CE, Nary Filho H. Two prosthetic crowns supported by a single implant: an esthetic alternative for restoring the anterior maxilla. *Quintessence Int.* 2008;39(9):717-25.
5. Kan JYK, Rungcharassaeng K, Lozada JL, Zimmerman. Facial gingival tissue stability following immediate placement and provisionalization of maxillary anterior single implants: a 2- to 8-year follow-up. *Int J Oral Maxillofac Implants.* 2011 ;26(1):179-87.
6. Buser D, Dahlin C, Schenk RK. Guided bone regeneration in implant dentistry. Chicago: Quintessence; 1994.
7. Buser D, Martin W, Belser UC. Optimizing esthetics for implant restorations in the anterior maxilla: anatomic and surgical. *Int J Oral Maxillofac Implants.* 2004;19(suppl):43-61.
8. Schincaglia GP, Nowzari H. Surgical treatment planning for the single-unit implant in aesthetic areas. *Periodontol* 2000. 2001;27:162-82.
9. Chen ST, Buser D. Clinical and esthetic outcomes of implants placed in postextraction sites. *Int J Oral Maxillofac Implants.* 2009;24(suppl):186-217.
10. Wöhrle PS. Single-tooth replacement in the aesthetic zone with immediate provisionalization: fourteen consecutive cases reports. *Pract Periodontics Aesthet Dent.* 1998;10(9):1107-14; quiz 1116.
11. Kan JYK, Rungcharassaeng K, Lozada J. Immediate placement and provisionalization of maxillary anterior single implants: 1-year prospective study. *Int J Oral Maxillofac Implants.* 2003;18(1):31-9.
12. De Rouck T, Collys K, Cosyn J. Immediate single-tooth implants in the anterior maxilla: a 1-year case cohort study on hard and soft tissue response. *J Clin Periodontol.* 2008;35(7):649-57.
13. Rosa JCM, Rosa DM, Zardo CM, Rosa ACPO, Canullo L. Restauração dentoalveolar imediata pós-exodontia com implants platform switching e enxertia. *ImplantNews.* 2009;6(4):381-5.
14. Kan JYK, Rungcharassaeng K. Immediate placement and provisionalization of maxillary anterior single implant: A surgical and prosthodontic rationale. *Pract Periodontics Aesthet Dent.* 2000;12:817-824.
15. Miyamoto Y, Obama T. Dental Cone Beam Computed Tomography analyses of postoperative labial bone thickness in maxillary anterior implants: comparing immediate and delayed implant placement. *Int J Periodontics Restorative Dent.* 2011;31(3):215-25.

16. Tsuda H, Rungcharassaeng K, Kan JYK, Roe P, Lozada JL, Zimmerman G. Peri-implant tissue response following connective tissue and bone grafting in conjunction with immediate single-tooth replacement in the esthetic zone: a case series. *Int J Oral Maxillofac Implants.* 2011;26(2):427-36.
17. Cooper LF, Raes F, Reside GJ, Garriga JS, Tarrida LJ, Wiltfang J, et al. Comparison of radiographic and clinical outcomes following immediate provisionalization of single-tooth dental implants placed in healed alveolar ridges and extraction sockets. *Int J Oral Maxillofac Implants.* 2010;25(6):1222-32.
18. Kois JC, Kan JYK. Predictable peri-implant gingival esthetics: surgical and prosthodontics rationales. *Pract Proced Aesthet Dent.* 2001;13(9):691-8; quiz 700, 721-2.
19. Brown SDK, Payne AGT. Immediately restored single implants in the aesthetic zone of the maxilla using a novel design:1-year report. *Clin Oral Implants Res.* 2011;22(4):445-54.
20. El-Chaar ES. Immediate placement and provisionalization of implant-supported, single-tooth restorations: a retrospective study. *Int J Periodontics Restorative Dent.* 2011 ;31(4):409-19.
21. Rungcharassaeng K, Lozada JL, Kan JYK, Kim JS, Campagni WV, Munoz CA. Peri-implant tissue response of immediately loaded threaded HA-coated implants: 1-year results. *J Prosthet Dent.* 2002;87(2):173-81.
22. Tomasi C, Sanz M, Cecchinato D, Pjetursson B, Ferrus J, Lang NP, et al. Bone dimensional variations at implants placed in fresh extraction sockets: a multilevel multivariate analysis. *Clin Oral Implants Res.* 2010;21(1):30-6.
23. Jemt T. Regeneration of gingival papillae after single-implant treatment. *Int J Periodontics Restorative Dent.* 1997;17(4):326-33.
24. Raes F, Cosyn J, Crommelinck E, Coessens P, De Bruyn H. Immediate and conventional single implant treatment in the anterior maxilla: 1-year results of a case series on hard and soft tissue response and aesthetics. *J Clin Periodontol.* 2011 ;38(4):385-94.
25. Herberer S, Al-Chawaf B, Jablonski C, Nelson JJ, Lage H, Nelson K. Healing of ungrafted and grafted extraction sockets after 12 weeks: a prospective clinical study. *Int J Oral Maxillofac Implants.* 2011;26(2):385-92.
26. Gallucci GO, Grütter L, Chuang SK, Belser UC. Dimensional changes of peri-implant soft tissue over 2 years with single-implant crowns in the anterior maxilla. *J Clin Periodontol.* 2011;38(3):293-9.
27. Becker CM, Wilson TG Jr, Jensen OT. Minimum criteria for immediate provisionalization of single-tooth dental implants in extraction sites: a 1-year retrospective study of 100 consecutive cases. *J Oral Maxillofac Surg.* 2011;69(2):491-7.
28. Levin B. Immediate temporization of immediate implants in the esthetic zone: evaluating survival and bone maintenance. *Compend Contin Educ Dent.* 2011;32(4):52-6, 58-60, 62.
29. Ferrara A, Galli C, Mauro G, Macaluso GM. Immediate provisional restoration of postextraction implants for maxillary single-tooth replacement. *Int J Periodontics Restorative Dent.* 2006;26(4):371-7.
30. Funato A, Salama MA, Ishikawa T, Garber DA, Salama H. Timing, positioning, and sequential staging in esthetic implant therapy: a four-dimensional perspective. *Int J Periodontics Restorative Dent.* 2007;27(4):313-23.
31. Grunder U. Crestal ridge width changes when placing implants at the time of tooth extraction with and without soft tissue augmentation after a healing period of 6 months: report of 24 consecutive cases. *Int J Periodontics Restorative Dent.* 2011;31(1):9-17.
32. Cornellini R, Cangini F, Covani U, Wilson TG Jr. Immediate restoration of implants placed into fresh extraction sockets for single-tooth replacement: a prospective clinical study. *Int J Periodontics Restorative Dent.* 2005;25(5):439-47.
33. Noelken R, Kunkel M, Wagner W. Immediate implant placement and provisionalization after long-axis root fracture and complete loss of the facial bony lamella. *Int J Periodontics Restorative Dent.* 2011;31(2):175-83.
34. Huynh-Ba G, Pjetursson BE, Sanz M, Cecchinato D, Ferrus J, Lindhe J, et al. Analysis of the socket bone wall dimensions in the upper maxilla in relation to immediate implant placement. *Clin Oral Implants Res.* 2010;21(1):37-42.
35. Raes F, Cosyn J, De Bruyn. Clinical, aesthetic, and patient-related outcome of immediately loaded single implants in the anterior maxilla: a prospective study in extraction sockets, healed ridges, and grafted sites. *Clin Implant Dent Relat Res.* 2012 jan 17. [Epub ahead of print].
36. Malchiodi L, Cucchi A, Ghensi P, Nocini PF. Evaluation of the esthetic results of 64 nonfunctional immediately loaded postextraction implants in the maxilla: correlation between interproximal alveolar crest and soft tissues at 3 years of follow-up. *Clin Implant Dent Relat Res.* 2013;15(1):130-42.
37. Cosyn J, Eghbali A, De Bruyn H, Colls K, Cleymaet R, De Rouck, T. Immediate single-tooth implants in the anterior maxilla: 3-year results of a case series on hard and soft tissue response and aesthetics. *J Clin Periodontol.* 2011;38(8):746-53.
38. McAllister BS, Cherry JE, Kolinski ML, Parrish KD, Pumphrey DW, Schoroering RL. Two-year evaluation of a variable-thread tapered implant in extraction sites with immediate temporization: a multicenter clinical trial. *Int J Oral Maxillofac Implants.* 2012;27(3):611-8.
39. Alberti L, Donnini F, Alberti C, Camerino M, Sgaramela N, Muzio L. Clinical and radiologic evaluation of 70 immediately loaded single implants in the maxillary esthetic zone: preliminary results after 1 year of functional loading. *Int J Oral Maxillofac Implants.* 2012 ;27(1):181-6.
40. Spinato S, Agnini A, Chiesi M, Agnini A, Wang H. Comparison between graft and no-graft in an immediate placed and immediate nonfunctional loaded implant. *Implant Dent.* 2012;21(2):97-103.