

Immediate loading on reconstructed maxilla with alogenous bone by means of guided surgery: A case report

Jefferson **TRAEBERT***

Wilson **ANDRIANI JÚNIOR****

José Nilo de Oliveira **FREIRE*****

Abstract

Introduction: Implant placement by means of virtual planning and guided surgery can facilitate and optimize surgery, increasing predictability of final outcomes in areas with severe bone resorption. **Objective:** To report a case of guided surgery employed for immediate implant placement in edentulous maxilla previously reconstructed with allograft. **Methods:** Proper care and major advantages of the technique were discussed.

Keywords: Dental implant. Allograft. Guided surgery. Immediate loading.

» The patient displayed in this article previously approved the use of her facial and intraoral photographs.

How to cite this article: Traebert J, Andriani Júnior W, Freire JNO. Immediate loading on reconstructed maxilla with alogenous bone by means of guided surgery: A case report. Dental Press Implantol. 2013 July-Sept;7(3):90-8.

» The authors inform they have no associative, commercial, intellectual property or financial interests representing a conflict of interest in products and companies described in this article.

Contact address

Jefferson Traebert
Rua Frederico Bunn, 105, Biguaçu/SC — Brazil - CEP: 88160-000
E-mail: jefferson.tarebert@gmail.com

Submitted: July 06, 2013
Revised and accepted: August 06, 2013

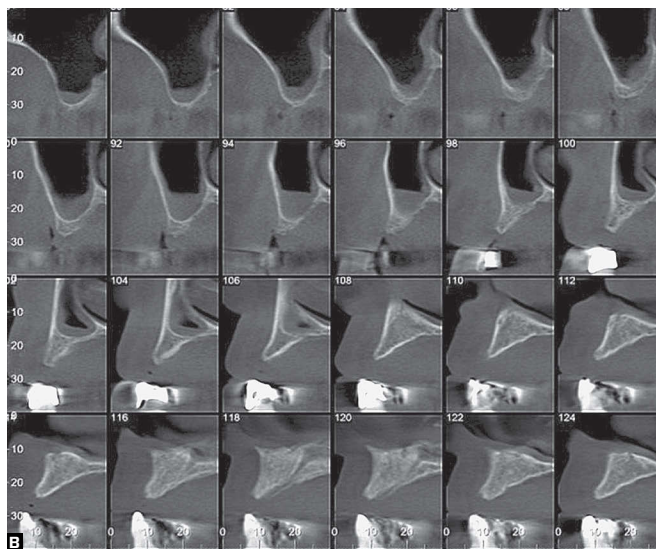
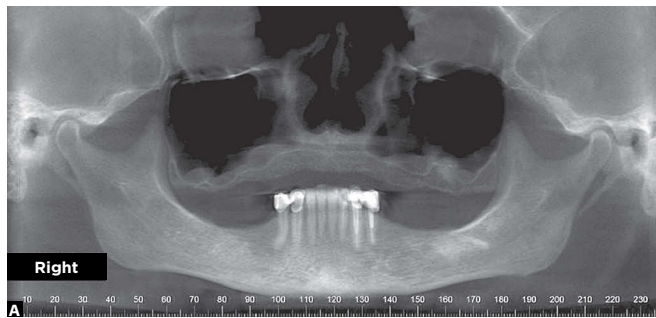
*Professor, Postgraduate course in Health Sciences, University of Southern Santa Catarina.

**Professor, Specialization in Implantodontics, ABCD/Florianópolis and Federal University of Santa Catarina (UFSC).

***Professor, Specialization in Implantodontics, ABCD/Florianópolis.

Introduction

According to data provided by the Brazilian Ministry of Health,¹ the prevalence of denture wearers in Brazil is of 63% among patients aged between 65 and 74 years old, with an average need for implant of 17% in at least one of the arches. The high rates of edentulism are a challenge for Dentistry, given that rehabilitation of esthetics and function of edentulous patients increases their self-esteem and improves their quality of life.²



Different techniques have been developed for the total rehabilitation of edentulous patients through Implantology and Prosthodontics. Implant placement through guided surgery is made feasible by computed tomography (CT) scans and prototypes as well as pre-planned surgical guides. For this reason, it facilitates and optimizes surgery and, as a result, increases the predictability of final outcomes. However, edentulism is often associated with severe bone resorption, and demands proper planning that includes reconstruction of large areas of the arches prior to implant and prosthesis placement.

This paper aims at reporting a case of guided surgery used for immediate implant placement in edentulous maxilla with severe bone resorption, previously reconstructed with allograft.

Case report

The patient was 59 year old, female, with chief complaint of little stability of complete upper prosthesis. After anamnesis, physical and clinical examination, as well as preliminary X-ray scrutiny, a cone-beam CT scan was requested and revealed severe maxillary bone resorption (Fig 1).

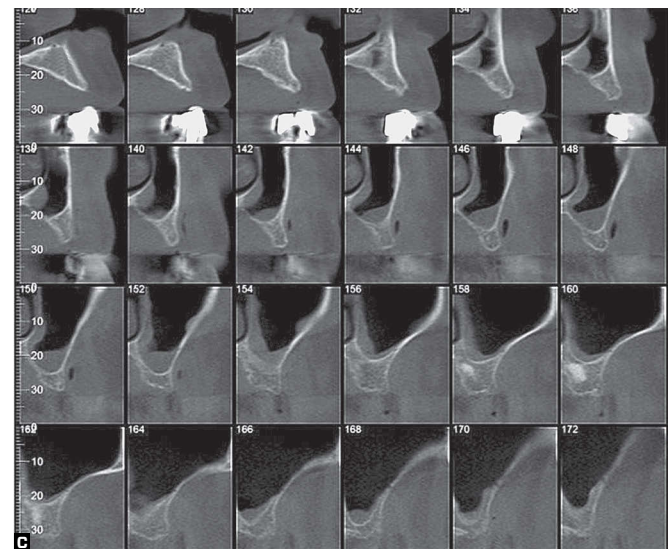


Figure 1 - Cone-beam CT- panoramic (A) and transverse (B, C) slices.

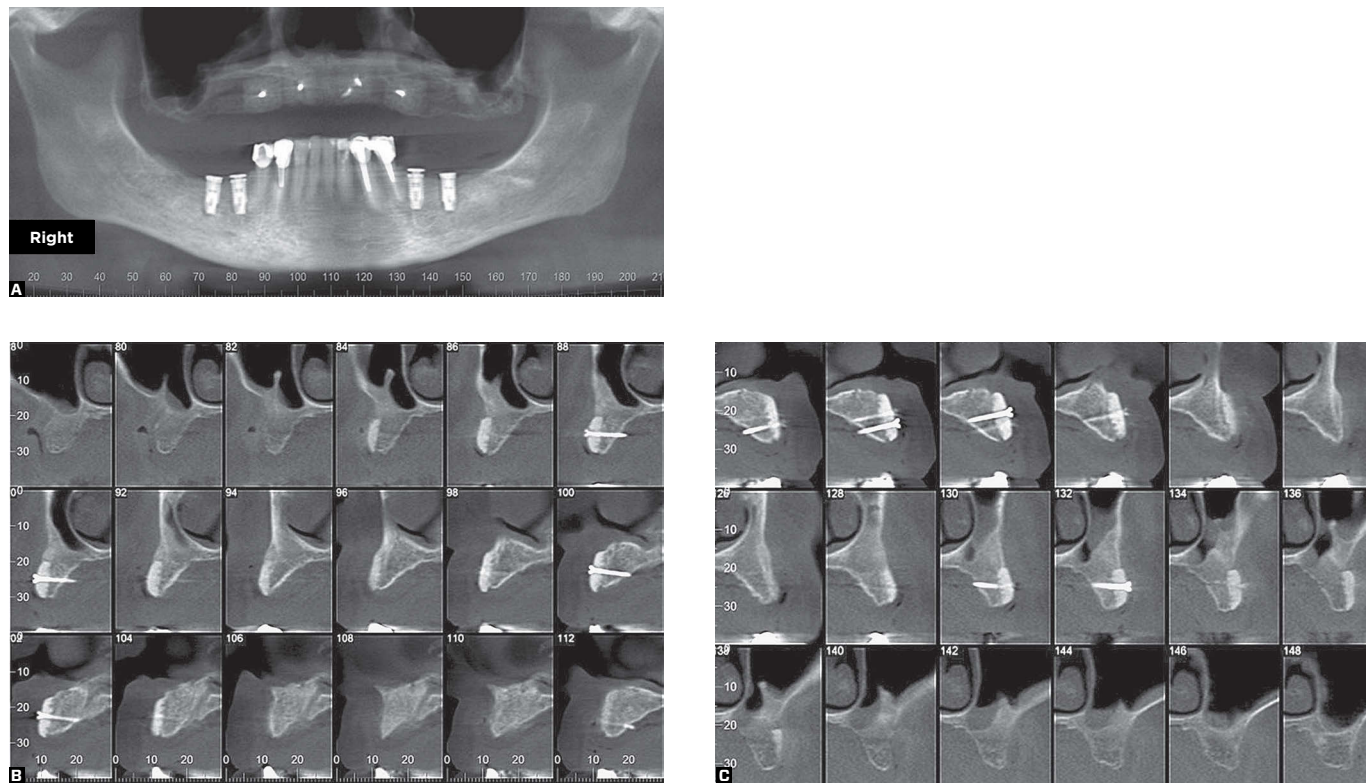


Figure 2 - Cone-beam CT - panoramic (A) and transverse (B, C) slices six months after the surgical reconstruction of the maxilla with allograft bone blocks.

After CT scan analysis, block bone grafting was performed to reconstruct patient's maxilla. Implant placement was carried out after six months. Further planning included placement of an upper immediate denture through computer-guided surgical technique.

The patient was non-smoker and did not make routine use of medication. The clinical examination revealed that the prosthesis was well placed, despite little stability. She had healthy gingival and mucosal tissue. Complete blood count, coagulation and blood glucose tests revealed no alterations. Oral antimicrobial and non-steroidal anti-inflammatory drugs were prescribed during the preoperative phase.

Bone grafting was performed in the operating room at the Brazilian Association of Dental Surgeons / Florianópolis,

under local anesthesia with intravenous sedation, supervised by an anesthesiologist. Four blocks of allograft bone from a bone bank (UNIOSS, Marília, São Paulo, Brazil) were used and fixed with bone graft screws.

A new cone-beam CT scan was taken six months after surgery and revealed proper integration of the blocks to the remaining jawbone (Fig 2).

To proceed with immediate loading plan treatment, a virtual surgical planning was performed using the Dental Slice software (Bioparts, Brasília, Brazil) with subsequent preparation of the prototyped guide (Fig 3) for two different purposes: to function as a surgery guide and as a base for immediate implant-supported denture construction (Fig 4).

Guided surgery was performed as planned after the dental prosthesis was manufactured. All preoperative procedures were performed, including prescription of oral antimicrobial and anti-inflammatory drugs.

After infiltrative administration of local anesthesia, the vertical dimension of occlusion was recorded in centric relation with the surgical guide within the patient's mouth (Fig 5) so as to guide the subsequent placement of immediate full denture.

The fixing screws of the allogeneous bone blocks were placed, and small incisions were made for their removal (Fig 6).

Subsequently, three fastening screws 2 mm in diameter and 8 mm in length were installed to guide stabilization: one in the anterior region and two in the premolar region (Fig 7). Implant placement sites were opened with a rotational circular scalpel at 80 rpm. Surgical instrumentation was performed by observing the progressive sequence of cutters, according to the surgical protocol, until it reached a diameter of 3.3 mm (Fig 8).

Internal-hexagon implants 3.75 mm in diameter and 15 mm in length were used in the cuspid area, whereas

implants 3.75 mm in diameter and 13 mm in length were installed in the region of lateral incisors and second premolars (Fig 9).

The surgical guide was removed and the prosthetic components (microunits) were placed, five angled at 17° and one straight (tooth #25) (Fig 10). They were previously selected during the virtual planning and used to construct the prosthesis.

The pre-made full denture was installed with the use of temporary metal copings embedded in acrylic resin (Fig 11).

Discussion

Proper treatment planning relies on satisfactory diagnosis. Patient's detailed clinical and physical examination is essential. Volumetric computed tomography, study models and surgical guides are imperative, given that enable correct positioning of implants and a better distribution of mechanical forces.³

In the case reported herein, the areas with severe maxillary bone resorption were reconstructed with allograft. Autogenous bone is the first choice of treatment for reconstruction of severe alveolar bone defect.

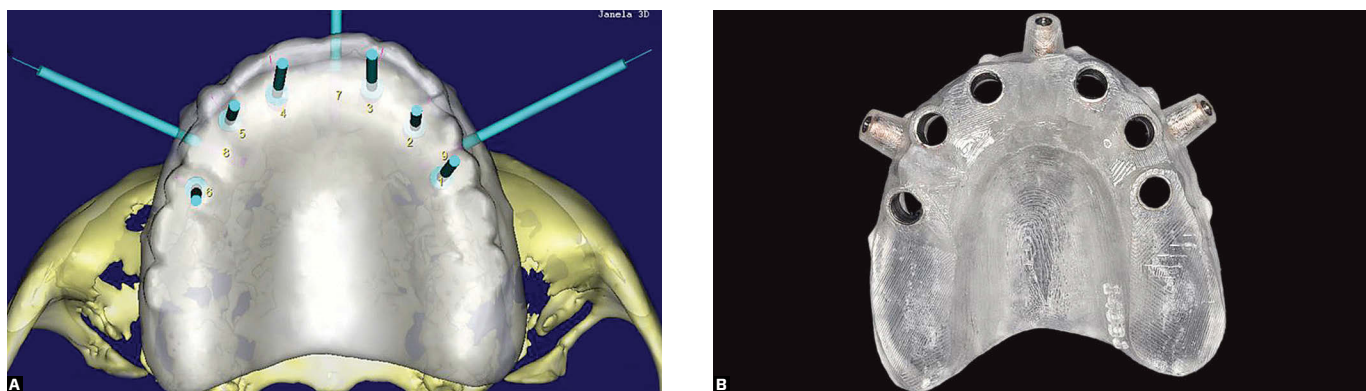


Figure 3 - Planning in a virtual environment. Note the axial positioning of implants in relation to the final prosthesis – 3D image of the Dental Slice software (Bioparts, Brasília, Brazil) (A) and prototype (B).

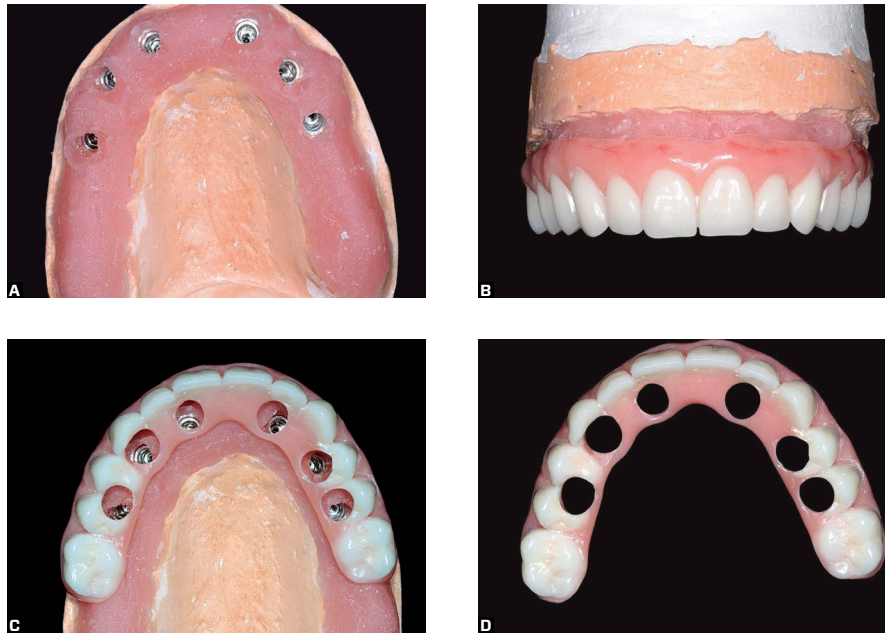


Figure 4 - Analog working models (A) and total prosthesis (B, C and D).

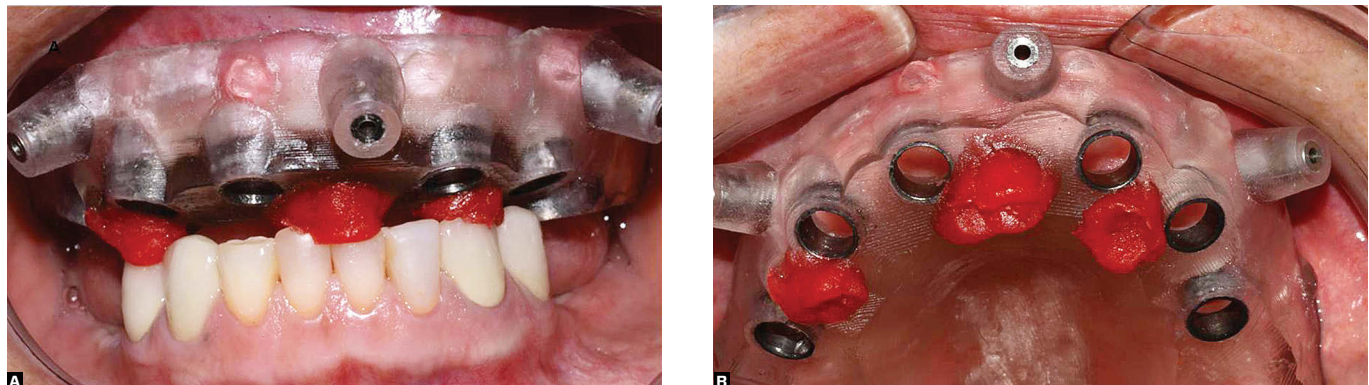


Figure 5 - Clinical vestibular (A) and occlusal view (B) of the prototyped guide in the mouth after bite registration in centric relation.

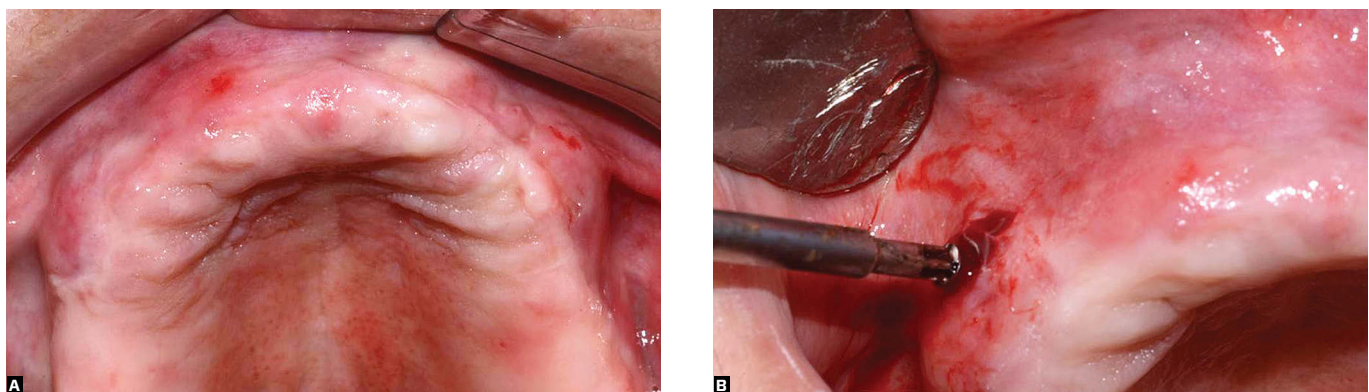


Figure 6 - Overview of the reconstructed maxilla (A) and incision to remove the fastening screws of the allograft bone blocks (B).

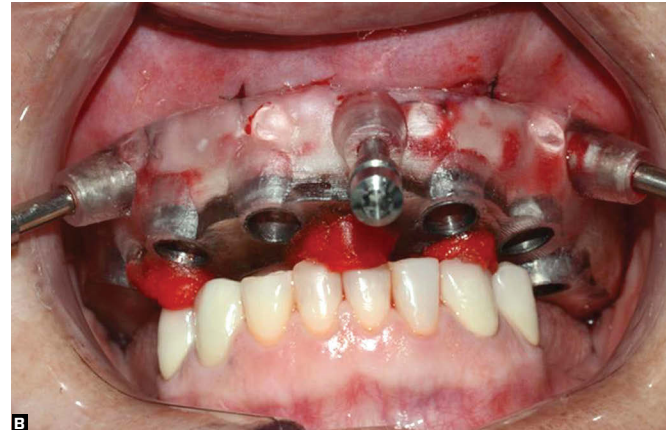
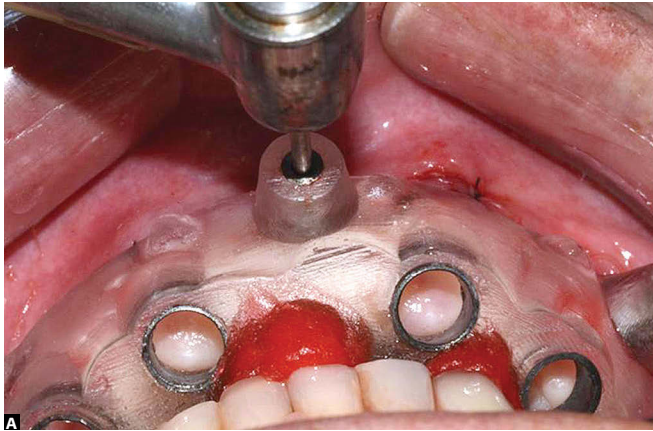


Figure 7 - Fastening screws installation (A). Guide stabilization with three fastening screws (B).

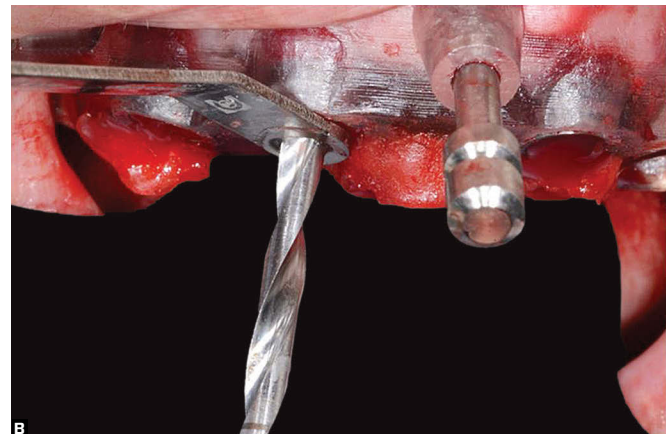
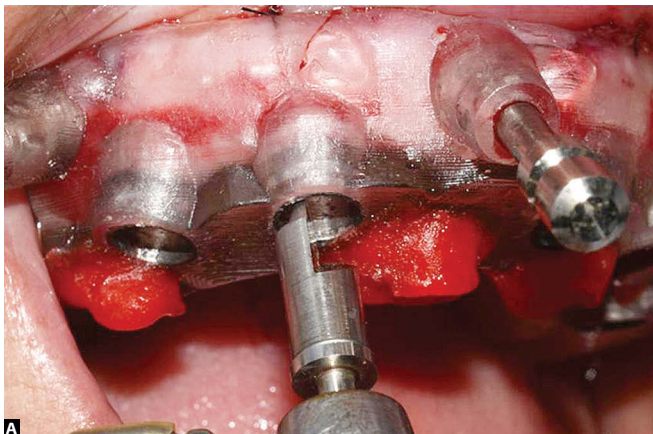


Figure 8 - Opening with a rotational circular scalpel (A) and sequence of cutters (B).

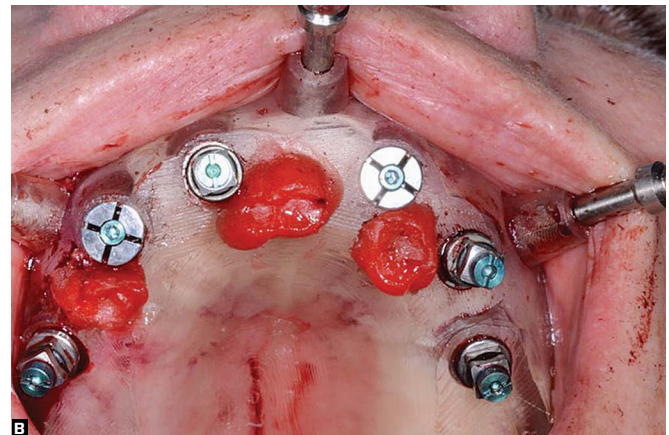
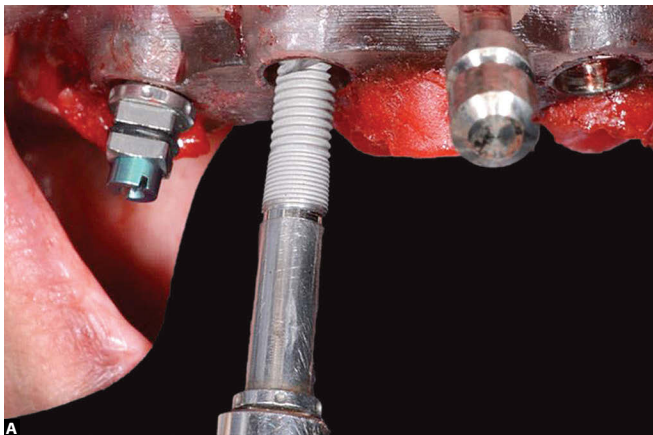


Figure 9 - Implant placement (A). Installed implants (B).

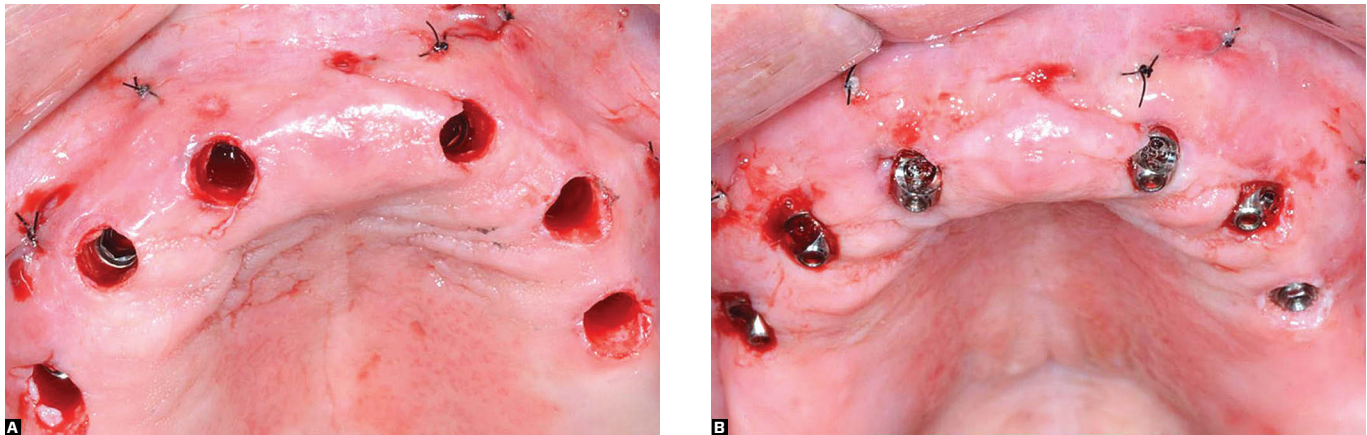


Figure 10 - Installed implants with the guide removed (A). Installed prosthetic components (B).

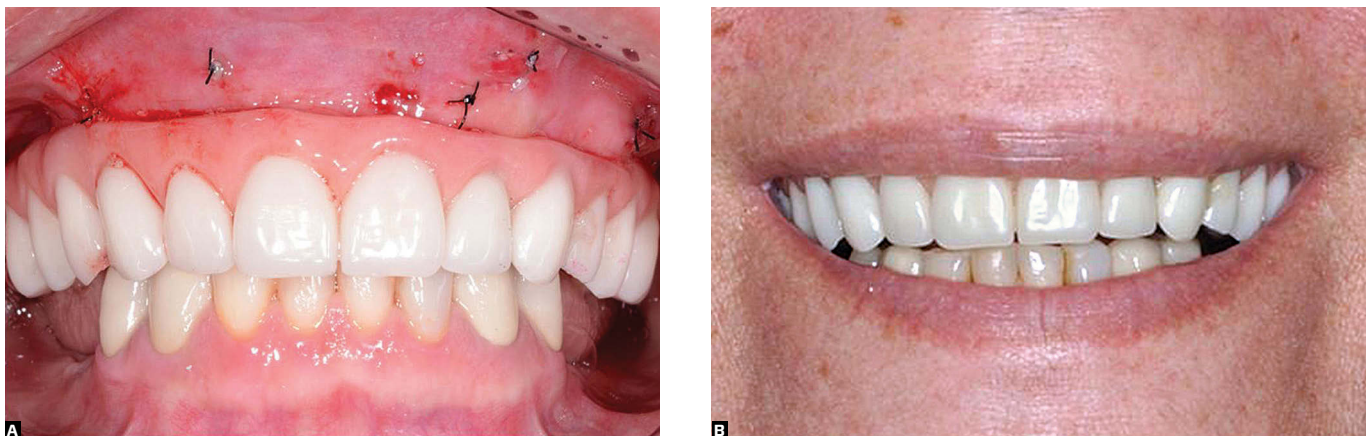

Figure 11 - Prosthesis installed right after surgery (A) and 20 days after surgery (B).

It results in more predictable outcomes, prevents disease transmission and offers full histocompatibility.⁴ However, the need for a second bone harvesting site has increased the interest in procedures that reduce the consequences inherent to the donor area. In this context, allograft bone obtained from a donor is considered a feasible alternative. With the emergence of tissue banks and the expansion and improvements in preservation techniques, there is increased availability of allograft bone tissue, which constitutes an important aid for severe bone resorption cases.⁵

The advantages of using allograft bone include increased availability of tissue and elimination of harvesting surgical sites, with consequent prevention of morbidity in the donor site and possible reduction in treatment costs.⁶ As for disadvantages, they include the risk of disease transmission and potential antigenicity, which are complications that can be controlled by processing methods. The risk of infection can be reduced by serological testing of donors, dispose of material that produces positive bacteriological culture, and manipulation of bone graft under aseptic and sterilization conditions.⁷

A limited number of studies has focused on alveolar ridge reconstruction with allograft bone. In a bibliographic review, Levandowski et al⁵ showed that the clinical results are satisfactory, but the literature does not show sufficient methodological quality to justify the use of allograft bone when autogenous bone is available. Even so, the authors concluded that bone allograft undergoes biological changes that are qualitatively similar to autogenous bone grafts, but they occur more slowly. Moreover, they showed that the time for bone allograft incorporation and remodeling can take from 40 to 90 days for small grafts and can be indeterminate for large grafts.

On the other hand, cone beam computed tomography images processed in computer software enable virtual surgical planning, making it possible to visualize, three-dimensionally, the relationship between implants and arch anatomy.⁸ When associated with stereolithography, CBCT images enable prototyping and the fabrication of surgical guides through computational modeling. The use of prototypes accurately reproduces the anatomy of the area to be rehabilitated, thus facilitating the surgical technique and anticipating problems and solutions with more predictable results.⁹

Associating a surgical guide used for diagnosis with implant placement is highly advantageous and improves final results.¹⁰ The guide provides accurate information not only about the buccolingual inclination of the planned implant, but also about bone size and anatomical features.¹¹ Because the surgical planning is computerized in three dimensions, implants can be placed in the exact position, based on the bone structure.

Once treatment plan is established, the surgical guide is made of acrylic, with metal cylinders attached to implant analogs to create a prosthetic model. The cylinders also function as guide points for milling during

implant bed preparation, which allows correct position and inclination. Additionally, the diameter of the guides corresponds to the diameter of the cutters, which leads to a smaller margin of error.¹² The guide is placed in the oral rehabilitation area by means of screw fasteners, allowing surgical stability.

Prototype models have the advantage of providing comfort to the patient during the surgical procedure. This is made possible through virtual guided surgery. The prototyping technique enables guided surgery and optimal implant placement based on the prosthetic planning that results in the immediate installation of a provisional implant-supported prosthesis in the maxilla or mandible⁹. Guided surgery requires minor incisions, providing greater comfort to patients with less postoperative pain and swelling.³

Immediate implant loading is highly advantageous for rehabilitation of edentulous cases. Placement of implants and total prosthesis in one single session is another advantage. In addition to improving patient's self-esteem,² the procedure allows patients to return to their daily activities within a short period of time as a result of esthetic and functional recovery. Furthermore, it reduces healing time, given that no major manipulation procedures of mucosa and periosteum are performed, thus favoring osseointegration.¹³⁻¹⁷ Nevertheless, primary implant stabilization is required, and it is related to implant geometry, bone anatomy and surgical technique.⁹

According to Holcman et al,³ the success rates of immediate implant placement are similar to those of delayed loading after osseointegration. For this reason, and due to treatment predictability, these authors recommend the use of a single-session surgical protocol with the application of immediate load, which simplifies rehabilitation without compromising functional and esthetic results.

Conclusion

The implant method described above proves to be highly advantageous for yielding immediate function and esthetic results. The single-stage surgical protocol and flapless surgical procedure provide greater comfort for the patient during surgery, as well as a more favorable postoperative period.

The use of allograft bone blocks enable high-quality bone structures to receive the implant. This was evidenced by the good primary implant stability achieved. Furthermore, the technique had the advantage of avoiding harvesting of autogenous bone graft, which resulted in lower morbidity risks and consequent increased pre- and post-surgical comfort.

REFERENCES

1. Brasil. Ministério da Saúde. Projeto SB Brasil 2010. Resultados principais. Ministério da Saúde Brasília. Brasília, DF; 2011.
2. Melas F, Marcenes W, Wright PS. Oral health impact on daily performance in patients with implant-stabilized overdentures and patients with conventional complete dentures. *Int J Maxillofac Implants*. 2001;16(5):700-12.
3. Holcman M, Pinto JT, Farina CG, Falsi M, Santos Neto A, Vasconcelos AP, et al. Cirurgia guiada em função imediata: proposta de técnica sem incisão. *Rev Bras Implant*. 2007;13(2):6-9.
4. Vaccaro AR. The role of the osteoconductive scaffold in synthetic bone graft. *Orthopedics*. 2002;25(5 Suppl):s571-8.
5. Levandowski Jr N, Pfeifer AB, Paza AO, Valiati R, Silva MRPB. Utilização do osso alógeno em bloco para aumento de rebordo alveolar: revisão da literatura. *ImplantNews*. 2008;5(1):51-7.
6. Keith JR JD. Localized ridge augmentation with a block allograft followed by secondary implant placement: a case report. *Int J Periodontics Restorative Dent*. 2004;24(1):11-7.
7. Baptista AD, Sorriilha A, Tormes TAM, Abdoune YA, Croci AT, Camargo OP, et al. Estudo histológico dos enxertos ósseos homólogos humanos. *Acta Ortop Bras*. 2003;11(4):220-4.
8. Viana Neto A, Neves PJC, Madruga FATTA, Rocha RS, Carvalho RWF. Cirurgia guiada virtual para reabilitação oral: revisão de literatura e relato de caso. *Rev Cir Traumatol Buco-Maxilo-Fac*. 2009; 9(2):45-52.
9. Thomé G. Planejamento virtual para soluções reais. *ImplantNews*. 2007;4(4):372-5.
10. Bottino MA, Itinoche MK, Buso L, Faria R. Estética com implantes na região anterior. *ImplantNews*. 2006;3(6):560-8.
11. Arita CA. Prótese sobre implante no segmento posterior. *ImplantNews*. 2006;3(4):336-43.
12. Dinato J, Nunes LS. Tratamento protético sobre implante no desdentado total na atualidade. *ImplantNews*. 2006;3(5):452-60.
13. Campos JLG, Chagas JFS, Campos DCF. Guia multifuncional como facilitador na reabilitação com carga imediata em mandíbula: relato de caso. *Rev Bras Implant*. 2006;12(3):22-5.
14. Rosenfeld AL, Mandelaris GA, Tardieu PB. Prosthetically directed implant placement using computer to ensure precise placement and predictable prosthetic outcomes. Part 2: rapid-prototype medical modeling and stereolithographic drilling guides requiring bone exposure. *Int J Periodontics Restorative Dent*. 2006;26:347-53.
15. Balshi SF, Wolfinger GJ, Balshi TJ. Surgical planning and prosthesis construction using computer technology and medical imaging for immediate loading of implants in the pterygomaxillary region. *Int J Periodontics Restorative Dent*. 2006;26(3):239-47.
16. Balshi SF, Wolfinger GJ, Balshi TJ. Surgical planning and prosthesis construction using computer tomography, CAD/CAM technology, and the internet for immediate loading of dental implants. *J Esthet Rest Dent*. 2006;18(6):312-23.
17. Kupeyan HK, Shaffner M, Armstrong J. Definitive CAD/CAM-guided prosthesis for immediate loading of bone-grafted maxilla: a case report. *Clin Implant Dent Relat Res*. 2006;8(3):161-7.