

# Focal osteoporotic bone marrow defect: Concept, diagnosis and osseointegrated implants

**Abstract** / Focal osteoporotic defects in adult patients must be on the list of differential diagnosis of small and medium uni and multicocular radiolucent lesions, especially in the jaw. Clinical and imaginologic diagnoses are safe; however, a biopsy must be performed in case of doubt, in which case the report will include hematopoietically active medullary tissue. Focal osteoporotic defects in adult patients do not hinder osseointegrated implant placement because, biologically speaking, they do not hamper bone repair. In fact, they may even favor it as a result of the large number of stem and osteoprogenitor cells comprising the bone marrow. Safe diagnosis is essential to differentiate focal osteoporotic defects from more severe similar lesions also found in the mandible. This study highlights the main characteristics of focal osteoporotic defect in adult patients, considering the condition as a variation of normal bone and medullary trabecula.

**Keywords** / Focal osteoporotic defects in adult patients. Mandibular lesions.

## Alberto **Consolaro**

Full professor, Department of Pathology, School of Dentistry – University of São Paulo/Bauru and Postgraduate Department, School of Dentistry – University of São Paulo/Ribeirão Preto.

**How to cite this article:** Consolaro A. Focal osteoporotic bone marrow defect: Concept, diagnosis and osseointegrated implants. Dental Press Implantol. 2013 Oct-Dec;7(4):25-30.

**Submitted:** November 15, 2013 - **Revised and accepted:** November 20, 2013

**Contact address:** consolaro@uol.com.br

» The author informs he has no associative, commercial, intellectual property or financial interests representing a conflict of interest in products and companies described in this article.

» The patients displayed in this article previously approved the use of their facial and intraoral photographs.

## INTRODUCTION

In the context of oral rehabilitation, bone structure density plays an important role in treatment planning performed with osseointegrated implants. Structural and imaginologic bone density refers to the amount of trabeculae within an area of bone: the more trabeculae, the greater the density.

The jaw may vary in bone density:

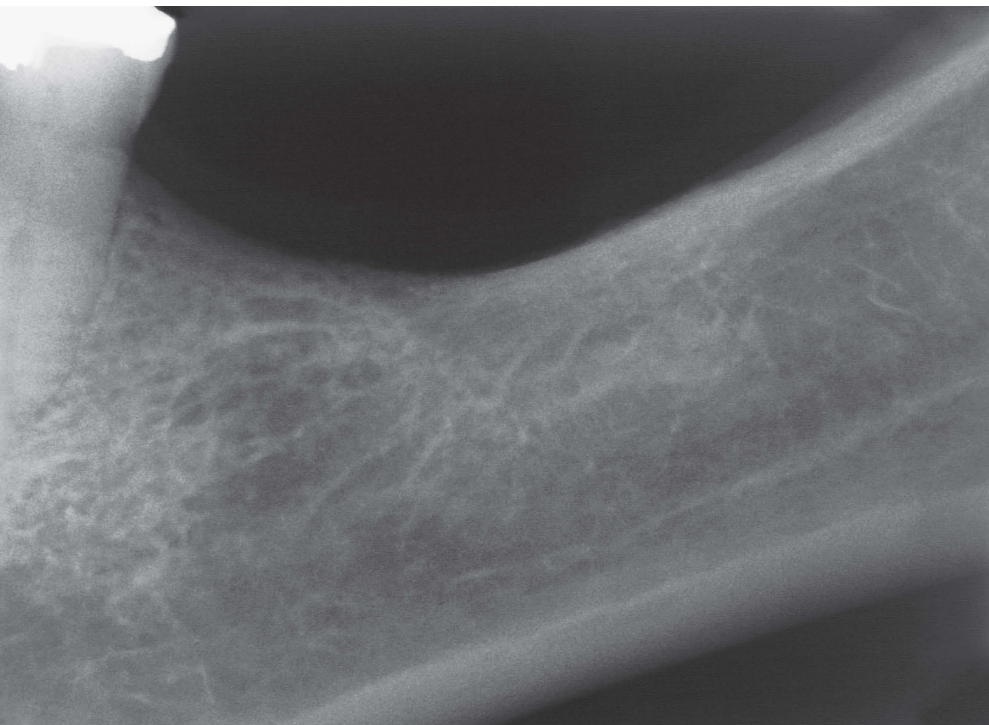
- a)** The maxillary tuberosity tends to be less dense, with thin and short trabeculae.
- b)** The anterior region of the mandible has thicker trabeculae, with small, but numerous medullary spaces.

An area with increased bone density is known to be undergoing bone sclerosis or focal sclerosis. Should the cause of sclerosis be known, the area in which it is found is called focal sclerosing osteitis. Should it be unknown, the areas are called dense bone islands or idiopathic osteosclerosis.

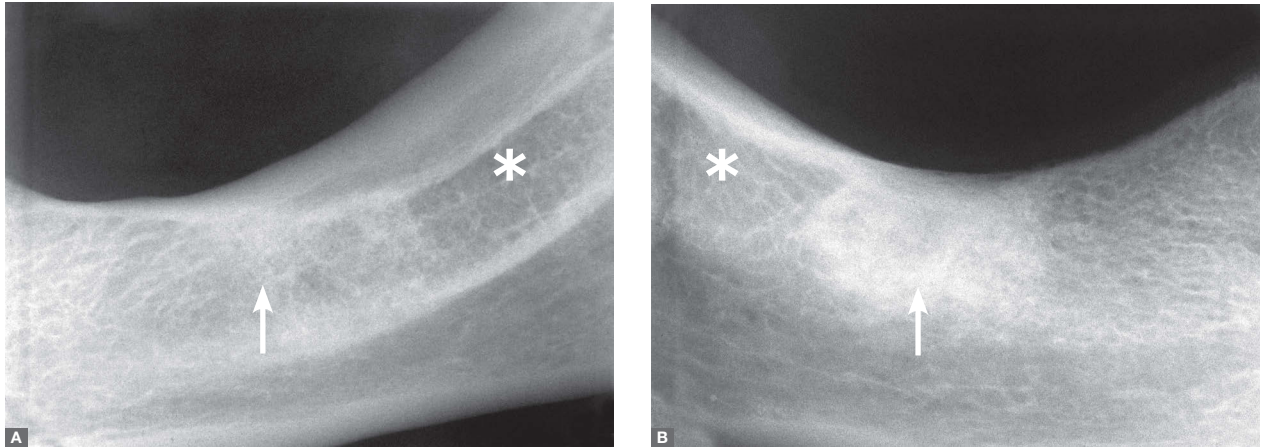
Nevertheless, bone density may also be characterized by wide medullary spaces dissociated by thin, short trabeculae. The trabecula is so “loose” or dissociated that some clinical cases may be imaginologically diagnosed as inflammatory bone lesions, whether reactionary, pseudotumoral and neoplastic. For example, in the posterior and buccolingual region of the mandible, the bone trabecula is so dissociated that may lead to dubious diagnosis when overlapped with images of the mandibular fovea.

A differential diagnosis of bone lesions must consider variations in bone normality (density and uniformity) (Figs 1, 2), including osteoporotic defects in adult patients, which may hinder safe diagnosis of normality during dental treatment planning with osseointegrated implants (Fig 3).

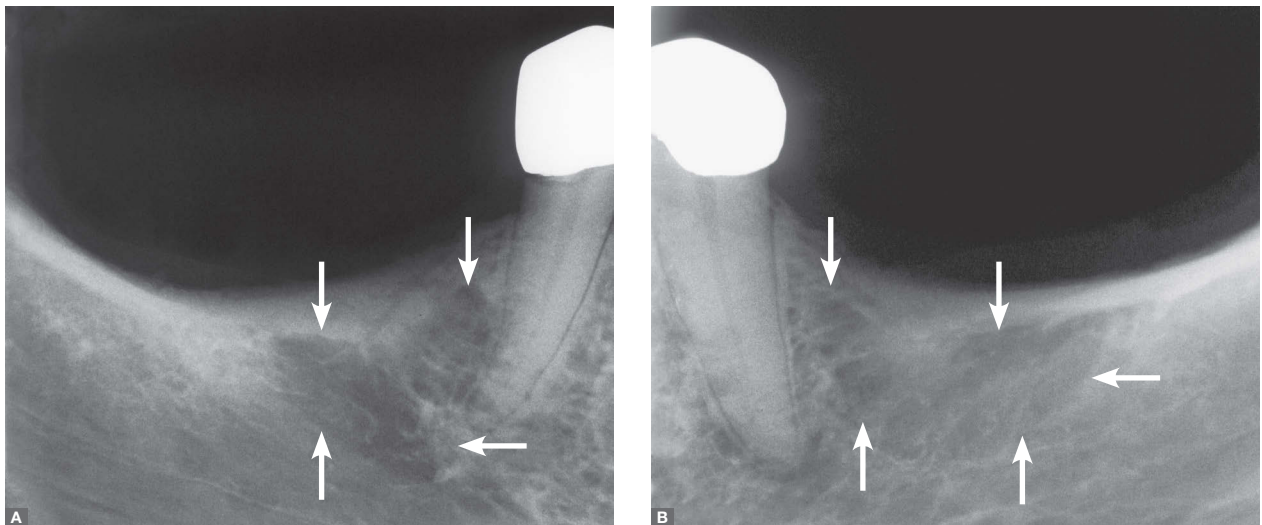
Focal Osteoporotic Defect in adult patients is also known as Focal Osteoporotic Defect or Haematopoietic Focal Osteoporotic Defect.



**Figure 1:** Bone structure density in bone repair after extraction may vary significantly according to previous conditions such as periodontal disease, periapical periodontitis, fracture, etc.



**Figure 2:** Bone density in bone repair after extraction may vary from extreme (arrow) to loose (\*) within one small mandibular area.



**Figure 3:** Focal Osteoporotic Defect in edentulous adult patient, probably as a result of changes in bone repair after extraction associated with reactionary hyperplasia in hematopoietically active bone marrow. Bilateralism probably due to similarity between both conditions.

### FOCAL OSTEOPOROTIC DEFECTS IN ADULT PATIENTS: CONCEPT AND CAUSES

Focal Osteoporotic Defect in adult patients are radiolucent, irregular and asymptomatic lesions that affect the jaw (Fig 3), especially the posterior region of the mandible of middle-aged women (from 40 to 50 years old). Microscopic biopsy<sup>1</sup> revealed that these areas are

filled with hematopoietically active (red) bone marrow occasionally permeated by adipocytes typical of yellow bone marrow.

Children and adolescents have their maxillary and mandibular bones filled with trabeculae permeated by active haematopoietic medullary tissue to aid the production of blood cells. Adults, on the other hand,

have atrophic active medullary tissue, with medullary spaces filled with atrophic bone marrow made of adipose and fibrous tissue. For this reason, they have what is known as yellow bone marrow. Red or hematopoietically active bone marrow may be found in three regions of an adult's jaw: maxillary tuberosity, angle of the mandible and mandibular condyle.

Focal osteoporotic defect in adult patients does not promote either expansion of the cortex or asymmetry of the dental arch and/or face. It is usually diagnosed by imaginologic exams taken prior to rehabilitation as well as orthodontic, surgical or other types of dental treatment planning.

Focal Osteoporotic Defect in adult patients is caused<sup>1-7</sup> by the following:

- 1) Red bone marrow hyperplasia caused by local stimulus such as recent extraction, i.e., a year before (Fig 3).
- 2) Changes in bone repair with dissociated or loose trabecula as a result of local trauma and/or extraction in areas of functional physical stimulus (Fig 3).
- 3) Enduring hematopoietically active medullary tissue in these areas since childhood and adolescence, when such tissues are considered normal.
- 4) Bone marrow hyperplasia induced by an organic demand increased by blood cells as in sickle-cell disease and other hematologic diseases. Focal Osteoporotic Defect in adult patients as a manifestation of hematologic diseases is refuted by many researches.

### IMAGINOLOGIC ASPECTS AND DIFFERENTIAL DIAGNOSIS

At their initial and medium stages, Focal Osteoporotic Defect in adult patients may be wrongly diagnosed as ameloblastomas, odontogenic keratocysts, myxomas and other odontogenic tumors. Today, imaginologic exams are often employed by dental and medical practice, thus allowing such lesions to be diagnosed at their initial stages. It is important that the

morphological pattern of Focal Osteoporotic Defect in adult patients be well characterized so as to make a differential diagnosis.

The radiolucent areas of Focal Osteoporotic Defect in adult patients are crossed by short, delicate trabeculae randomly and separately distributed, with acute and straight angled drawings among them (Fig 3). Unlike ameloblastomas, keratocysts and other odontogenic tumors (except for myxomas), the radiolucent areas tend to be roundly shaped, without angle-shaped drawings between the trabeculae and reactional bone that surrounds it.

Focal Osteoporotic Defect in adult patients tend to respect the lamina dura of adjacent and topographically-related teeth without inducing root resorption. Ameloblastomas often present root resorption in the roots of teeth adjacent to the lesion. As for myxomas and odontogenic keratocysts, root resorption is rarely found in adjacent teeth. The imaginologic aspects of Focal Osteoporotic Defect in adult patients are rarely mistaken by fibrous bone lesions at their initial stages, for instance, Florid Cemento-Osseous Dysplasia and Fibrous Dysplasia of the Maxilla.

Some Focal Osteoporotic Defects in adult patients must differentiate from Simple Bone Cyst,<sup>6</sup> even though neither of them result in root resorption, and both of them respect and surround the lamina dura without expanding the bone cortex to the corresponding area. Simple bone cyst tends to be unilocular, despite being round-shaped and without delicate, short trabeculae crossing its radiolucent area. Patient's profile is another differential: Simple Bone Cyst prevails among adolescents and young adults, whereas Focal Osteoporotic Defect in adult patients prevails among women aged between 40 and 50 years old.

Out of the 197 cases of Focal Osteoporotic Defect in adult patients analyzed by Barker et al,<sup>1</sup> 50 were found in the mandibular region of first molars, while 28 were in second molars and 59 cases were found in the region of third molars or more distally. Only 18 cases were diagnosed in the maxilla, especially in the maxillary tuberosity. Similar outcomes were described by Lipani et al<sup>4</sup> (16 lesions) and Schneider et al<sup>6</sup> (298 lesions).

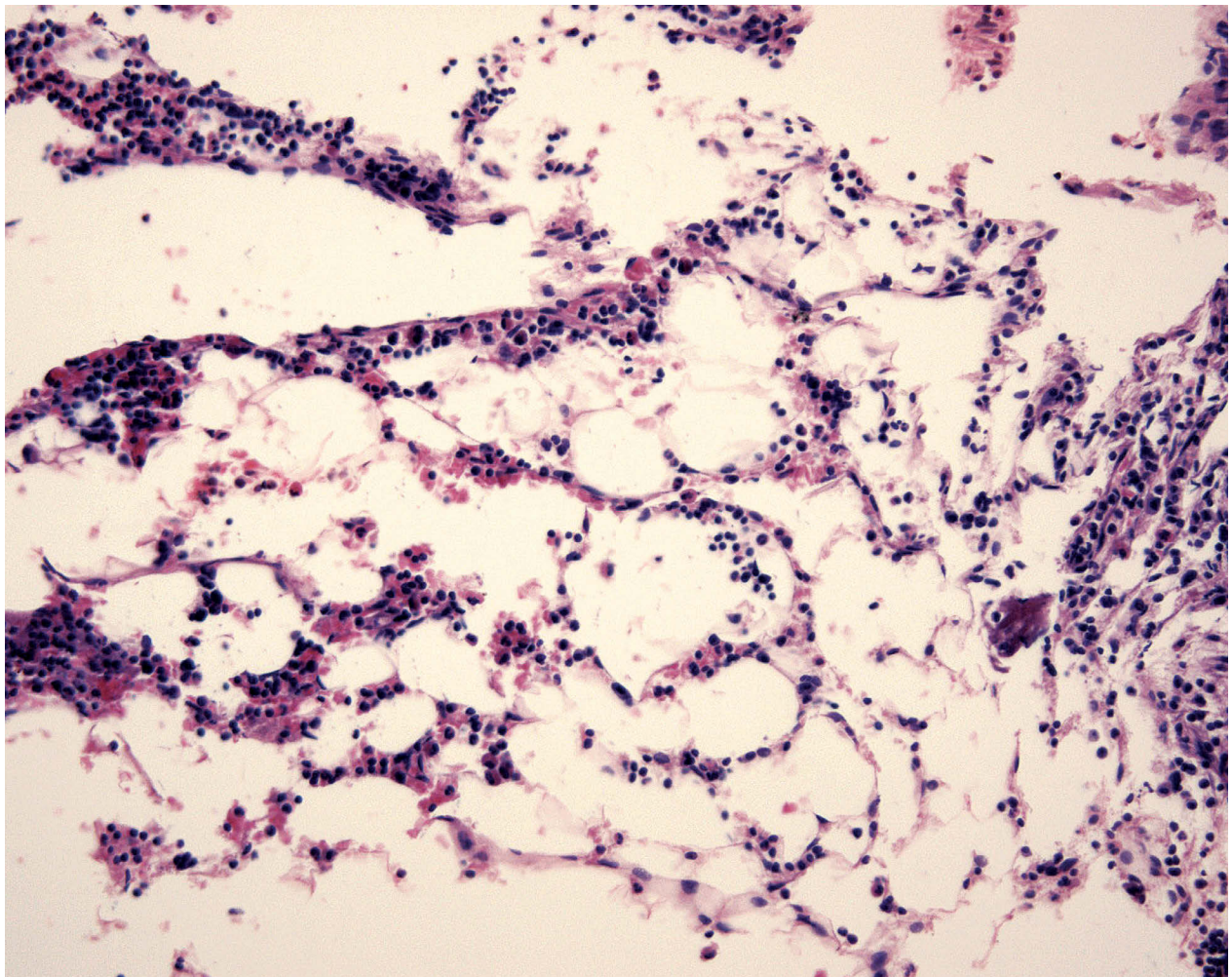
Unfortunately, despite being often found, Focal Osteoporotic Defects in adult patients are rarely included in the list of differential diagnosis of mandibular lesions, generally due to being unknown.

### MICROSCOPY AND HISTOPATHOLOGY REPORT

Should any diagnostic doubts arise after clinical and imaginologic examinations, incisional biopsy must be carried out so as to avoid postponing the definitive diagnosis. As for Focal Osteoporotic Defect in adult patients, microscopic description reports the presence of hematopoietically active bone marrow and fat cells.<sup>1-7</sup>

Cytology by aspiration may reveal that the content of the risk area consists of hematopoietically active bone marrow, in which case cytological diagnosis is critical for the interaction between clinical and imaginologic data to make an accurate final diagnosis. Should any diagnostic doubts remain after cytology, a biopsy must be carried out.<sup>7</sup>

Microscopic diagnosis is not always accurate with regard to Focal Osteoporotic Defect in adult patients. However, description of hematopoietically active bone marrow tissue crossed with clinical, surgical and imaginologic data allows correct clinical diagnosis. Sending the diagnostic images to a pathologist may favor a more precise and accurate diagnosis.



**Figure 4:** Hematopoietically active bone marrow permeated by adipocytes found in Focal Osteoporotic Defect in adult patients.

## FOCAL OSTEOPOROTIC DEFECTS IN ADULT PATIENTS AND OSSEOINTEGRATED DENTAL IMPLANTS

Biology of osseointegration does not hinder implant placement in adult patients with Focal Osteoporotic Defect. However, the fact that their bone pattern offers little immediate mechanical interlocking<sup>7</sup> should be carefully considered.

In spite of offering little mechanical interlocking, the bone pattern of Focal Osteoporotic Defect adult patients gives good biological conditions for osseointegration due to the presence of hematopoietically active bone marrow rich in stem cells as well as osteoprogenitor cells with high potential to osteogenesis, especially in the surface of osseointegrated implants. Focal Osteoporotic Defect in adult patients does not require treatment, although surgical manipulation may alter its trabecular pattern.

## FINAL CONSIDERATIONS

Focal osteoporotic defects in adult patients must be on the list of differential diagnosis of uni and multilocular radiolucent lesions, especially in the mandible. Clinical and imaginologic diagnoses are safe, however, a biopsy must be immediately performed in case of doubt, in which case the histopathology report will include hematopoietically active medullary tissue.

Focal Osteoporotic Defect in adult patients does not hinder osseointegrated implant placement because, biologically speaking, it does not hamper bone repair. In fact, it may even favor it, as a result of the large number of stem and osteoprogenitor cells comprising the bone marrow. Safe diagnosis is essential to differentiate focal osteoporotic defects from more severe similar lesions also found in the mandible. Focal Osteoporotic Defect in adult patients represents a morphological variation of bone trabecula of the jaw.

---

### References:

1. Barker BF, Jensen JL, Howel PV. Focal osteoporotic bone marrow defects of the jaws: an analysis of 197 new cases. *Oral Surg.* 1974;38(3):404-12.
  2. Frances MG, Crews KM, Kevin, M Carroll O. Focal osteoporotic bone marrow defect in the anterior maxilla. *Oral Surg Oral Med Oral Pathol.* 1993;76(4):537-42.
  3. Haen P, Ranoarivony T, Seigneuric, JB. Focal osteoporotic bone marrow defect of the mandible. A little documented pathology. *Rev Stomatol Chir Maxillofac.* 2009;110(3):155-7.
  4. Lipani CS, Natiella JR, Greene GW Jr. The hematopoietic defect of the jaws: a report of sixteen cases. *J Oral Pathol.* 1982;11(6):411-6.
  5. Marmulla R, Mühling J. Verification of extensive bone marrow hyperplasia using magnetic resonance imaging. *J Oral Maxillofac Surg.* 2007;65(8):1590-4.
  6. Schneider LC, Mesa ML, Fraenkel D. Osteoporotic bone marrow defect: radiographic feature and pathogenic factors. *Oral Surg Oral Med Oral Pathol.* 1988;65:127-9.
  7. Sençimen M, Dellibasi C, Gülses A, Okçu KM, Gunhan O, Varol A. Focal osteoporotic hematopoietic bone marrow defect formation around a dental implant: a case report. *Int J Oral Maxillofac Implants.* 2011;26(1):e1-4.
-