

Membranes function in bone fracture healing and bone surgery

Abstract: “Essence” is the primary reason for being, using or understanding something. The essence of a membrane, regarding the mechanisms of socket bone repair, is to replace the injured or damaged periosteum so as to prevent non-osteogenic cells from colonizing blood clot and exudate, forming a fibrous or adipose tissue to fill the “empty” spaces. Bone cells are slower in comparison to other cells; and the membranes, which substitute the periosteum, preserve or restore the bone cavity which becomes an area restricted to bone cells. Furthermore, due to its organization and productive capacity, the periosteum plays an essential role in bone reconstruction and remodeling, adapting the bone to potential functional demands. **Keywords:** Bone repair. Membranes. Periosteum. Bone fracture.

Alberto CONSOLARO

Full professor, School of Dentistry —USP/ Bauru and professor of the postgraduate program at the School of Dentistry —USP/ Ribeirão Preto.

The importance of the periosteum to bone repair

Understanding the adaptive, reaction and/or repair capacity of the periosteum helps us understand the use of membranes, repair or epithelial regeneration guides for maxillary surgery.¹

Craniofacial bones are of intramembranous origin. They grow by apposition and resorption of periosteal and cortical surfaces and sutures. Even after the growth phase,

the bones of the face may undergo morphological changes often caused by apposition and resorption of periosteal surfaces, unlike endochondral bones that form and grow from a previously formed cartilage.

Cases of long bone fracture often cause areas of hyaline cartilage to form (Figs 1, 2, 3), which does not occur in the maxilla and the mandible, as bone cells do not go through this phase to directly deposit bone matrix and build bone as an anatomical structure.

How to cite this article: Consolaro A. Membranes function in bone fracture healing and bone surgery. *Dental Press Implantol.* 2014 Jan-Mar;8(1):68-80.

Submitted: March 13, 2014 - **Revised and accepted:** March 20, 2014

Contact address: consolaro@uol.com.br

» The author informs he has no associative, commercial, intellectual property or financial interests representing a conflict of interest in products and companies described in this article.

The structure of the periosteum

The periosteum is firmly inserted into the surface of cortical bone through Sharpey's fibers that, in turn, are inserted into bone matrix of collagen nature. The periosteum connective tissue³ is divided into two different contiguous layers:

- 1) **The outer layer**, mainly formed by fibroblasts. It is predominantly fibrous and aims at providing protection to the surface. This layer originates collagen fibers that are periosteally inserted into the sub-jacent cortical bone.
- 2) **The inner layer** of the periosteum is directly related to the cortical bone surface and is characterized for being rich in osteoblasts, pre-osteoblasts, osteoprogenitor cells, tissue stem cells, clasts and other cells in smaller numbers.

The center of the periosteal structure is intensely vascularized by a network formed by small vessels that branch off towards the bone surface. This intermediate zone formed by numerous capillaries could represent a third layer that differs in terms of thickness from the periosteum. The periosteum provides the bone structure with blood supply.

The **surgical opening** of the periosteum is a traumatic procedure that implies in loss of biological feasibility of the cortical bone surface layer. The osteocytes of the surface layer die and the bone matrix layer that hosted them undergoes resorption; with or without compensatory bone neoformation, depending on local conditions.

The most important indicator of bone vitality and feasibility is the presence of osteocytes

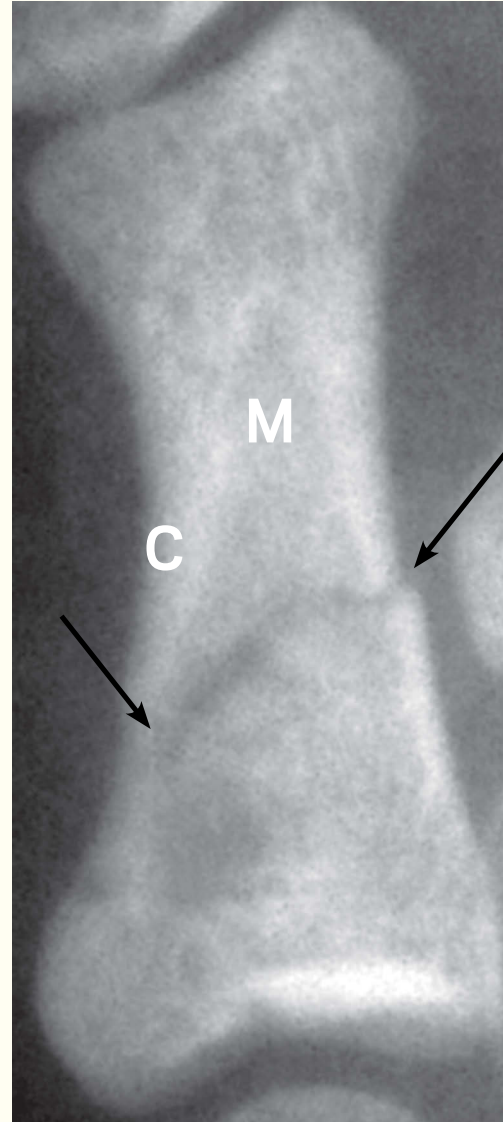


Figure 1. Long bone fracture used in this text to explain the process of bone repair and the importance of the periosteum. The arrows indicate the bone fracture line which is the epicenter of bone repair. C = cortex; M = bone marrow

within bone lacunae or osteoplasts. Without osteocytes, the bone is likely to undergo resorption and to be repositioned posteriorly. When periodontal surgery is performed on free cortical surfaces with thin alveolar cortical bone, the cleft flap technique causes the periosteum to adhere to the cortex, thus avoiding surface resorption and, as a consequence, preventing bone dehiscences and fenestrations.

Adaptive and reaction capacity of the periosteum

The adaptive and reaction capacity of the periosteum promotes local phenomena that depend on:

- a) *the degree of stimulus or offending agent: it must be durable and low.*
- b) *the level of local mediators: mild inflammations tend to accumulate mediators that, if slightly increased, induce osteoproduktive phenomena. Conversely, these same mediators, if accumulated at high levels, induce resorption.*
- c) *structural and functional integrity: preserving the periosteum cells as well as the periosteum circulatory tree is essential to produce new bone layers.*

Bone turnover has mediators of systemic and local action. Parathyroid hormone, calcitonin, vitamin D³ and estrogens are among systemic mediators. Their action is continuous and associated with the serum level of calcium and phosphorus. Conversely, it does not depend on local stimuli.

The local mediators of bone turnover play an important role, particularly in bone areas that require tissue adaptation and

reactions against stimuli such as the action of muscular forces accidentally applied or applied for orthopedic purposes.

Whenever forces are applied, the cells undergo alterations in shape as well as at the level of oxygenation due to alterations in blood flow. Deformation of the cytoskeleton and hypoxia are natural inducers of cellular stress, in which case mediators that are essential for cellular intercommunication, particularly cytokines, growth factors and products of arachidonic acid, are released. The phenomena induced by these mediators aim at restoring normality. Whenever physical events, such as force, change into biological reactions, it is possible to say that a phenomenon of “translation” or transduction was established. In other words, a physical phenomenon becomes biological, which can be summarized by the term mechanotransduction.

A classic example of mechanotransduction associated with osteogenesis is the transmission of tension to suture fibers caused by intracranial pressure, which stimulates bone neoformation and, as a result, bone growth.⁴ The force exerted by muscles and tendons increase cortical thickness as well as trabecular bone thickness and density, which represents an adaptive response to increased functional demand. It is possible to say that structural morphology is directly related to the type and degree of functional demand applied to a given structure.

In some cases, the stimulus or offending agent induces cellular stress and triggers a low-intensity inflammatory process that ceases with time if the cause of inflammation is eliminated, or remains if the cause remains. The inflammatory exudate and infiltrate are important alternative sources of local mediators of bone turnover.

BONE FRACTURE REPAIR AND THE IMPORTANCE OF THE PERIOSTEUM

Long bone fracture is the first example that helps us understand the idea of bone repair (Fig 1). The cortical bone has vessels and cells filling the Haversian and Volkman's canals, as well as the inner periosteum and the endosteum, that also cover bone trabeculae. The trabeculae, as well as the cortex, also have many undifferentiated and differentiated cells that, if necessary, originate new cells, as it is the case of bone repair, especially bone surface repair, of the endosteum. The bone marrow is another important source of bone repair cells and vessels, even if it is not hematopoietically active or red, in other words, in case of adipose or fibrous bone marrow.

In the fracture line between the cortex and the spongy bone and below the periosteum, serous exudate rich in blood clot and fibrin form (Fig 2A). The periosteum may or may not break by the lesion that caused the fracture. Nevertheless, its repair capacity is quicker than that of other bone components. The arrival of neutrophils with an insignificant amount of bacteria causes the acute phase of inflammation to evolve to repair within the first hours, which stimulates the phenomena of cell proliferation, differentiation, migration and synthesis in neighboring cells and cleaning of the area by the action of macrophages. The two major sources of mediators that cause the aforementioned phenomena are the macroplatelets of the fibrin network and the macrophage hyperactivated by phagocytosis.

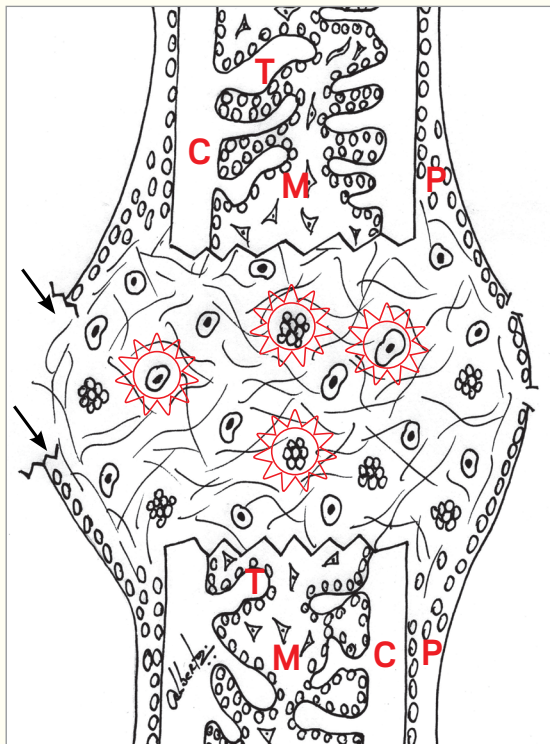







Figure 2A. At the fracture site, the inflammatory exudate and blood clot are characterized by an exuberant fibrin network that provides anchorage to cells and platelets. While the macrophages clean the area, the platelets release a large amount and variety of mediators (arrows) so as to stimulate the neighboring cells to differentiate, migrate and colonize the area. Partially injured periosteum (arrows).

P = periosteum; C = cortex; T = trabeculae; M = bone marrow

-  Undifferentiated cells
-  Osteoblasts
-  Macroplatelets
-  Macrophages
-  Fibrin network

Angiogenesis is a process that originates in the endothelial sprouts of blood vessels neighboring the periosteum and the endosteum (Fig 2B). Following their path, undifferentiated young cells or pre-differentiated cells go on colonizing the fibrin network that is formed. Within a few hours or days, blood clot and/or serofibrous exudate changes into a jelly-like tissue that represents the young granulation tissue which is rich in: 1) neoformed vessels; 2) recently-arrived young differentiated cells; and 3) macrophage and leukocytes remaining from the acute phase of inflammation (Fig 2B). The presence of

foreign bodies, bone fragments and necrotic areas physically hinders the formation of granulation tissue.

In the granulation tissue, the recently-differentiated cells that migrated to that area start to synthesize new extracellular bone matrix, predominantly of collagen nature, which will be further mineralized. They are of endosteal and periosteal origin and assume the genotype and the phenotype of young osteoblasts – synthesizers of bone matrix.

Initially, from the outer surface to the center, the synthesis occurs with primary,

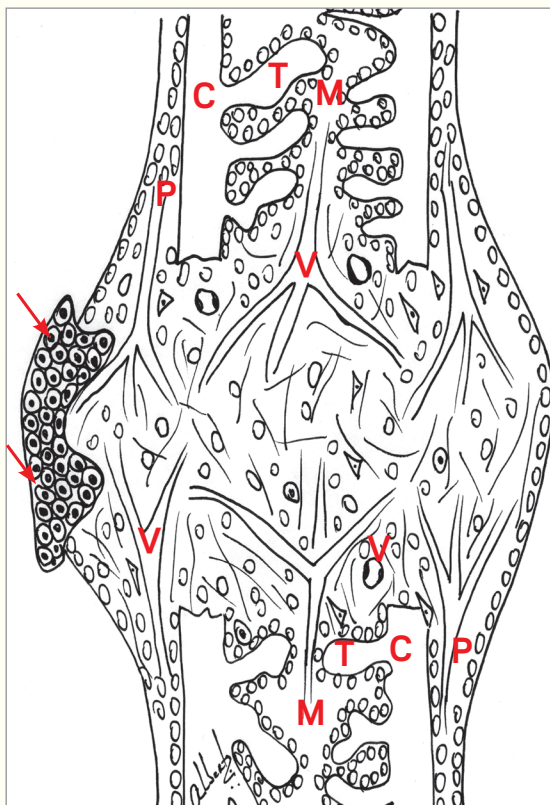







Figure 2B. Neoformed vessels (V) replace blood clot and exudate. The vessels are formed from bone marrow (M), periosteum (P), undifferentiated cells and young osteoblasts that gradually migrate and replace the fibrin network by extracellular matrix. As a result, granulation tissue is formed. Injured periosteum (P) is replaced by a temporary plug formed by hyaline cartilage (arrows) which prevents the cells of neighboring fibrous connective tissue from entering into the bone environment. V = neoformed vessels; M = bone marrow; P = periosteum; C = cortex; T = trabeculae.

-  Undifferentiated cells
-  Osteoblasts
-  Macroplatelets
-  Macrophages
-  Fibrin network

embryonic or immature bone tissue, which is characterized by its high number of cells, low level of mineralization and disorganized distribution (Fig 2C). Primary bone matrix deposition does not follow a plan of absorption and distribution of forces, it only meets a demand for filling the injured area.

The granulation tissue extends for the inner part of neighboring medullary spaces, as well as for subperiosteal spaces lateral to the fracture line in such a way that it significantly overlays the surface and the contour of the original bone (Fig 2A, 2B). The excess bone formed from exuberant granulation

tissue at the fracture line and which exceeds normal limits and dimensions is known as bone callus.

As the days goes by, primary or immature bone is filled with irregular trabeculae from the outer layer to the center, and is gradually reabsorbed. The areas it used to occupy will be then filled with secondary or mature bone which is able to meet functional demands, such as muscular forces exerted during movement (Fig 2D). As the weeks go by, the entire granulation tissue is replaced by a new secondary bone which is usually excessive. As the bone

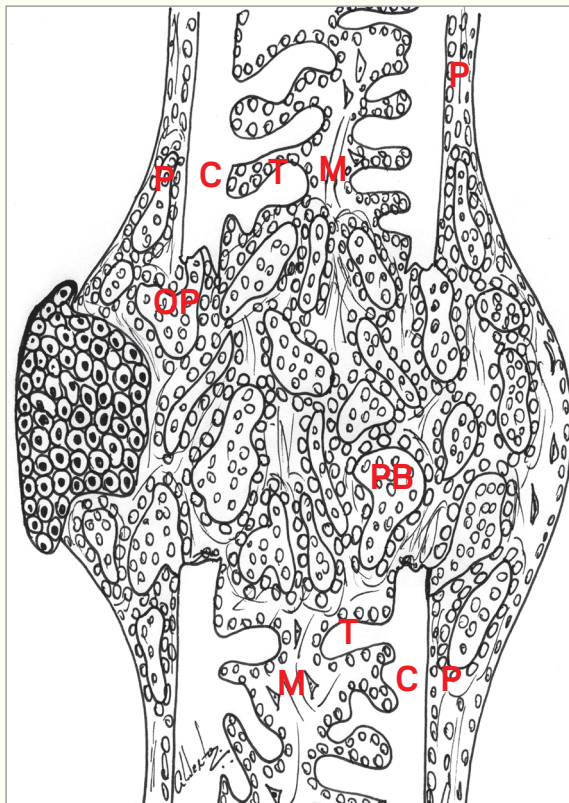







Figure 2C. Irregular primary bone (PB) trabeculae gradually occupy most granulation tissue, from the outer layer to the center. They are rich in cells and little mineralized due to exerting its filling function. In the subperiosteal areas, primary bone is also exuberantly formed, similarly to ossifying reactional periostitis. The temporary plug formed by hyaline cartilage gradually loses its function as the periosteum restores its continuity.
PB = primary bone; C = cortex; T = trabeculae; P = periosteum; M = bone marrow.

-  Undifferentiated cells
-  Osteoblasts
-  Macroplatelets
-  Macrophages
-  Fibrin network

meets the functional demands to which it is subjected, it is continuously remodeled and adapted to its new conditions in accordance with its trabecular density. As a result, cortical thickness and bone callus gradually disappear.

THE ROLE OF THE PERIOSTEUM IN BONE FRACTURE AND THE ROLE OF MEMBRANES IN BONE REPAIR

Within a few hours after bone fracture is caused, the periosteum — acting as a specialized, membranous connective tissue — proliferates and tends to recover the injured or

ruptured area, compartmentalizing the bone environment and restricting the repair process to the cells and bone structural components.

The injured or ruptured periosteum soon recovers in terms of continuity, given that one of its major functions within bone pathophysiology is to isolate the bone environment from neighboring soft tissues. Regarding the speed of migration, the cells of neighboring connective tissue are much faster than osteoblasts and predecessor cells. The presence of periosteum compartmentalizes the bone environment.

In bone fracture, it is common to find areas of hyaline cartilage (Fig 2B, 2C, 3)

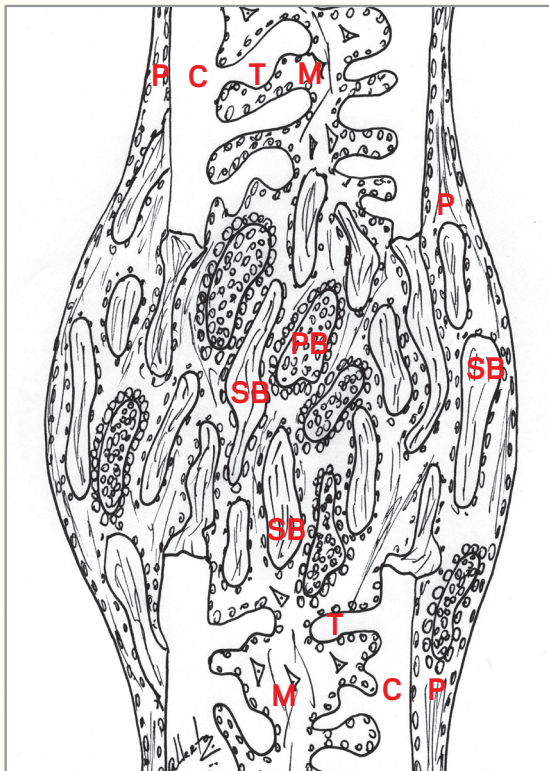







Figure 2D. Secondary or mature bone (SB) gradually replaces primary bone (PB) from the outer layer to the center. Due to being thicker and less cellularized than primary bone, it is able to meet functional and mechanical demands. The periosteum (P) restores its integrity and, as a result of frequent bone remodeling, the cortex (C) gradually recovers and excess bone formed on the surface (bone callus) is slowly remodeled. SB = secondary bone; PB = primary bone; P = periosteum; C = cortex; T = trabeculae; M = bone marrow.

-  Undifferentiated cells
-  Osteoblasts
-  Macroplatelets
-  Macrophages
-  Fibrin network

usually where the periosteum was ruptured or severely injured. When the outer cells of bone repair granulation tissue are exposed to soft tissues, they differentiate into chondrocytes with a view to isolating the bone cavity, given that the periosteum is injured. After the periosteum is structurally recovered and bone repair gradually progresses, the hyaline cartilage ossifies or causes its cells to undergo a process of apoptosis, which replaces it by new bone.

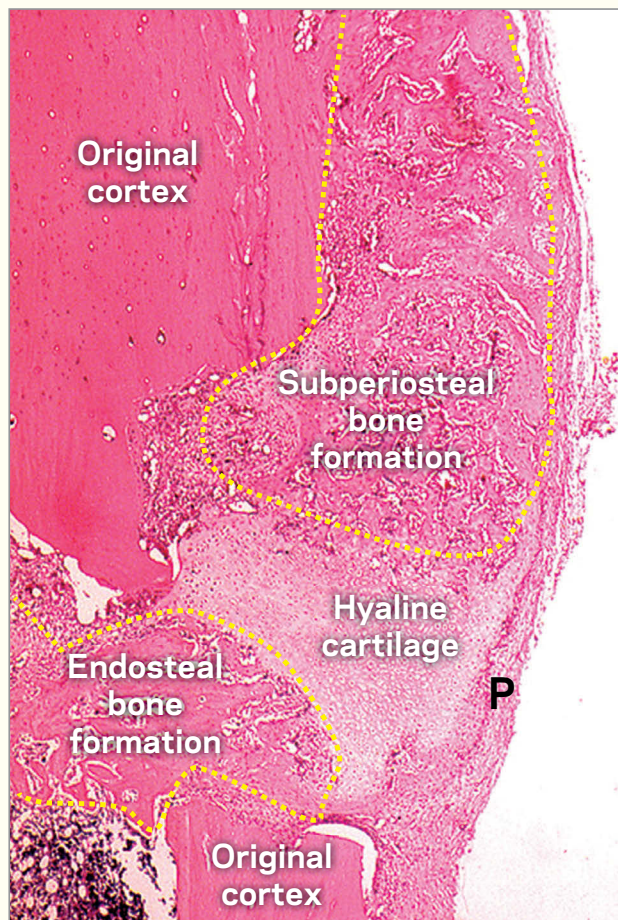


Figure 3. Bone repair process established in case of fracture, in which primary bone neoformation is well advanced in the subperiosteal and endosteal areas. The plug formed by hyaline cartilage and the covering of the area by the new periosteum (P) are highlighted. (HE, 10x).

The hyaline cartilage plays an effective role in areas of endochondral ossification. In areas of intramembranous ossification, as it is the case of the maxilla and mandible, the hyaline cartilage does not act because the cells that enter the granulation tissue do not have active genetic information that enables them to differentiate into chondroblasts (Figs 4,5). Thus, in these cases, the bone fracture site is more susceptible to be invaded by neighboring fibrous connective tissues, if the periosteum is severely injured or missing. Should the aforementioned situation occur in cases of movable bone fracture, a pseudarthrosis (false joint) is established.










When fibroblast cells invade the granulation tissue in areas of bone repair, there will be deposition of extracellular matrix typical of fibrous connective tissue. In other words, fibrous connective tissue will form (Figs 6, 7). The process by which fibrous connective tissue fills a space that does not exist under normal conditions is known as fibrosis or healing fibrosis. Fibrosis is common in cases of maxillary bone repair surgery and tooth extraction.

MEMBRANES USED AS PERIOSTEUM SUBSTITUTES IN SURGICAL BONE CAVITY

In the maxilla and the mandible, intramembranous ossification hinders the formation of hyaline cartilage which, at least temporarily, replaces severely injured periosteum (Figs 6, 7).

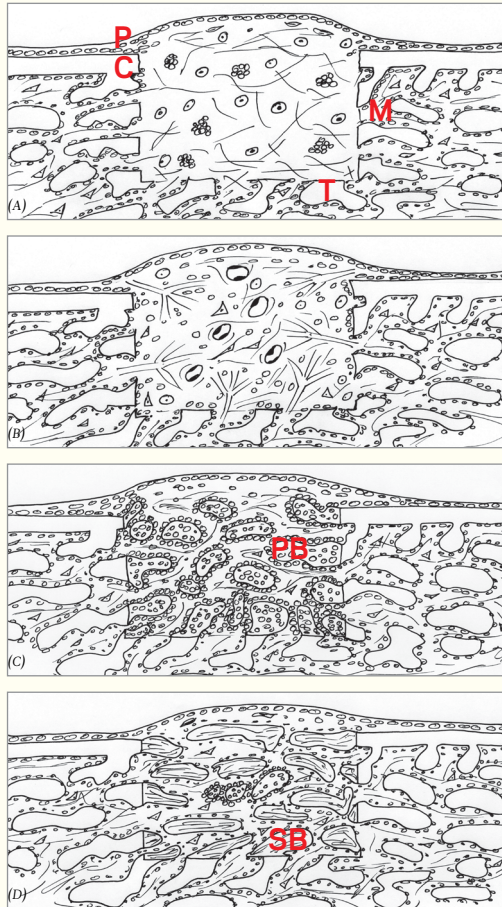

Figure 4. **A)** At the fracture site, the inflammatory exudate and blood clot are characterized by an exuberant fibrin network that provides anchorage to cells and platelets. **B)** Vessels and cells originating from the endosteum, bone marrow (M) and periosteum (P). The periosteum protects the granulation tissue from being invaded by neighboring fibroblasts that originate from fibrous connective tissue. **C)** Young osteoblasts migration favors synthesis of primary bone (PB) trabeculae which is irregularly distributed for space filling from the outer layer to the center. **D)** Subsequently, primary bone is gradually replaced, from the outer layer to the center, by secondary bone (SB) trabeculae which is more organized, less cellularized and more mineralized than primary bone, thus allowing it to meet functional and mechanical demands. M = bone marrow; P = periosteum; PB = primary bone; SB = secondary bone; C = cortex; T = trabeculae.

-  Undifferentiated cells
-  Osteoblasts
-  Macroplatelets
-  Hyaline cartilage
-  Macrophages
-  Fibrin network
-  Neoformed vessels
-  Primary or immature bone
-  Secondary or mature bone

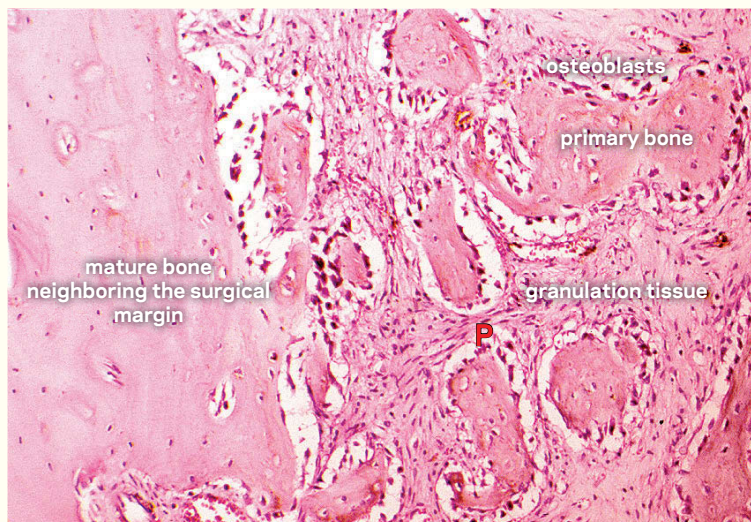


Figure 5. Primary or immature bone formation in granulation tissue of surgical bone cavity undergoing repair (HE, 25x).

For this reason, in cases of oral and maxillofacial surgery, it is recommended that special attention be given to the periosteum, particularly with regards to blood supply, flap surgery planning, irrigation during procedures to avoid cell desiccation and death, excess manipulation and evaluation during flap reposition. Cases of intramembranous ossification bone surgery with severely injured periosteum require a periosteum substitute² usually known as “membranes”, epithelial regeneration guides or repair guides (Fig 8).

The membranes essentially aim at replacing injured or missing periosteum. A few

days or weeks after the membrane is placed, the neighboring periosteum forms again by means of repair.² Resorbable or phagocytatable membranes tend to practically restore the original characteristics of the site (Fig 8). Non-resorbable membranes, however, tend to remain at the site for an indefinite period of time, behaving as foreign body enclosed by macrophage and multinucleated giant cells of inflammation that are covered by delicate connective tissue (Fig 8C). For this reason, it is recommended that this type of membrane be removed by means of a second surgical procedure, which may be inconvenient for the patient.

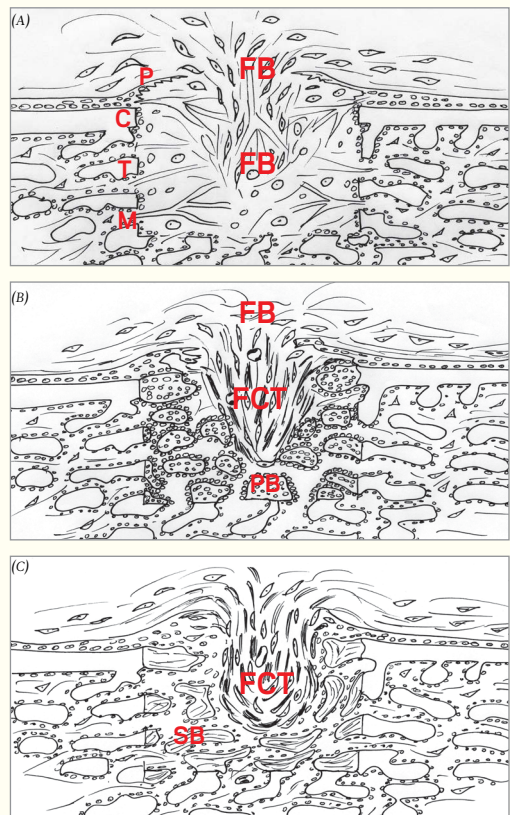











Figure 6. **A)** Severely injured periosteum (P) allows fibroblast cells (FB) from neighboring tissues to infiltrate into blood clot and exudate of the surgical cavity as a result of stimuli produced by repair mediators released by the macrophages and platelets. **B)** At this site, fibrous connective tissue (FCT) forms, in which case it will be known as healing fibrosis that hinders primary and secondary ossification in the surgical cavity. **C)** The surgical cavity remains with a structural and imagi-nologic defect. P = periosteum; FB = fibroblast cells; FCT = fibrous connective tissue; C = cortex; T = trabeculae; M = bone marrow; PB = primary bone; secondary bone.

-  Undifferentiated cells
-  Osteoblasts
-  Macroplatelets
-  Hyaline cartilage
-  Macrophages
-  Fibrin network
-  Neoformed vessels
-  Primary or immature bone
-  Secondary or mature bone

The membranes that function as periosteum substitutes present some characteristics that are inherent to periosteum, namely: being permeable to ions, amino acids and peptides, as well as to mediators such as cytokines, growth factors and products of arachidonic acid. Furthermore, they must be permeable to medication molecules such as antibiotic, analgesic and anti-inflammatory drugs. Their degree of permeability must prevent the passage of the cells, only; allowing nutrients and cell mediators to flow.

When the membranes are contaminated by *staphylococcus* or *streptococcus*

bacteria, they are associated with a suppurative inflammatory process with pus formation. Moreover, their porous structure requires increased care to prevent bacterial contamination before and during the surgical procedures. Likewise, knowing the origin of the product and avowedly knowing that it has been safely sterilized is key to achieve success with the surgical procedure.

In cases that require bone surgery, the periosteum, as well as its membranous substitutes, are anchored in the fibrin network of the inflammatory exudate and/or in the blood clot. The anchorage network offered

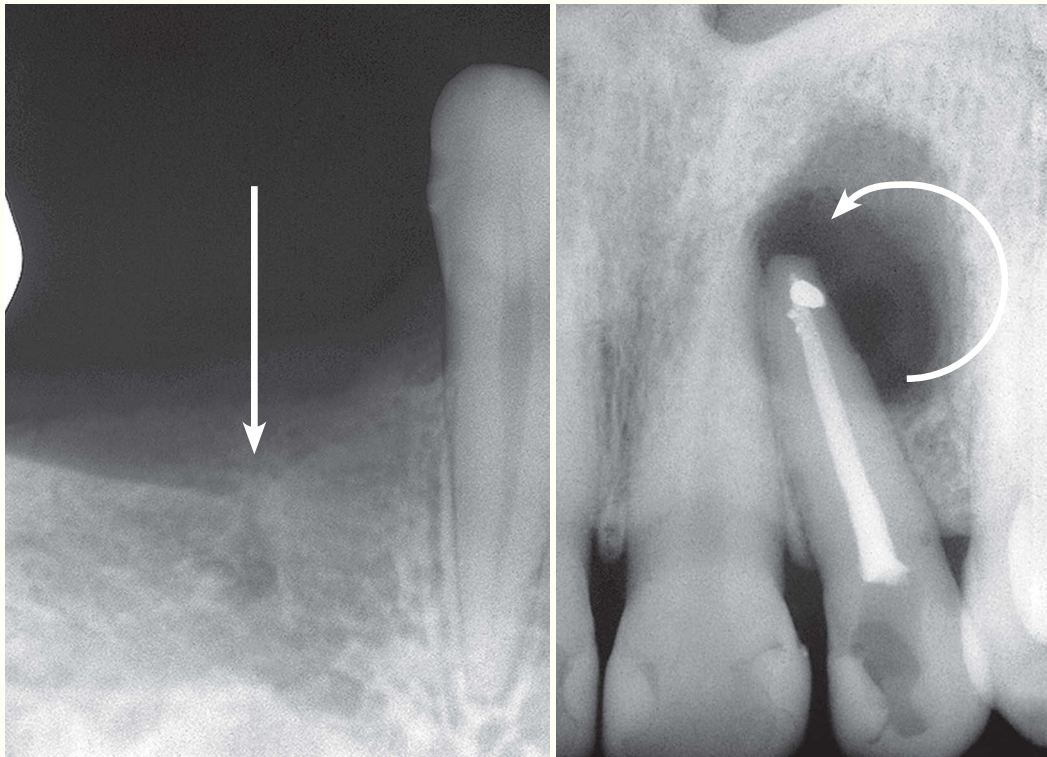


Figure 7. Fibrous connective tissue formation at two surgical sites as a result of severe periosteum defects not previously detected during flap reposition. Injured areas allowed infiltration of neighboring, soft tissue cells and formation of healing fibrosis.

by fibrin has some physical limitations, however, in cases of wider surgical cavities, the periosteum or its substitutes (the membranes) tend to mechanically break and retract. Therefore, a hollow is formed on the surface which is also followed by the periosteum and the membranes. During the final phase of repair, a portion of the surface bone cavity will not be filled by new bone, which implies in potential esthetic and functional complications.

In cases of wider surgical cavities, the fibrin network requires support for its mechanical anchorage, which may be provided by biomaterial, such as polymer fragments and lyophilized bone, placed within

the cavity. It is worth noting that the use of membranes is not necessarily related to the use of biomaterial in bone repair. Nevertheless, membranes and biomaterial may be used together, as they exert different functions in bone repair.

Some cavities have a low or missing bone wall. In order to contain blood clot – the primary matrix of bone repair – within the cavity, bone walls and, occasionally, a membrane that not only functions as periosteum substitute, but also as a delimiting support to retain the blood clot formed within this type of cavity; are necessary. In other words, the membrane may sometimes be used to retain blood clot within a cavity.

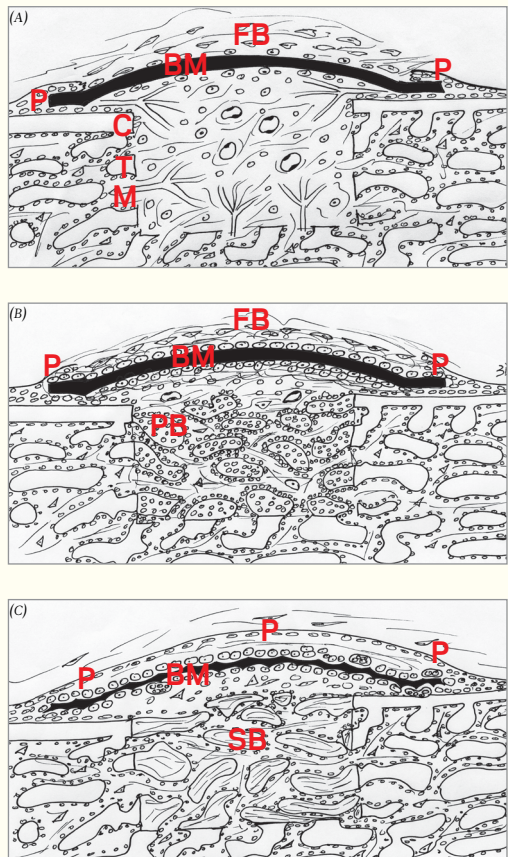











Figure 8. A) The use of a barrier membrane (BM) as a periosteum (P) substitute prevents fibroblast cells (FB) from neighboring tissues to infiltrate into blood clot and exudate of the surgical cavity as a result of stimuli produced by repair mediators released by the macrophages and platelets. **B)** When a resorbable membrane is used, a foreign body-type granuloma will temporarily form and the macrophages will gradually phagocytize the membrane. **C)** Meanwhile, the periosteum recovers itself over the degrading membrane, which may last for weeks or months. BM = membrane; P = periosteum; FB = fibroblast cells; C = cortex; T = trabeculae; M = bone marrow; PB = primary bone; SB = secondary bone.

-  Undifferentiated cells
-  Osteoblasts
-  Macroplatelets
-  Hyaline cartilage
-  Macrophages
-  Fibrin network
-  Neoformed vessels
-  Primary or immature bone
-  Secondary or mature bone

FINAL CONSIDERATIONS

- 1) *The periosteum is the delimiting structure that covers the bones and prevents the cells of neighboring soft tissues from infiltrating into the bone structure and, as a result, weakening it.*
- 2) *In cases of traumatic lesions caused by fracture ,surgery, and bone surgical cavities in which the periosteum is injured, the cells of soft tissues tend to infiltrate*

into the bone structure and form areas of fibrous connective tissue, also known as healing fibrosis. These areas do not ossify, but weaken the site and promote esthetic and/or functional defects.

- 3) *The membranes, when properly used as periosteum substitutes, may function as a barrier that allows the blood clot and the inflammatory exudate to be colonized by cells of osteogenic lineage.*

REFERENCES:

1. Consolaro A. *Inflamação e reparo*. 2a ed. Maringá: Dental Press; 2014. No prelo.
2. Rezende MLR. *Efeito da desmineralização das superfícies ósseas de contato na consolidação de enxertos autógenos em cobaias [tese]*. Bauru (SP): Universidade de São Paulo; 2008.
3. Squier CA, Choneim S, Kremenak CR. *Ultrastructure of the periosteum from membrane bone*. J Anat. 1990;171:233-9.
4. Young RW. *The influence of cranial contents on postnatal growth of the skull in the rat*. Am J Anat. 1959;105:383-415.