

# Recovering function and aesthetics of a fractured tooth using the immediate dentoalveolar restoration technique: Case report with a 3-year follow-up

**Abstract:** *The prognoses of root fracture, endodontic failure or advanced periodontal disease are not favorable. The treatment of choice for such patients includes removal of the tooth and implant therapy. Root fracture is commonly associated with bone loss, especially in the buccal wall, and the aesthetic risk is increased. This article describes the use of the Immediate Dentoalveolar Restoration technique to restore a compromised socket through bone graft, implant placement and immediate function in a patient with a complicated crown-root fracture in the maxillary central incisor. The patient was followed up clinically and tomographically for 3 years. Keywords: Dental implant. Fresh socket. Bone graft. Immediate loading.*

**José Carlos Martins da ROSA**

PhD resident in Oral Implantology, Department of Implantology, São Leopoldo Mandic Dental Research Center, Campinas/SP, Brazil.

**Ariadene Cristina Pértile de Oliveira ROSA**

PhD resident in Oral Implantology, Department of Implantology, São Leopoldo Mandic Dental Research Center, Campinas/SP, Brazil.

**Carlos Eduardo FRANCISCHONE**

Full Professor of Department of Implantology, São Leopoldo Mandic Dental Research Center, Campinas/SP, Brazil.

**Bruno Salles SOTTO-MAIOR**

Full Professor of Department of Restorative Dentistry, Federal University of Juiz de Fora, Juiz de Fora/MG, Brazil.

**How to cite:** Rosa JCM, Rosa ACPO, Francischone CE, Sotto-Maior BS. Recovering function and aesthetics of a fractured tooth using the immediate dentoalveolar restoration technique: Case report with a 3-year follow-up. *Dental Press Implantol.* 2014 Jan-Mar;8(1):86-94.

**Submitted:** January 18, 2013 - **Revised and accepted:** December 19, 2013

**Endereço de correspondência:** José Carlos Martins da Rosa - Av. São Leopoldo 680 - CEP 95097-350 Caxias do Sul - RS - Brazil - E-mail: josecarlos@rosaodontologia.com.br

The authors inform they have no associative, commercial, intellectual property or financial interests representing a conflict of interest in products and companies described in this article.

The patient displayed in this article previously approved the use of her facial and intraoral photographs.

## INTRODUCTION

Root fracture, endodontic failure, and advanced periodontal disease are frequently associated with tooth extraction and immediate implant placement. The extraction delay of a fractured tooth can lead to bacterial biofilm development, and bacterial spread into or from the fracture space,<sup>1,2</sup> resulting in buccal bone loss.<sup>3</sup> Traditionally, immediate implant placement has been contraindicated in the presence of active infection and bone defects,<sup>4</sup> especially in the absence of buccal bone wall.<sup>5</sup> Therefore, to improve clinical efficacy and esthetics and to reduce treatment time, the Immediate Dentoalveolar Restoration (IDR) technique was developed.

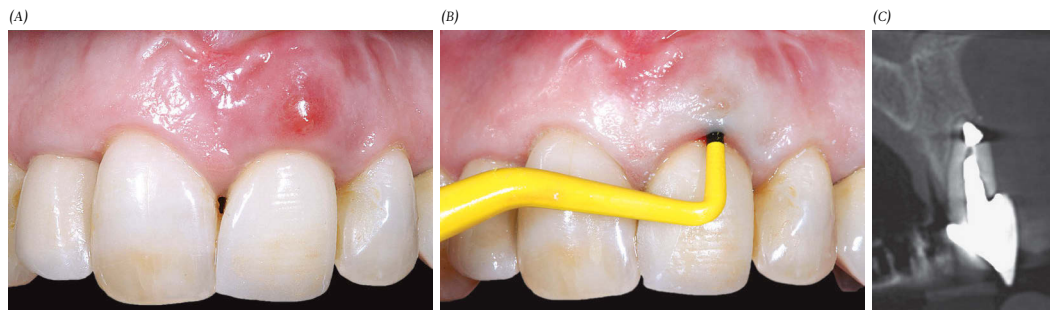
The aim of IDR is to restore the buccal bone wall during implant placement. To correct socket defects and support soft tissue esthetics, the buccal bone wall is re-established with cortico-cancellous bone graft from the maxillary tuberosity. This technique has its limitations, for example, it requires adequate bone availability in the tuberosity. This paper reports the 3-year follow-up outcomes of a patient with vertical root fracture (VRF) in the region of the upper central incisor. Preoperatively,

the patient presented socket damage and acute infection, and was treated by the IDR protocol which consists in tooth extraction, implant placement, bone graft and immediate provisional crown installation, thereby enabling treatment to be carried out in a single procedure.

## CASE REPORT

A 50-year-old woman was referred for treatment of painful symptoms in the maxillary left central incisor. Clinically, the gingival tissue exhibited fibrosis and scars at the surgical site, a thin periodontal biotype, swelling, and fistula in the vestibular region (Fig 1A). The probing depth was 11 mm buccally (Fig 1B). Cone beam computed tomography (CBCT) images showed a metallic core, good bone availability beyond the root apex, and buccal bone wall loss (Fig 1C). Due to the local infection in the fractured root (Fig 2A), antibiotic therapy started 5 days prior to and continued for 7 days after surgery.

A minimally invasive dental extraction procedure was performed. The socket was carefully treated by curettage to remove the granulation tissue and the remaining



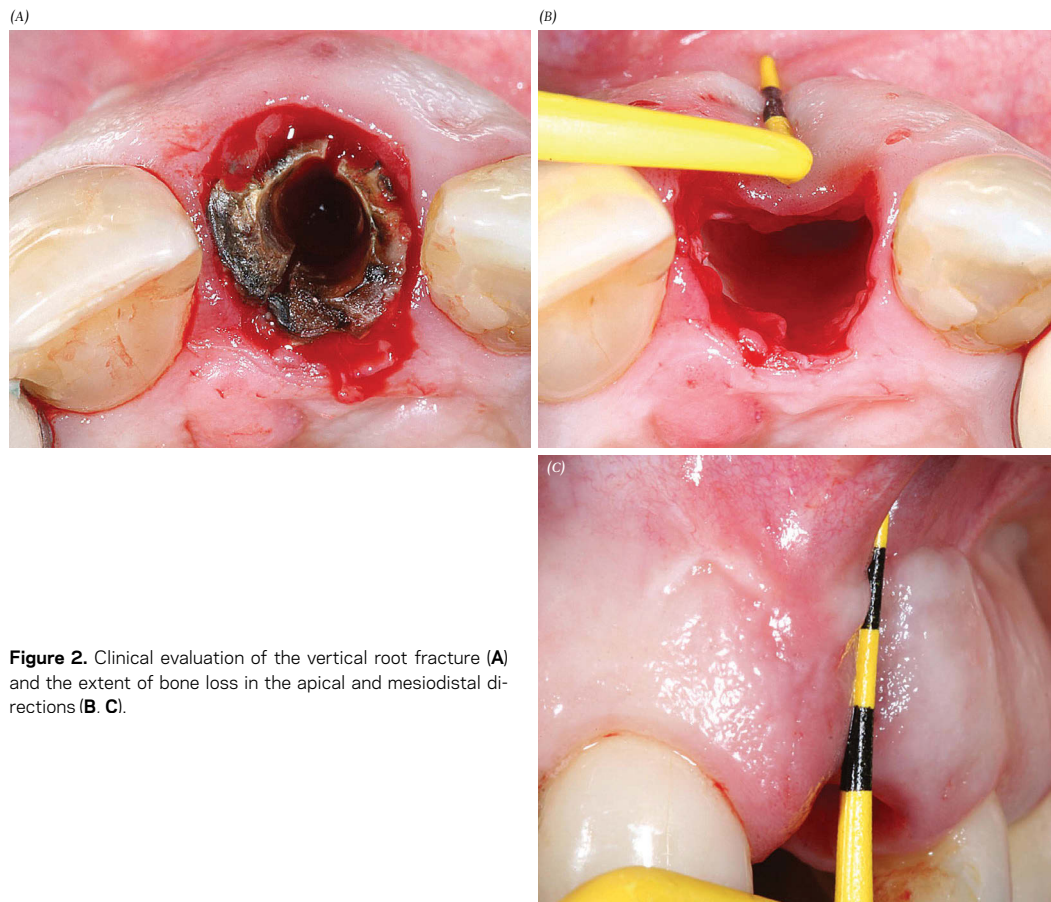
**Figure 1.** Initial clinical assessment of the compromised tooth #9 with fistula (A, B). The absence of the buccal bone wall is visible on the CBCT image (C).

manipu-  
t from  
out us-  
of the  
e corti-  
ed ap-  
atform  
to the  
chieve

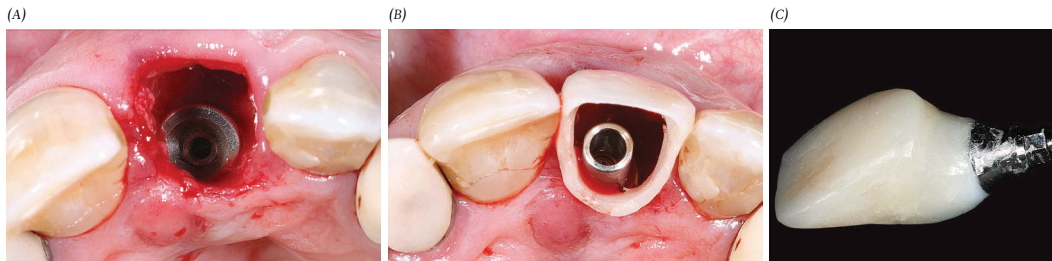
periodontal connective tissue. The socket walls were probed in the apical-coronal and mesial-distal directions to assess the degree of bone damage and to verify the anatomical shape of the defect (Fig 2B, C). An implant (13 mm in length and 4.8 mm in diameter) was installed with a palatal approach and anchored into the bone beyond the root apex, resulting in a stability of 50 Ncm (Fig 3A). A provisional crown was constructed, establishing an ideal emergence profile to allow accommodation of the soft tissue (Fig 3B, C).<sup>6</sup>

After anesthesia at the donor area was achieved, a crestal incision was made in the maxillary tuberosity. An appropriate

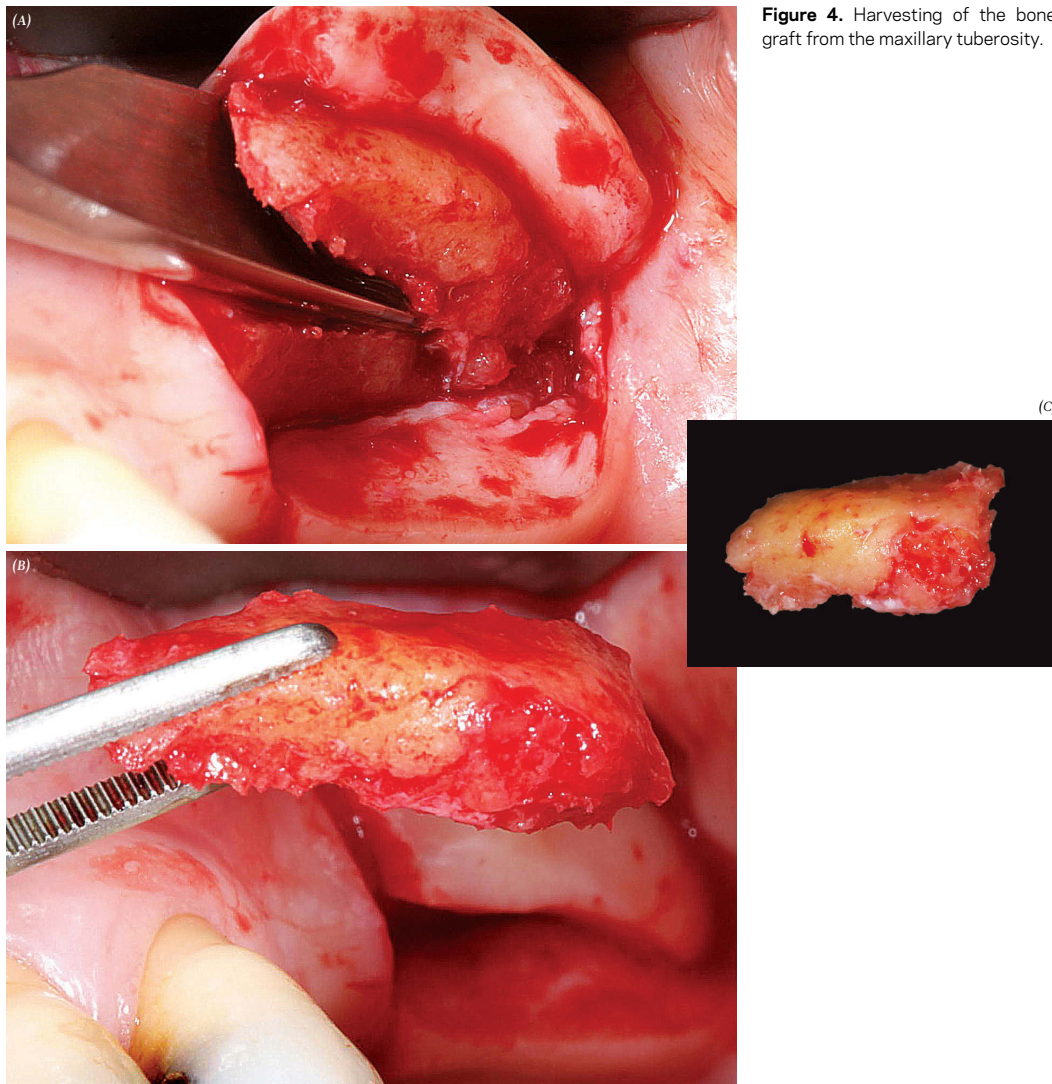
gouge-shaped chisel, 2 mm wider than the width of the bone defect (Fig 4A and B), was selected to harvest the graft according to the shape of the region to be restored (Fig 4C). Manipulation of the cortico-cancellous graft from the maxillary tuberosity was carried out using a rongeur to reproduce the shape of the peri-implant bone defect (Fig 5A). The cortico-cancellous bone graft was positioned approximately 1 mm from the implant platform, coronally, juxtaposed to the edges of the bone defect (Fig 5B), achieving primary stabilization of the graft, with the cortex turned toward the soft tissues. Subsequently, particulate



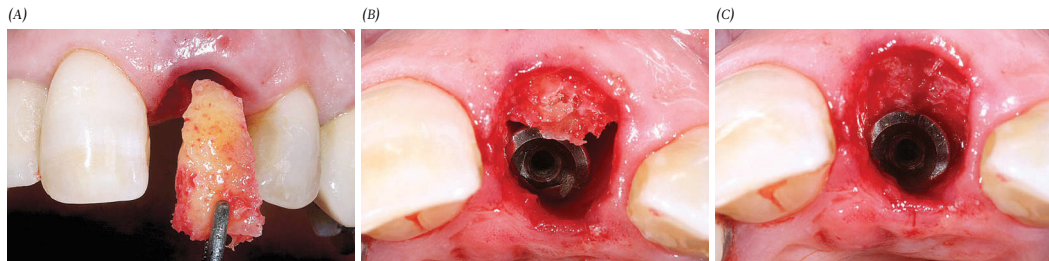
**Figure 2.** Clinical evaluation of the vertical root fracture (A) and the extent of bone loss in the apical and mesiodistal directions (B, C).



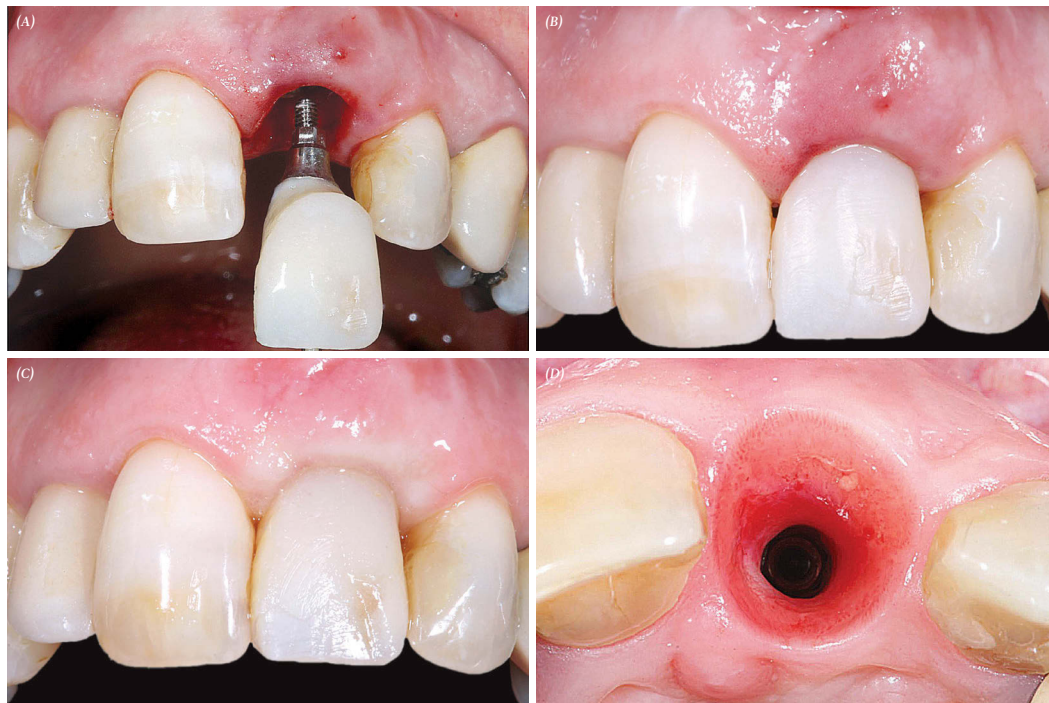**Figure 3.** Implant placement (A) and construction of a provisional crown before the grafting procedure (B, C).



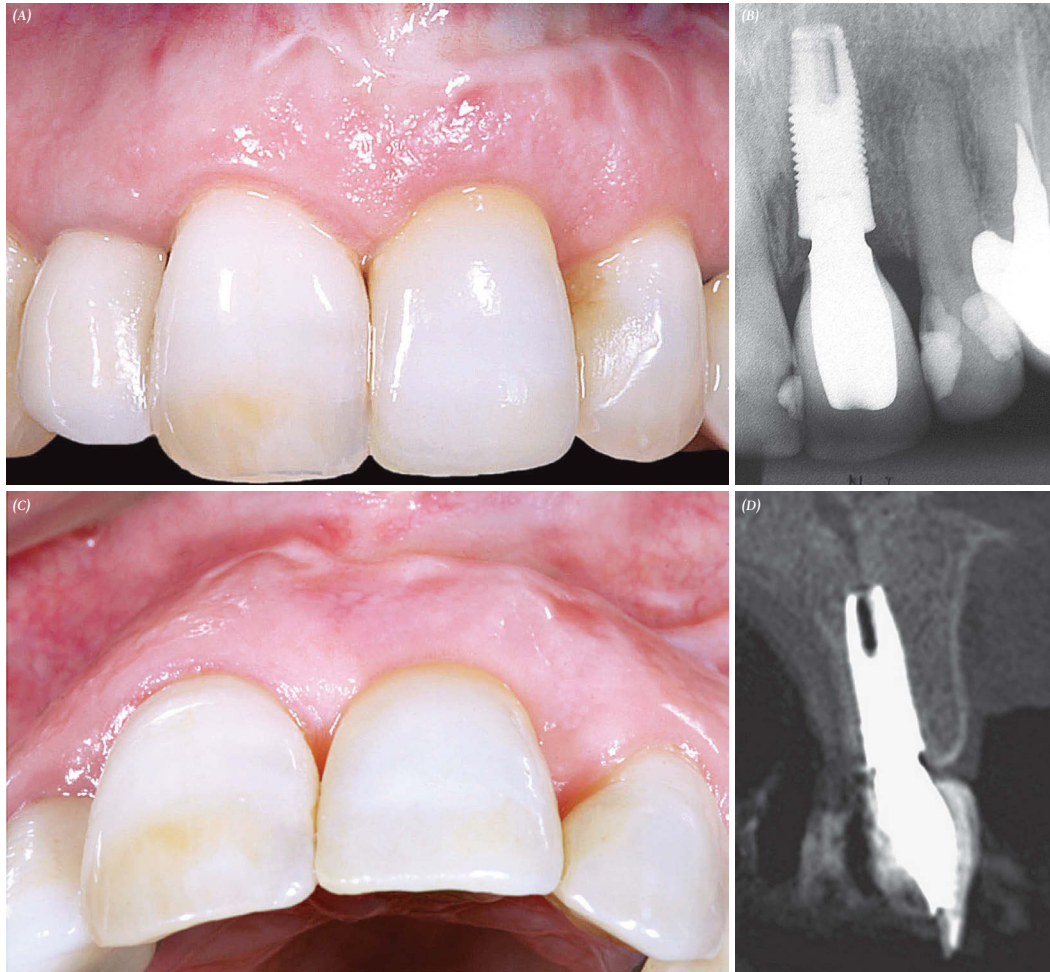**Figure 4.** Harvesting of the bone graft from the maxillary tuberosity.



**Figure 5.** Insertion of the cortico-cancellous graft, with the cortex on the buccal side (A) to the level of 1 mm from the implant platform, coronally (B). Final stabilization of the bone graft by filling with particulate medullary bone between the buccal surface of the implant and the internal portion of the bone graft (C).



**Figure 6.** Installation of the provisional crown (A, B). The results 4 months following the procedure, and after adding composite resin at the cervical portion of the provisional crown to balance the gingival margin, achieving good quality and volume of soft tissue (C, D).



**Figure 7.** Clinical assessment 3 years after the operation, showing stabilization of the soft tissues (A, C). Radiographic aspect showing the stability of the mesial and distal bone (B). Tomographic slice showing restoration of the buccal bone wall, that remains stable after total remodeling 1 mm from the implant platform, coronally (D).

bone marrow was inserted and packed between the medullary portion of the cortico-cancellous graft and the surface of the implant to ensure secondary stabilization of the graft (Fig 5C). Finally, the provisional crown was installed to seal the gingival margin (Fig 6A and B) and to provide final stabilization of the bone graft.

The patient was monitored clinically every week for the first month and every month for the next 4 months thereafter. After this period, composite resin was added at the cervical portion of the provisional crown (Fig 6C). Once bone and gingival architecture were reestablished (Fig 6D), a careful impression was obtained to capture the emergence profile. A zirconia abutment was installed using a torque of 35 Ncm. A lithium disilicate dental crown was constructed. After testing the porcelain and performing esthetic and functional adjustments, the crown was fixed with adhesive cement. Three years later, the clinical, radiographic and CBCT images show stability of hard and soft tissues (Fig 7).

## DISCUSSION

The reported prevalence of VRFs in the literature ranges from 10.9% to 12.9%.<sup>7</sup> Posts in the root canal are associated with 61.7% of root fractures.<sup>8</sup> The prognosis of a tooth with extensive fracture is poor, and in most situations, extraction is the only possible treatment option. VRF is usually associated with acute infection and damage of the socket, followed by bacterial biofilm development in the fracture space. In a clinical retrospective study of 75 patients, only 32% of extraction sites had intact bone walls, and 68% presented damage to at least one wall.<sup>9</sup> The buccal bone

wall is the most affected site because it is thinner and not as well vascularized.

The goal of the IDR technique is to promote a barrier with a cortico-cancellous graft, between the soft tissue and the particulate bone graft stabilized around the implant. The graft, which is harvested from the tuberosity, is modeled in the shape of the bone wall defect. IDR is an alternative to block grafting and guided bone regeneration procedures. It yields satisfactory functional and esthetic results, besides reducing total treatment time. This method enables recovery of the alveolar bone defect during the same surgical procedure of implant installation and immediate provisionalization. Although some studies<sup>10,11</sup> have voiced concerns regarding the adoption of immediate implant therapy in the presence of fractured or infected teeth because of possible biological complications, a systematic review found no differences in outcome with regard to the presence of infection.<sup>4</sup> To reduce the risks, the IDR uses a strict surgical protocol with careful curettage of the socket to remove the granulation tissue, and antibiotic therapy should start before implant placement.

The IDR technique is based on important biological principles. The trabecular nature of grafts harvested from the maxillary tuberosity suggests that such grafts have a high revascularization capacity and release growth factors to the receptor site.<sup>12</sup> However, these grafts must be transplanted rapidly to prevent the loss of their fundamental properties.<sup>13,14</sup>

Another important factor for the success of the IDR technique is the use of flapless surgery, which reduces the possibility of recession of the surrounding hard and soft tissues, commonly seen in more

invasive procedures. Flapless surgery has reportedly good esthetic results and low postoperative morbidity. However, it is a “blind” procedure, and the risk of complications increases when bone defects are larger.<sup>15</sup> For this reason, the clinical assessment and CBCT diagnostic imaging are fundamental to confirm the dimensions of bone defect to be reconstructed and the presence of adequate bone height at the anticipated site of implant placement.

Immediate implant placement after extraction can be successfully performed to reduce treatment time without reducing predictability with respect to standard protocols. Biological changes that occur when an implant is used at an early stage are of great importance in bone repair. Early low-intensity stimulation increases the local blood flow and contact osteogenesis, thereby accelerating the process of bone graft repair.<sup>16</sup>

In damaged sockets, soft tissue stability is necessary for reconstruction of the peri-implant tissue components. Absence of a buccal bone wall to support the facial mucosa may lead to recession and incomplete papillae.<sup>2</sup> Thus, implant treatment goals must be expanded to include the reconstruction of these lost anatomical structures. A goal of the IDR technique is to re-establish lost bone wall, thereby correcting socket defects and supporting soft tissue esthetics with bone graft from the maxillary tuberosity, at the same time of implant placement and provisional crown fabrication. However, the maxillary tuberosity also presents some disadvantages due to the limited quantity of bone available, low bone density, and difficulty of surgical access.<sup>12</sup>

Immediately after implant insertion and dentoalveolar restoration, coagulum

and a fibrin network form and fill the remaining spaces between the implant and the grafted bone. If the gap is wide, there is a risk of ongoing resorption of the buccal bone wall and exposure of the implant surface. According to Buser and Martin,<sup>17</sup> if the width between the implant and the labial bone wall exceeds 2 mm, then a considerable amount of horizontal bone resorption can be expected, and simultaneous bone graft is necessary to promote bone regeneration. Based on this principle, also in the use of IDR, all alveolar spaces should be filled with particulate bone from the tuberosity.

## CONCLUSION

Cortico-cancellous bone graft, manipulated according to the bone defect format, associated with particulate bone marrow from the maxillary tuberosity promotes restoration of freshly damaged sockets, thereby enabling immediate provisionalization of an implant, avoiding the need for several surgical procedures, and preventing the esthetic risks related to these procedures. The IDR technique, therefore, represents a viable and reproducible treatment alternative, since the protocol is followed accurately.

REFERENCES:

1. Belser U, Buser D, Higginbottom F. Consensus statements and recommended clinical procedures regarding esthetics in implant dentistry. *Int J Oral Maxillofac Implants.* 2004;19 Suppl:73-4.
2. Cosyn J, Sabzevar MM, De Bruyn H. Predictors of inter-proximal and midfacial recession following single implant treatment in the anterior maxilla: a multivariate analysis. *J Clin Periodontol.* 2012;39(9):895-903.
3. Da Rosa JC, Rosa AC, da Rosa DM, Zardo CM. Immediate dentoalveolar restoration of compromised sockets: a novel technique. *Eur J Esthet Dent.* 2013;8(3):432-43.
4. Palmer R. Evidence for survival of implants placed into infected sites is limited. *J Evid Based Dent Pract.* 2012;12(3 Suppl):187-8.
5. Huynh-Ba G, Pjetursson BE, Sanz M, Cecchinato D, Ferrus J, Lindhe J, et al. Analysis of the socket bone wall dimensions in the upper maxilla in relation to immediate implant placement. *Clin Oral Implants Res.* 2010;21(1):37-42.
6. Su H, Gonzalez-Martin O, Weisgold A, Lee E. Considerations of implant abutment and crown contour: critical contour and subcritical contour. *Int J Periodontics Restorative Dent.* 2010;30(4):335-43.
7. Mora MA, Mol A, Tyndall DA, Rivera EM. In vitro assessment of local computed tomography for the detection of longitudinal tooth fractures. *Oral Surg Oral Med Oral Pathol Oral Radiol Endod.* 2007;103(6):825-9.
8. Hassan B, Metska ME, Ozok AR, van der Stelt P, Wesselink PR. Comparison of five cone beam computed tomography systems for the detection of vertical root fractures. *J Endod.* 2010;36(1):126-9.
9. Zitzmann NU, Schärer P, Marinello CP. Factors influencing the success of GBR. Smoking, timing of implant placement, implant location, bone quality and provisional restoration. *J Clin Periodontol.* 1999;26(10):673-82.
10. Takeuchi N, Yamamoto T, Tomofuji T, Murakami C. A retrospective study on the prognosis of teeth with root fracture in patients during the maintenance phase of periodontal therapy. *Dent Traumatol.* 2009;25(3):332-7.
11. Nelson S, Thomas G. Bacterial persistence in dentoalveolar bone following extraction: a microbiological study and implications for dental implant treatment. *Clin Implant Dent Relat Res.* 2010;12(4):306-14.
12. Cicconetti A, Sacchetti B, Bartoli A, Michienzi S, Corsi A, Funari A, et al. Human maxillary tuberosity and jaw periosteum as sources of osteoprogenitor cells for tissue engineering. *Oral Surg Oral Med Oral Pathol Oral Radiol Endod.* 2007;104(5):618.e1-12.
13. Prolo DJ, Rodrigo JJ. Contemporary bone graft physiology and surgery. *Clin Orthop Relat Res.* 1985;200:322-42.
14. Goldberg VM, Stevenson S. Natural history of autografts and allografts. *Clin Orthop Relat Res.* 1987;(225):7-16.
15. Doan N, Du Z, Crawford R, Reher P, Xiao Y. Is flapless implant surgery a viable option in posterior maxilla? A review. *Int J Oral Maxillofac Surg.* 2012;41(9):1064-71.
16. Burchardt H. Biology of bone transplantation. *Orthop Clin North Am.* 1987;18(2):187-96.
17. Buser D, Martin W, Belser UC. Optimizing esthetics for implant restorations in the anterior maxilla: anatomic and surgical considerations. *Int J Oral Maxillofac Implants.* 2004;19 Suppl:43-61.